

Zaporozhye State Medical University  
Department of Obstetrics and Gynecology

# **Postpartum Obstetrical Hemorrhages**

(a text-book for English-speaking students of  
higher medical educational establishments)

Prepared by  
Gaidai N.V.

Zaporozhye

2015

Author:

Natalya V. Gaidai – associate professor of the department of Obstetrics and Gynecology Zaporozhye State Medical University.

Reviewers:

Natalya S. Lutsenko - a doctor medical sciences, professor, the head of department of Obstetrics and Gynecology of Zaporozhye Medical Academy of postgraduate education Ministry of Health of Ukraine.

Vadim Yu.Potebnya - associate professor of the department of Obstetrics and Gynecology Zaporozhye Medical Academy of postgraduate education Ministry of Health of Ukraine.

Grammar correction:

E.L. Gordienko. Department of Foreign Languages. Zaporozhye State Medical University.

Recommended by the central methodical \_\_\_\_\_ of Zaporozhye State Medical  
University (Minutes № 6 \_\_\_\_\_ from 20/05/2015 y.)

## **Preface.**

The text-book prepared according to the program of studying of obstetrics at medical faculty on a speciality «medical profession». The incidence of obstetrical hemorrhage is 5-10% of all labour cases, however, it itself represents the most often cause of maternal morbidity, invalidity and death (20-25%). The one of the main factors which influences the obstetrical hemorrhage, incidence is the increasing of abdominal delivery cases. The profuse obstetrical hemorrhage during some minutes can become fatal because of belated elimination of blood and its components deficiency. According to statistics from the World Health Organization (WHO 2010) more than 20% of maternal deaths associated with postpartum hemorrhage. In Europe, maternal mortality from hemorrhages is -1.7%; in Russia- 22%; in Ukraine- 25%; in Nigeria-27%.If blood loss during pregnancy and delivery is above these indices, the hemorrhage is pathological.

The text-book is recommended for students of IV, V, VI courses of medical faculty of higher educational establishments.

## Contents.

1.Preface.....	3
2. Physiological puerperal period.....	5
3. Hemorrhage in early postpartum period:.....	11
3.1 Placental anomalies and retained placenta	
3.2 Hypotonia and atonia of uterus.	
3.3 Traumas of maternal passages	
4.. Patient maternal traumatism.....	22
5. Intensive Therapy of Massive Obstetrics Hemorrhages.....	58
6. Hemorrhagic shock and coagulation disturbances	
DIC-syndrome. ....	66
7. Literature.....	79
8. Supplement .....	80

## PHYSIOLOGICAL PUERPERAL PERIOD

Despite the fact that the puerperal period is a physiological process it requires from the doctor the knowledge of all its stages and peculiarities, namely: the processes of involution in the organs and systems of the woman after delivery, lactation, which allows timely detection of initial signs of diseases and complications, which may arise in a parturient woman.

*The puerperal period* (puerperium) begins right after delivery and lasts during 6 weeks. During this time the organs of the reproductive system of the woman returns to the state, which existed before the pregnancy.

The puerperal period is divided into early and late.

*The early puerperal period* begins from the moment of placenta expulsion and lasts 2 h. In this period the parturient woman is in the maternity department under doctor's supervision, which is connected with the risk of complications, hemorrhage in the first place. The period is very important and should be viewed as a term of quick adaptation of the woman's functional systems after big load during pregnancy and, especially, delivery.

*The late puerperal period* lasts from the moment of the parturient woman's transfer to the postnatal department (in 2 h after delivery is completed) during 8 weeks. During this period there takes place the involution of all organs and systems, which have changed because of pregnancy and labor. It should be emphasized that the mammary glands are an exception, whose function is activated exactly in the puerperal period. It should also be noted that the rate of involutional processes is maximal during the first 8—12 days and are the most expressive in the genitals, the uterus in the first place.

## CHANGES IN THE WOMAN'S ORGANISM IN THE PUERPERAL PERIOD

**The uterus.** Right after the placenta is born the uterus begins quick contractions and becomes round. Open vessels of the placental part shrink. Right after the placenta is born the uterine body contracts and its fundus is in the middle of the distance from the pubis to the navel, then elevates slightly. The posterior and anterior uterine walls are 4—5 cm thick and adjoin one another; the uterine cavity is lined with the decidual membrane. During the next 2 days the uterine fundus is slightly below the navel; in 2 weeks after delivery the uterus descends below the symphysis. The uterus usually returns to preliminary dimensions in 6 weeks. Uterine involution takes place due to the involution of some muscles by means of hyaline and fatty degeneration.

During 2—3 days after delivery the decidual membrane remains in the uterus and divides into two layers. The surface layer necrotizes and is released with lochia (postnatal discharge). The basal layer, adjacent to the epithelium, which contains endometrial glands, remains intact and becomes the basis for the regeneration of new endometrium.

Endometrium regeneration takes place during 3 weeks, excluding the placental area. Complete epithelium regeneration in the place of placentation lasts 6 weeks. Violation of regeneration in the placental area may cause postnatal hemorrhages and infections.

**The uterine neck.** In 10—12 h after delivery the cervical canal of uterus is funnel-shaped, the internal mouth admits 2—3 fingers, and on the 3<sup>rd</sup> day — 1 finger. On the 8<sup>th</sup>—10<sup>th</sup> day after delivery the uterine neck is formed, the internal mouth is closed.

**The vagina.** In the course of 3 weeks after delivery the vaginal walls remain with edemata, which completely disappear till the end of the puerperal period. Minor injuries of the vaginal mucous tunic regenerate in 5—7 days. The pudendal fissure closes; the muscle tone of the pelvic floor muscles is gradually restored.

**The ovaries.** In the puerperal period follicles begin to mature. An anovulatory cycle is characteristic, against the background of which there takes place the first

menstruation after delivery. Further on ovulatory cycles restore. Due to the discharge of a big quantity of prolactin in women at breast feeding menstruations are absent during a couple of months or during the whole period of breast feeding.

***The abdominal wall and pelvic floor.*** Because of the rupture of elastic fibers of skin and long-term stretch by the pregnant uterus the anterior abdominal wall remains soft and flabby for some time and returns to the normal structure in a couple of weeks. Usually the abdominal wall returns to the preliminary condition, but at muscles atony may remain flabby and weak. Sometimes diastasis recti abdominis is observed. The pelvic floor muscles also gradually restore their tone, but the presence of an injure during delivery may cause muscles slackening and promote the formation of genital hernias (prolapses).

***The mammary glands.*** The function of the mammary glands after delivery reaches the highest development. During pregnancy estrogens and progesterone stimulate the growth of the ducts and alveolar system of the mammary glands. Under the influence of prolactin there takes place intensified blood supply to the mammary glands, their intumescence, which is the most evident on the 3<sup>rd</sup> day after delivery. Lactation happens as a result of complex reflex and hormonal processes. Milk formation is regulated by the nervous system and adenohipophysis hormone — prolactin. Besides, the optimal level of insulin, thyreoid and adrenal hormones plays a secondary role in lactation establishment. Sucking stimulates periodic secretion of prolactin and, by reflex, of oxytocin; the latter stimulates milk let-down fro the alveoles of mammary glands ducts. It should be noted that this process also intensifies contractions of the postnatal uterus. In the period till the 3<sup>rd</sup> day after delivery the mammary glands generate colostrum. Colostrum has a high concentration of proteins, mainly globulins, and minerals, and less — of sugar and fat. Colostrum proteins by their aminoacid composition are in the transient state between the protein fractions of human milk and blood serum, which obviously facilitates the newborn's organism in the period of transition from placental feeding to breast feeding. Colostrum contains a high level of immunoglobulins A, G, M, D, and also T- and B-lymphocytes. This is very important during the first days of the newborn's life, when

functions of its organs and systems are still immature and immunity is at the stage of formation. Colostrum converts into mature milk during 5 days. The main components of milk are proteins (albumins, globulins, casein), lactose, water, and fat.

***The respiratory system.*** Since the diaphragm descends after delivery, lung capacity increases, which causes the decrease of respiratory movements number to 14—16 per min.

***The cardiovascular and hematopoietic systems.*** After delivery there arise changes in hemodynamics connected with the elimination of the uteroplacental circulation and discharge of some fluid from the mother's organism. The heart takes its usual position in connection with phrenoptosis. Right after delivery there is noted pulse lability with inclination to bradycardia, ABP may be lowered in the first days after delivery, and further reaches normal indices. In the end of the first week after delivery the volume of circulating blood reduces to normal. Blood indices often do not differ from normal, still, in the early puerperal period considerable granulocytes-dominated leukocytosis is observed — up to  $30 \cdot 10^9/L$ . The fibrinogen level in the plasma

is increased, which should necessarily be taken into account at the prophylaxis of the development of lower extremities phlebitis.

***The system of urinary excretion.*** The renal function is not violated in healthy parturient women; diuresis is normal, may be slightly increased during the first days after delivery. The function of the urinary bladder is rather often disturbed, which is connected with the overexcitation of the sympathetic innervation of the sphincter and relaxation of the urinary bladder caused by its compression between the fetal head and pelvic wall during delivery.

***The alimentary organs and metabolism.*** The digestive system functions normally after delivery. Sometimes bowels atony is observed with constipations. Metabolism is usually increased during the first weeks after delivery, and later - till the 3<sup>rd</sup>—4<sup>th</sup> week — normalizes.



*The nervous system.* After delivery there usually takes place neurosis of different tension, which normalizes during 1—2 days. In this period the parturient woman needs psychological support of the family, friends, and medical staff.

## **PUERPERAL PERIOD MANAGEMENT**

The physiological puerperal period is characterized by satisfactory condition of the parturient woman, normal body temperature and pulse rate, regular involution of uterus, presence of the normal quantity and quality of lochia, sufficient lactation.

During the first two hours after delivery the woman is in an individual delivery room under the supervision of a midwife and an obstetrician-gynecologist; the husband or a relative may also be present. This time interval is very important, since during it there take place physiological processes of the maternal organism adaptation to the new conditions of existence, therefore it is necessary to create the most comfortable conditions promoting effective adaptation after delivery. This is undoubtedly promoted by the child's staying together with the mother in the contact "skin-to-skin" and early breast-feeding, which in its turn provides the formation of breast feeding, thermal protection of the child, prevention of infections, and development of emotional connection between the child and the mother. The optimal for the mother and child is considered the environment temperature of 25—28°. Later on, if there are no contraindications, the newborn child must stay with the mother twenty-four-hour in one room. Such rooming-in provides the child's feeding on demand, hypothermia and hospital infection prophylaxis.

When the parturient woman is in the labor ward the obstetrician-gynecologist must watch her pulse, arterial pressure, control the condition of the uterus: detect its consistency, dimensions, the height of uterine fundus standing in relation to the symphysis and navel, observe blood discharge from the maternal passages. It should be noted that evaluation of blood loss in the early puerperal period is obligatory. Blood loss measurement is conducted with the help of any graduated glass. Average

blood loss at the placental stage of delivery and in the early puerperal period makes 250—300 ml or 0.5 % of the woman's body weight, but not more than 500 ml.

In the early puerperal period one examines the external genitals, symphysis pubis, and perineum. Uterine neck and vagina examination is conducted with the help of specula by indications. If episiotomy was conducted or an injury of the parturient canal took place, the restoration of parturient canal integrity with the application of local anesthesia is obligatory.

In 2 h after delivery the parturient woman and the child are transferred to the postnatal department, where follow-up is carried out. Body temperature must be taken twice a day, in the morning and in the evening; one must also examine the skin and mucous tunics, detect the character and rate of pulse, take arterial pressure regularly. Special attention is paid to the mammary glands — one detects their form, condition of the nipples, presence of fissures, and possible swelling of the glands. In case of lactostasis, expression of breast milk is conducted. The woman is orientated at thorough daily examination of the mammary glands, detecting hardenings; a talk on mastitis prevention is to be given. The newborn is fed according to its needs.

One must daily palpate the parturient woman's abdomen, detect the height of uterine fundus standing, its consistency. The height of uterine fundus standing is measured in cm relative to the symphysis pubis. During the first day after delivery the uterine fundus is located higher than the symphysis pubis by 13—16 cm, during the second day — 10—12 cm, during the third day — 7—9 cm.

The velocity of reparative processes in the uterine cavity is also detected by lochia. Microscopically lochia consist of erythrocytes, fragments of decidual membrane, epithelial cells, bacteria; have a neutral or alkaline reaction. During the first days the presence of blood colors them red (*lochia rubra*), on the 3<sup>rd</sup>—4<sup>th</sup> day after delivery they become lighter (*lochia serosa*), and on the 8<sup>th</sup>—10<sup>th</sup> day, due to the prevailing presence of leukocytes, lochia become yellowish-white (*lochia alba*).

If there are no deviations from the physiological course of the puerperal period the parturient woman with the newborn is discharged home on the 3<sup>rd</sup> day under the

supervision of an obstetrician-gynecologist of the maternity welfare clinic and a district pediatrician with recommendations including:

- following the rules of personal hygiene;
- following the day regimen, having rest not less than 8 h a day;
- performing special physical exercises of postnatal gymnastics;
- following the diet and eating pattern with an average caloric content of 2,600—2,800 kcal/day, with sufficient quantity of proteins, vitamins, and minerals;
- the possibility of sexual life recommencement is decided individually depending on the woman's condition.

In 3—4 weeks after delivery the woman must undergo a standard examination at the maternity welfare clinic, where her level of health is thoroughly assessed, the question of further course of puerperal period is discussed, and recommendations are provided concerning family planning.

## **OBSTETRIC HEMORRHAGES**

### **Classification of the Obstetrics Bleeding:**

1. Haemorrhage in first half of pregnancy (spontaneous abortion, extrauterine pregnancy, hydatid mole, polyps, erosions, a cancer of cervix uterus, cervical pregnancy).
2. Haemorrhage in second half of pregnancy (placenta praevia, premature separation normally implanted placenta, polyps, erosions).
3. Haemorrhage in labor (placenta praevia, premature separation normally implanted placenta, a trauma of cervix uterus, a vagina, a bleeding from varicose amplate veins of generative organs, infringement contractive activity of a uterus in III stage of labor, infringement of system coagulate bloods).
4. Bleedings in early puerperal period (retention of parts of the placenta in the uterus, hypotonia and atonia of the uterus, a trauma of the soft tissues of the birth canal, blood coagulation disorders).
5. Bleedings in late puerperal period (placental polyp, endometritis, choriocarcinoma).

6. Haemorrhage in first half of pregnancy (spontaneous abortion, extrauterine pregnancy, hydatid mole, polyps, erosions, a cancer of cervix uterus, cervical pregnancy).

7. Haemorrhage in second half of pregnancy (placenta praevia, premature separation normally implanted placenta, polyps, erosions).

8. Haemorrhage in labor (placenta praevia, premature separation normally implanted placenta, a trauma of cervix uterus, a vagina, a bleeding from varicose amplate veins of generative organs, infringement contractive activity of a uterus in III stage of labor, infringement of system coagulate bloods).

9. Bleedings in early puerperal period (retention of parts of the placenta in the uterus, hypotonia and atonia of the uterus, a trauma of the soft tissues of the birth canal, blood coagulation disorders).

10. Bleedings in late puerperal period (placental polyp, endometritis, choriocarcinoma).

## **HEMORRHAGES IN THE COURSE OF DELIVERY AND IN THE POSTPARTUM PERIOD**

The reasons for hemorrhages at the 3rd stage and in the puerperal period may be various. The main of them: impaired motor function of the uterus, violation of placenta detachment and removal, impaired blood clotting, injuries of the maternal passages.

### **Placenta Attachment Anomalies**

**Reasons for fused placenta:** inflammatory processes in the anamnesis, postoperative scars on the uterus, abortions, metrofibroma, uterus malformations, increased proteolytic activity of the chorion.

#### **Degrees of fused placenta:**

- placenta adhaerens — the chorion villi penetrate into the basal layer of the decidual membrane (Fig. 1);

- placenta accreta — the chorion villi penetrate through the whole basal layer of the decidual membrane to the muscular layer of the uterus (Fig. 2);
- placenta insreta — the chorion villi penetrate into the depth of the uterine muscular layer;
- placenta percreta — the villi penetrate the muscular and serous uterine layers.

Normally the myometrium contracts in the puerperal period and the placenta begins detaching from the placental bed, which leads to the violation of intervillous lacuna integrity. Bleeding may be moderate, or acquires profuse character from the very beginning.

The degree of bleeding depends on the area of the placental bed, with which the placenta loses connection, contractility of the myometrium and coagulation value of

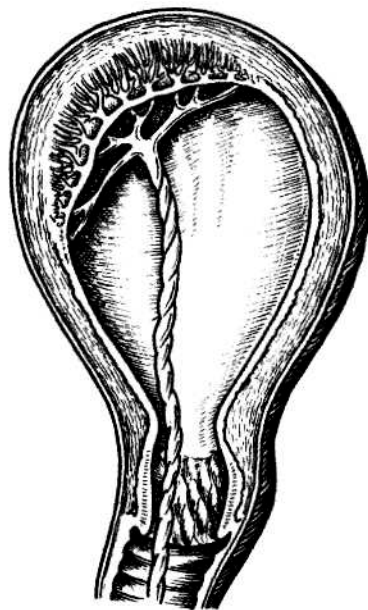


Fig.1. False fused placenta

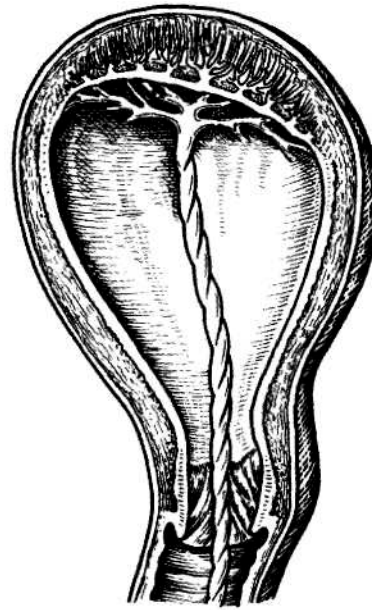


Fig. 2. True fused placenta

blood. The placenta detaches gradually, but if it is attached intimately or is fused, these processes are violated, which is accompanied by bleeding and the absence of signs or incomplete placenta detachment. If the placenta is fused, there is no bleeding and placenta detachment signs along it.

At *placenta percreta* (placenta invasion of all uterus layers) the main symptom is internal bleeding.

**Obstetric management.** The duration of the 3rd stage of labor makes 10 to 30 min. 2—3 signs are enough to establish the fact of placenta detachment, and if it is not born, one should apply external maneuvers of placenta removal.

If the volume of blood loss is up to 0.5 % of body weight and if bleeding continues, worsening of the general condition of the parturient woman in the absence of external bleeding — urgent manual detachment and removal of placenta under i.v. anesthesia (Fig. 3).

If during 30—40 min there are no signs of placenta detachment and external or internal bleeding, true fused placenta is diagnosed and placenta detachment is attempted only in the operating theatre.

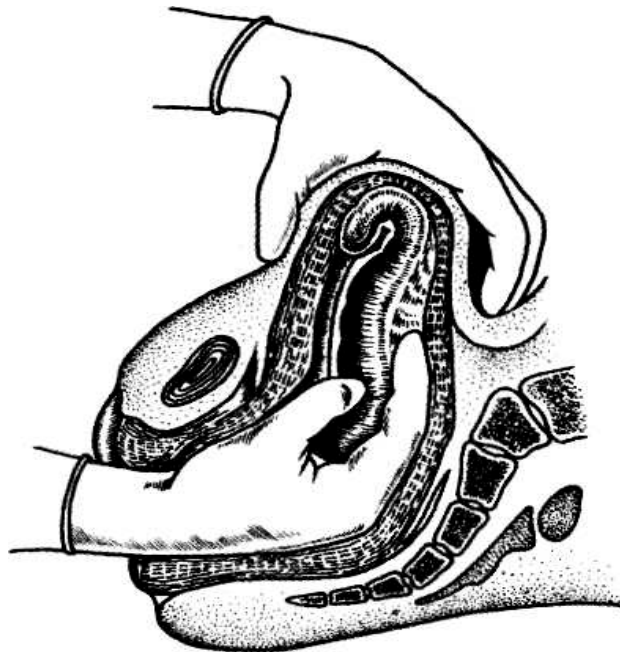


Fig. 3. **Manual detachment of placenta**

At true fused placenta or placenta invasion — laparotomy, extirpation of the uterus without the appendages.

An established defect of the placenta is an indication to manual revision of the uterine walls under i.v. anesthesia irrespective of bleeding presence.

## **Hemorrhages in the Early and Late Puerperal Period**

**Hypotonic hemorrhages.** Uterine hemorrhages during the first hours of the puerperal period are most often connected with the impaired contractile function of the uterus (hypo- and atonic conditions). Atony is such a state of the uterus, at which the myometrium completely loses the ability to contract, but usually reacts with contraction to mechanical, physical, and pharmacological irritators.

### **Reasons for hypotonic hemorrhages:**

1. General reasons: late gestosis, endocrinopathies, acute and chronic infections, etc.
2. Local reasons: a large fetus, hydramnion, uterine maldevelopment, chorionamnionitis.
3. Complicated delivery course.
4. Operative delivery.
5. Impaired functions of the neuromuscular apparatus of the uterus due to hemostasis defects associated with complications of pregnancy and delivery or hereditary/congenital diseases.
6. Iatrogenic reasons.

### **Clinical presentation.** Bleeding may be of two types:

- 1) right after the placenta is born the uterus loses the ability to contract, it is atonic, does not react to mechanical, temperature and medicamentous irritators, it is massive, in a couple of minutes > 1,000 ml, quickly leads to the shock state;
- 2) bleeding begins after uterus contraction, the uterus relaxes periodically, tones up under the action of contracting drugs, then becomes flaccid again. Blood is discharged in small portions — undulatingly: periods of bleeding increase are changed by almost complete arrest, blood loss increases gradually. This bleeding is hypotonic.

### **Obstetric management:**

- a) urinary bladder emptying;
- b) external massage of the uterus (20—30 sec in 1 min); external uterine massage, manual examination of the uterus (ROPME)

c) oxytocin introduction.

The initial dose:

— 10 IU i.m. or i.v. or i.v. infusion of 20 IU in 1,000 ml of physiologic saline, 60 drops a min.

The second dose:

— 10 IU i.m. or i.v. in 20 min if profuse bleeding continues or i.v. infusion of 10 IU in 1,000 ml of physiologic saline with the speed of 30-40 drops a min.

The maximum dose: introduction of uterotonic I line (oxytocin 20 IU / 400 ml 0.9% NaCl),— i.v. not more than 3 L of liquid containing oxytocin;

d) ergometrine -the first order preparation for the treatment of hypotension of the uterus, which does not react to oxytocin. The initial dose makes 0.2 mg i.m. or i.v. slowly, the second dose - 0.2 mg i.m. in 15 min if bleeding does not stop, but not more than 5 doses (1.0 mg).

- Carboprost (15-metil PGF<sub>2a</sub>) - the preparation for the treatment of atony of the uterus, which cannot be treated with oxytocin/ergometrine. For most women one dose is enough, the efficiency makes 86-96 %. The initial dose of 0.25 mg, deep i.m. injection into the myometrium; the second dose of 0.25 mg every 15 min, if bleeding does not stop, but not more than 8 doses (2.0 mg); introduction of uterotonic II line (misoprostol 800mkg / rectum- in 7 women in childbirth), III (pub 1.0 I / O - in 1 maternity)

- UCEM in the deployed using I / **traneksavmovoy** acid-100mg.

if the parturient women does not react to the measures being conducted, one should arrest bleeding temporarily by means of: 1) bimanual compression of the uterus (Fig. 3): the doctor puts on sterile gloves and introduces one hand into the vagina, makes a fist. The fist is to be located in the anterior fornix and to press on the anterior uterine wall. The other hand presses the posterior uterine wall through the anterior abdominal wall in the direction of the hand introduced into the



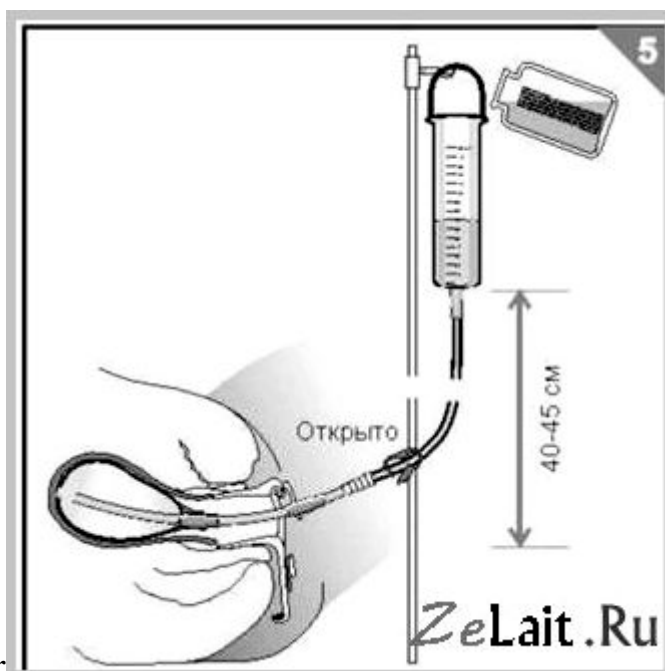
vagina. The doctor continues pressing until bleeding stops and the uterus begins contracting

### **BAKRI BALLOON**

The SOS Bakri tamponade balloon catheter (Cook Ob/Gyn) is marketed as 100% Silicon (no latex), purpose-designed two-way catheter, to provide temporary control or reduction of postpartum uterine bleeding when conservative

management is warranted (see Figure 3)4.

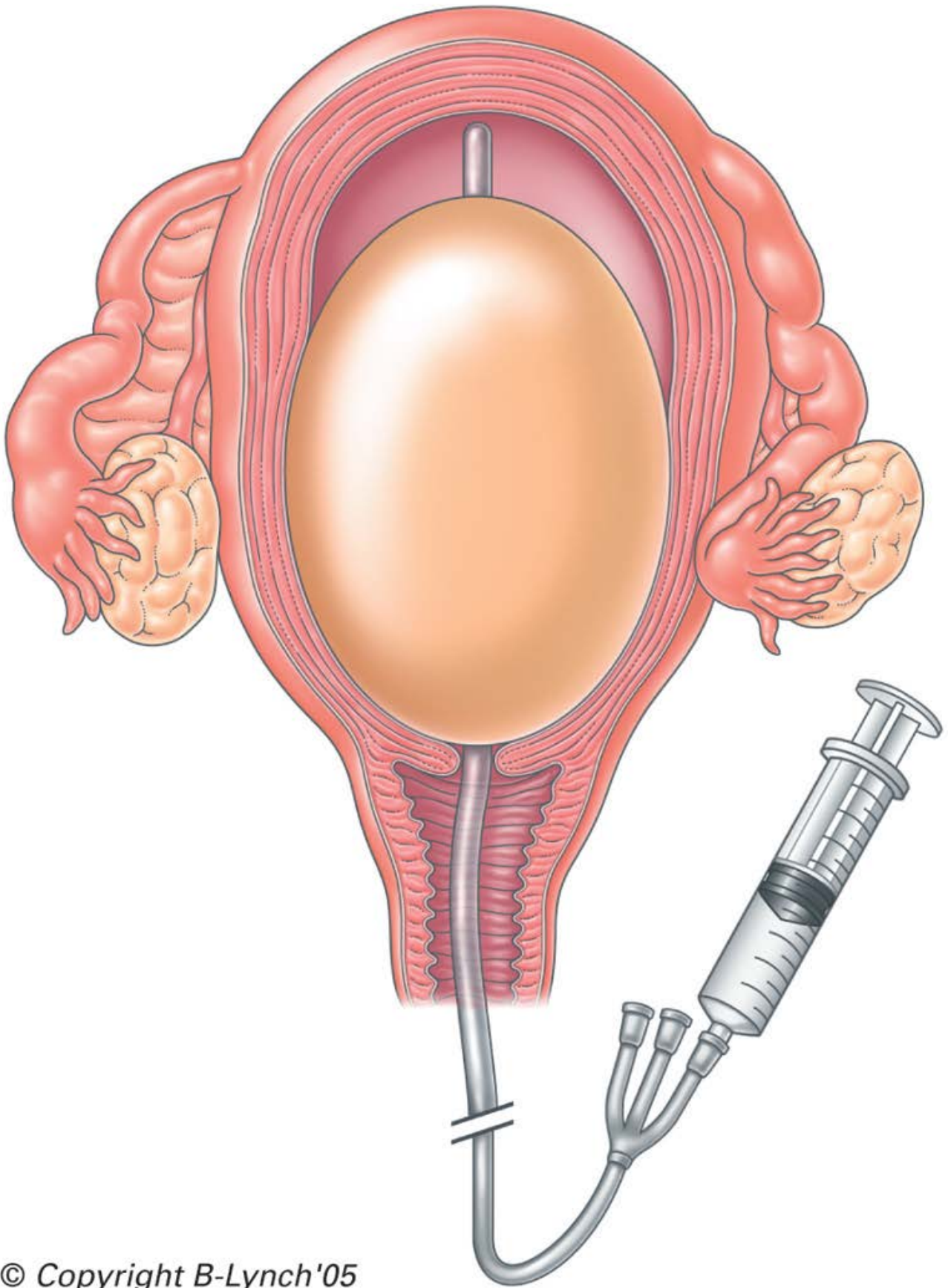
Again, the insertion technique is simple. Insert the balloon portion of the catheter in the uterus, making sure that the entire balloon is inserted past the cervical canal and internal os,



under

ultrasound guidance if possible. At Cesarean delivery, the tamponade balloon can be passed via the Cesarean incision into the uterine cavity with the inflation port passing into the vagina via the cervix. An assistant pulls the shaft of the balloon through the vaginal canal until the

deflated balloon base comes into contact with the internal cervical os. The uterine incision is closed in the usual fashion, taking care to avoid puncturing the balloon while suturing. A gauze pack soaked with iodine or antibiotics can then be inserted into the vaginal canal to ensure maintenance of correct placement of the balloon and maximize the tamponade effect. The balloon is then inflated with sterile fluid to the desired volume for tamponade effect. Gentle traction on the balloon shaft ensures proper contact between the balloon and the tissue surface and may enhance the tamponade effect. Success can be judged by the declining loss of blood seen through the drainage port and the fluid connecting bag. The main disadvantage of this method is that it may not be affordable in resource-poor countries because of the expense.

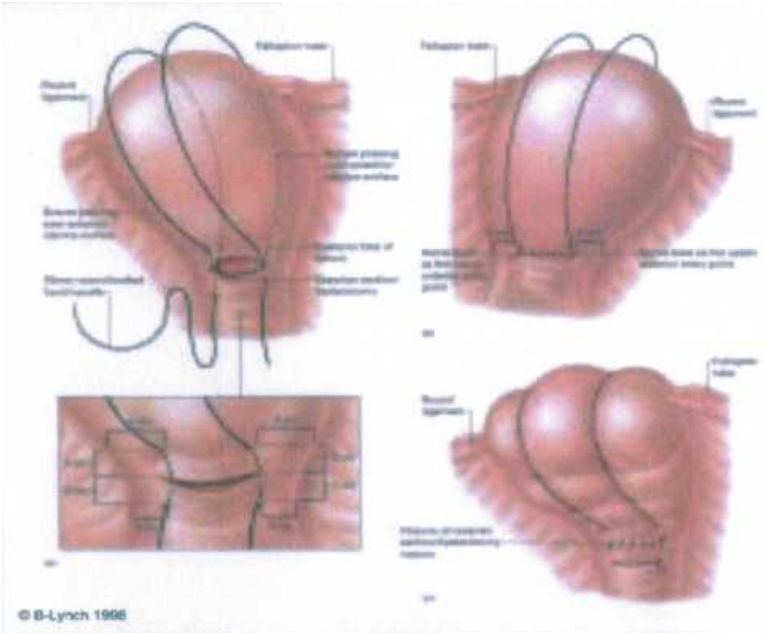


© Copyright B-Lynch'05  
POSTPARTUM HEMORRHAGE

e), or 2) internal massage of the uterus and then 3) abdominal aorta pressing;

f) if bleeding is not arrested conservatively, one should proceed to surgical hemostasis: compression sutures

g) on the uterus (e.g. Lynch's suture)



h) bilateral ligation of the uterine arteries; bilateral ligation of the internal iliac arteries; hysterectomy.

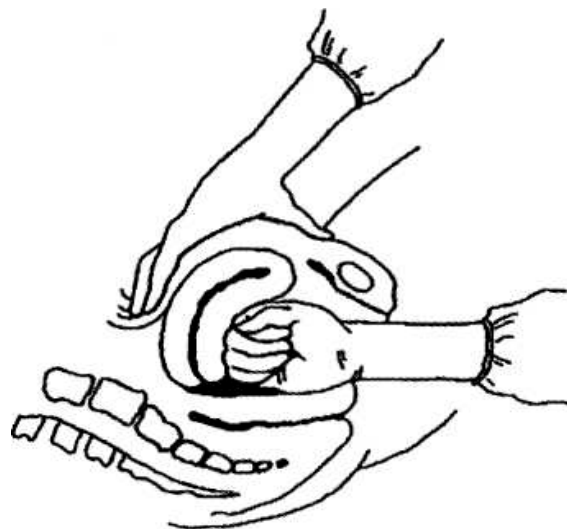


Fig. 6. Bimanual compression of the uterus

If bleeding resumes and blood loss volume makes 1.5 % and more of the body

weight, surgical treatment is indicated — extirpation of the uterus without appendages; if bleeding continues — ligation of the femoral arteries.

**Coagulopathic hemorrhages** — hemorrhages caused by violations of the blood clotting system.

**Reasons:** dead fetus, premature detachment of the normally located placenta, amniotic fluid embolism, after massive blood loss, at septic conditions, hereditary violations of the blood clotting system, etc.

THS arises, which is characterised by:

- 1) bleeding, which can not be explained by any other reason: for instance, continuous bleeding at well-contracted uterus and no injuries of the parturient canal;
- 2) the blood, which is running out of the uterus or wound, does not clot or clots poorly;
- 3) bleeding sickness is present;
- 4) fibrinogen content and thrombocyte number decrease below the critical level (accordingly less than 1.5 g/L and  $50 \cdot 10^9/L$ ).

**Diagnostics:** clinical presentation, monitoring of laboratory indices: prothrombin index, thrombocyte number, fibrinogen quantity in blood, the time of blood clotting is detected (if the system of blood clotting is violated, it exceeds 7—8 min, the clot is fragile, comes apart easily) and a test of blood clot dissolution is carried out: 2 ml of blood from the patient's vein is poured into a tube with a blood clot of a healthy woman of 2 ml volume, and if the clot dissolves in 2—3 min, blood clotting in the patient is reduced.

**Traumatic injuries of the maternal passages:**

- a) injury of the vulva, vagina, clitoris — suturing, and in case of necessity compressing bandage of tampon type. At a clitoris injury — placing U-sutures. If a hematoma of the vagina forms, it is opened and the bleeding vessel is sutured;
- b) cervical rupture — suturing. At a cervical rupture of the 3rd degree — manual revision of the uterine cavity walls to exclude hysterorrhesis;
- c) hysterorrhesis — at complete and incomplete hysterorrhesis irrespective of blood loss volume it is necessary to urgently conduct operative intervention in the

volume of hysterectomy.

## **PARTURIENT MATERNAL TRAUMATISM**

Parturient traumatism of the mother is the injury of the soft tissues of the parturient canal, neck and body of uterus, which took place during the pathological course of delivery, untimely and unqualified obstetric help.

Cervical ruptures are observed in 6—15 % deliveries according to different authors. Hysterorrhexis makes 0.1—0.05 % of all deliveries.

The reasons for the injury of the soft tissues of the parturient canal is the most often unskilled perineum protection, delivery of a fetus with big weight, of an overmature fetus, or accelerated labor and also its prolonged character; incorrect fitting of the fetal head, narrow pelvis, breech presentation, rigidity, inflammatory changes of the perineum tissues, surgical delivery.

There are differentiated ruptures of the vulva, vagina, perineum, neck and body of uterus, inversion of uterus, postpartum fistulas, separation of symphysis and symphysiolysis.

Ruptures of the vulva, vagina, and perineum are the most frequent.

## **VULVA, VAGINA, PERINEUM RUPTURES**

**Vulva ruptures** usually take place in the region of the small lips of pudendum, clitoris and are a surface injury.

**Clinical presentation and diagnostics.** Injury is accompanied by external hemorrhage, sometimes rather intensive.

**Treatment.** Ruptures in the region of the small lips of pudendum are sutured with catling not touching the underlying tissues to prevent hemorrhage from the cavernous bodies.

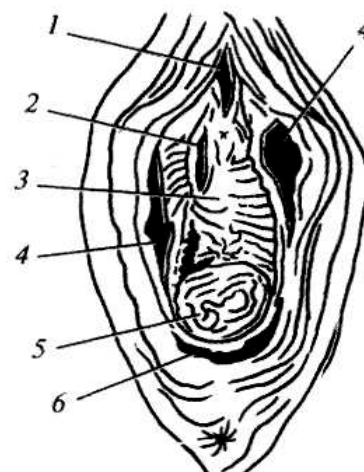
A catheter is introduced into the urethra before suturing ruptures in the region of the clitoris.

Uninterrupted or single sutures are inserted under local or intravenous anesthesia.

**Traumatic injuries of the vagina** (Fig. 7). If perineum rupture is localized in its lower third, it is often combined with vulva rupture.

Fig.7. **Ruptures of the external genitals and vagina:**

- 1 — of clitoris;
- 2,3 — anterior wall of vagina;
- 4 — mucosa of small pudendal lips;
- 5 — posterior wall of vagina;
- 6 — posterior commissure.



Vagina rupture in the upper third sometimes proceeds to the fronix of vagina and is then combined with the rupture of the neck of uterus. The middle part of the vagina is rarely injured due to its elasticity and ability to stretch. Sometime tissue ruptures takes place only in the deep submucosal layers and the mucous layer remains intact.

Vagina ruptures are most often longitudinal, less frequently — transversal, sometimes they penetrate deep into the paravaginal fat.

The code number ICD-10 O-71.4 indicates obstetric rupture of the upper part of the vagina only.

**Clinical presentation and diagnostics.** Clinically vaginal laceration declares itself either with hemorrhage or — at submucosal rupture, when a venous or arterial vessel is damaged, — hematoma formation. The code number ICD-10 O-71.7 indicates obstetric pelvic hematoma; O-71.8 — other adjusted obstetric injuries.

*Diagnostic criteria:*

- at examination — a tumor-like mass of blue-and-violet color;
- at vulva hematoma — the small and large lips are edematous, tense, of crimson coloring;
- vagina hematomas more often form in the posterior regions;
- the most frequently is a symptom of a hysterorrhexis not diagnosed during

delivery;

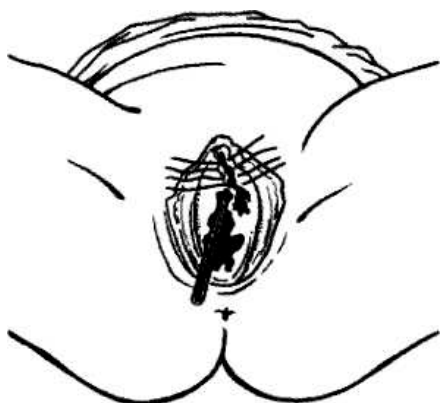- no subjective sensations at small hematomas;
- at quick increase of the hemorrhage in size there appears sensation of pressure, spreading, burning pain, laboratory investigation detects anemia signs;
- if hematoma is infected, pain increases, has a throbbing character, body temperature rises, hectic character of the temperature profile, leucocytosis in blood, ESR acceleration.

**Treatment.** Vaginal lacerations are sutured with single or uninterrupted sutures by the rules of the surgical treatment of wounds. If hematomas are small and do not progress in size, if there are no signs of infection, bed rest, cold, hemostatics, Z-sutures or uninterrupted sutures and antibacterial therapy are indicated (Fig. 8).

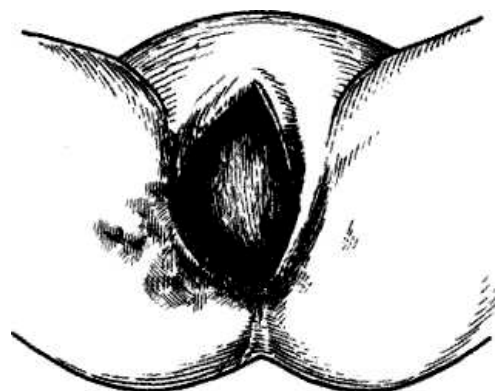
If hematomas are large (Fig. 9):

- the doctor is to follow the superior hematoma level through the abdominal wall by the method of deep palpation (if hematomas enlarge quickly);
- if hematomas enlarge, anemization increases, hemorrhagic shock signs appear, laparotomy is carried out with the purpose of internal iliac artery ligation. In 5—6 days the hematoma is dissected and drained for infection prevention. It is not expedient to dissect empty a light hematoma (thrombus abruption at thrombosed vessels resumes hemorrhage).

If hematoma is infected - dissecting, draining, antibiotics administration.



**Fig. 8. Closure of a rupture in the region of clitoris**  
(a catheter is introduced into the urethra)



**Fig. 9. Vulva hematoma**

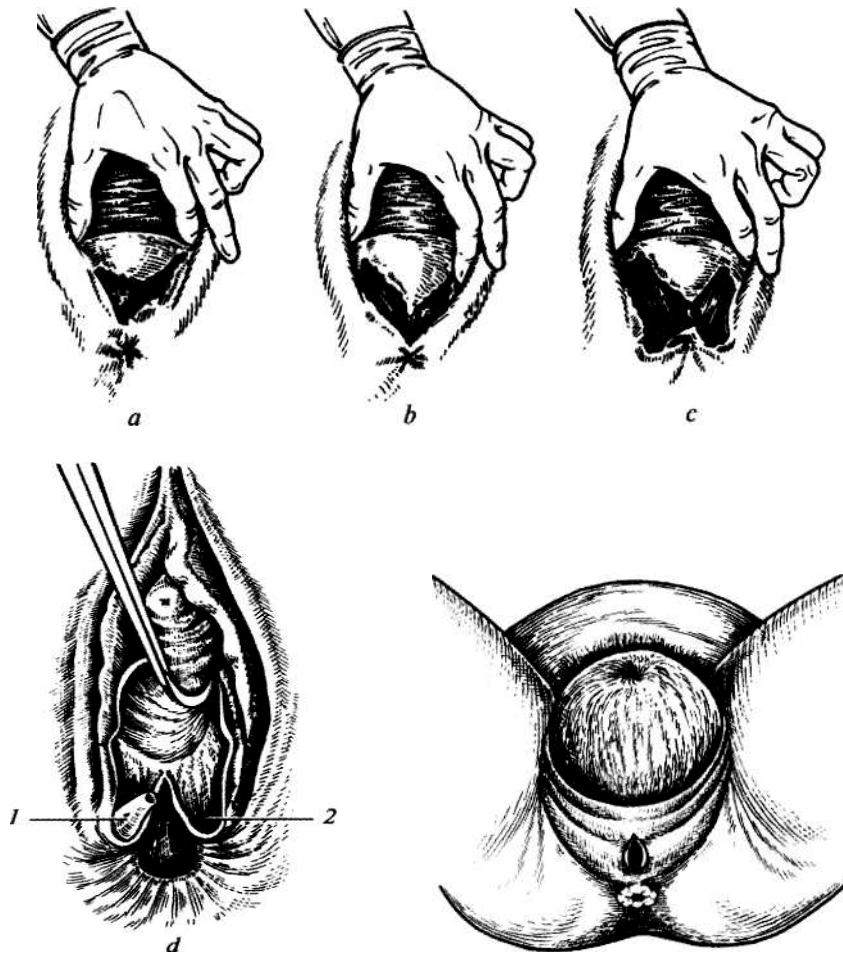


**Perineal ruptures.** There are differentiated spontaneous and forced perineal ruptures. The latter appear at technical errors of conducting vaginal embryotomies or incorrect rendering of manual aid.

*Perineal rupture degrees:*

— the 1<sup>st</sup> degree — rupture of the posterior perineal commissure, a small part of perineal skin (up to 2 cm), perineal muscles remain intact;

— the 2<sup>nd</sup> degree — damaged perineal skin, vaginal walls and perineal muscles. The sphincter and rectum remain intact;



**Fig. 10. Perineal rupture:**  
*a* - of the 1<sup>st</sup> degree; *b* - 2<sup>nd</sup> degree;  
*c* - 3<sup>rd</sup> degree; *d* - 3<sup>rd</sup> degree complete  
 (1 — a sphincter flap; 2 — the place of sphincter abruption)

**Fig. 11. The moment of central perineal rupture occurrence**

— the 3<sup>rd</sup> degree — except for the rupture of the perineal skin and muscles there ruptures the external sphincter of the rectum (incomplete rupture of the 3<sup>rd</sup> degree);

if the mucous tunic of the rectum ruptures, the 3<sup>rd</sup> degree rupture is complete.

A rare type of the injure is the central perineal rupture (Fig. 10): rupture of the posterior vaginal wall, pelvic floor muscles and perineal skin; the posterior commissure and sphincter of the rectum remain intact. Delivery takes place through this formed aperture.

Sometimes the perineal muscles are deeply injured (Fig. 11) without any violation of skin integrity.

***Clinical presentation and diagnostics.*** There are differentiated 3 main signs of perineal rupture threat: 1) superdistension of the perineum with the fetal head violating venous blood drainage, which is accompanied by tissue cyanosis; 2) perineum edema, testified to by tissue luster; 3) paleness of the perineal skin, which is a manifestation of arterial vessels squeezing, exsanguination of tissues, which can not resist further squeezing, which results in perineal rupture.

***Diagnostic criteria*** of perineal rupture: tissue defect, wound surface, hemorrhage from the maternal passages.

***The treatment*** is conducted in accordance with the generalwound treatment principles:

- every uninfected wound must be sutured during the first hour after delivery;
- perineal ruptures of the 1<sup>st</sup>—2<sup>nd</sup> degrees are sutured under local anesthesia (novocaine, lidocaine);
- the vaginal muscles, fat and mucous tunic, and perineal skin are sutured with polyglycogen filament;
- before suturing the damaged tissue is removed in the region of the wound lips with sharp scissors;
- sutures are inserted to renew anatomic correlations.

The operation of suturing perineal ruptures of the 1<sup>st</sup>—2<sup>nd</sup> degree begins with inserting a suture into the anterior corner of the wound; then 3—4 buried sutures on the perineal muscles (vicryl, chromic catgut); restoration of the perineal skin with the help of 3—4 silk ligatures or a subcuticular cosmetic suture;

- 3<sup>rd</sup> degree sutures are inserted under anesthetic (Fig. 12).

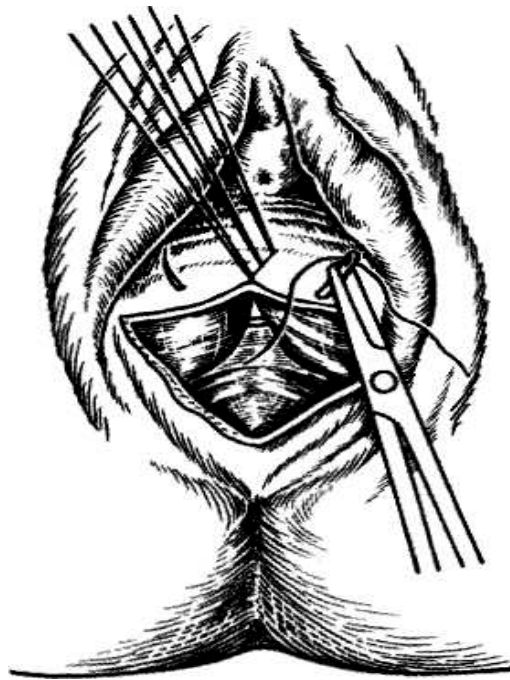


Fig.12. Suturing a 2<sup>n</sup> degree perineal rupture

Suturing consists of the following moments:

1. Restoration of the rectum and sphincter. At first, silk sutures are placed on the mucous tunic of the rectum with immersing knots into the lumen of the rectum. The muscular layer is sutured with chromic catgut, the knots are tied into the wound lumen.

2. Restoration of the rectum sphincter. The contracted part of the muscle is to be found. Then its integrity is restored with some vicryl sutures.

The tools are interchanged, the surgeon's hands are scrubbed. Further layerwise suturing is conducted as at the 1<sup>st</sup>—2<sup>nd</sup> degree rupture.

**Aftercare:** perineal sutures are processed 3 times a day and after every urination and defecation.

After processing the sutures are dried with a sterile gauze tampon and dubbed with potassium permanganate solution or 1 % brilliant green solution. Quicker wound healing is promoted by ultraviolet irradiation. The parturient woman is not recommended to sit during 2-3 weeks after delivery.

At the 1<sup>st</sup>-2<sup>nd</sup> degree perineal rupture fluid diet is administered during 4—5 days.

At the 3<sup>rd</sup> degree perineal rupture the patient is to have no excrements during 5

days after surgery (Fig. 13).

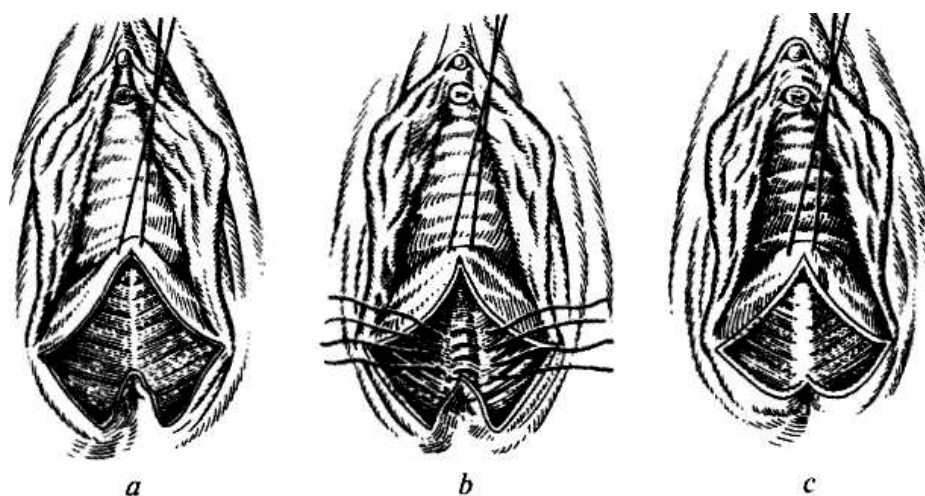


Fig. 13. Suturing a 3<sup>rd</sup> degree perineal rupture:

*a* — placing the first knot on the apex of the vaginal wall rupture;

*b* — placing submerged knots on the rectum sphincter;

*c* — the view after rectum sphincter reintegration (the 3<sup>rd</sup> degree rupture has turned into the 2<sup>nd</sup> degree rupture)

## CERVICAL RUPTURE

Cervical ruptures most often happen in the bottom-up direction, i.e. from the external mouth to the internal one.

*3 degrees of cervical rupture are differentiated by depth:*

— the 1<sup>st</sup> degree - cervical rupture from one or both sides not more than 2 cm long;

— the 2<sup>nd</sup> degree - a rupture longer than 2 cm, which does not reach the fornix of vagina (Fig. 14);

— the 3<sup>rd</sup> degree - a rupture of the uterine neck to the fornix of vagina or reaching the upper part of vagina.

The 3<sup>rd</sup> degree rupture is a severe type of obstetric traumatism, at which it is impossible to exclude the transition of the rupture to the region of the inferior uterine segment.

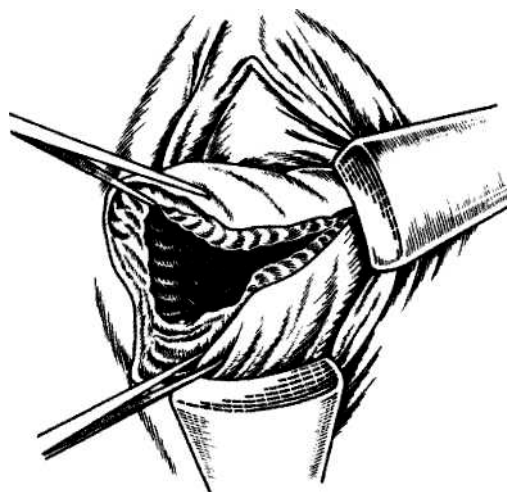


Fig. 14. 2<sup>nd</sup> degree cervical rupture

**Clinical picture and diagnostics.** Shallow ruptures 0.5—1 cm long are usually asymptomatic. Deeper ruptures are accompanied by hemorrhage. If the descending cervical part of the uterine artery is injured, the hemorrhage is rather voluminous and begins right after the fetus is born. Blood exudes in the form of a vermeil trickle if the placenta is detached and the uterus is well-contracted.

If the tissues are damaged because of being pressed to the pelvic bones with the fetal head, no hemorrhage may be observed though the tissues of the neck of uterus have been considerably injured.

If there is no bleeding, cervical ruptures may be identified only during vagina examination with the help of specula and smooth forceps.

**Treatment.** Cervical ruptures are sutured with single or uninterrupted sutures by the rules of surgical wound repair.

The 3<sup>rd</sup> degree cervical rupture is an indication to manual examination of the uterine cavity to exclude its lower segment rupture.

Cervical ruptures may be sutured with single- or multiple-layer sutures (Fig. 15).

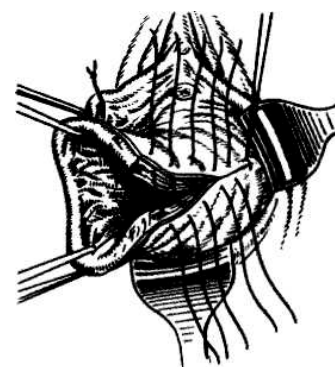


Fig. 15. Placing sutures in case of 2<sup>nd</sup> degree cervical rupture

There is a technique of later cervical ruptures suturing — after delivery, on the 3<sup>rd</sup>—5<sup>th</sup> day. In this case the muscular ring of the circular layer is formed, even

small ruptures are visible, but this technique requires removal of the damaged rupture margins.

## HYSTERORRHESIS

Hysterorrhexis is the violation of uterus integrity in any part during pregnancy or delivery.

According to different authors, hysterorrhexis frequency makes 0.03—0.005 % of the general quantity of deliveries. Maternal and perinatal mortality at this complication makes about 3—4 % and 40 % accordingly.

### *Hysterorrhexis classification:*

#### I. By pathogenesis:

##### 1. Spontaneous hysterorrhexis:

- at morphological myometrium changes;
- at a mechanical obstacle to fetal birth;
- at morphological myometrium changes and a mechanical obstacle to fetal birth combined.

##### 2. Forced hysterorrhexis:

- pure (at delivery vaginal surgeries, at an external injury);
- mixed (at different combinations of gross interference, morphological myometrium changes, a mechanical obstacle to fetal birth).

#### II. By the clinical course:

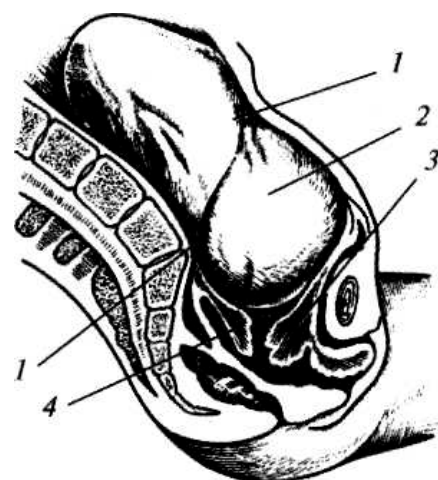
##### 1. Threatening hysterorrhexis (Fig. 16).

2. Hysterorrhexis, which has already taken place.

#### III. By the injury character:

1. Incomplete hysterorrhexis (not penetrating into the abdominal cavity; Fig. 17).

2. Complete hysterorrhexis (penetrating



**Fig. 16. Threatening hysterorrhexis (uterus has the appearance of an hourglass):**

1 — contraction ring; 2 — overstretched uterine segment; 3 — incarceration of the anterior lip of cervix uteri; 4 — posterior lip of cervix uteri

into the abdominal cavity; Fig. 18).

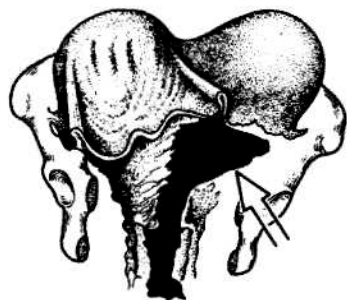


Fig. 17. Incomplete hysterorrhexis

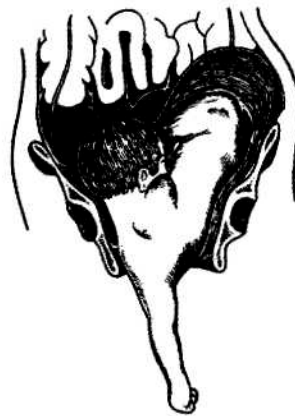

Fig. 18. Complete hysterorrhexis at transverse lie

#### IV. By the localization:

##### 1. Rupture in the lower uterine segment (Fig. 19):

- anterior wall rupture;
- lateral rupture;
- abruption of the uterus from the vaginal vaults.

##### 2. Rupture in the body of uterus:

- anterior wall rupture;
- posterior wall rupture.

##### 3. Rupture in the fundus of uterus.

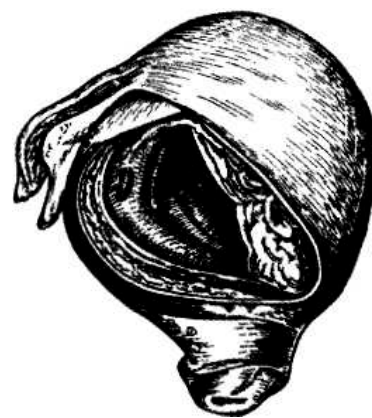

Fig.19. Complete hysterorrhexis in the inferior segment

***Etiology and pathogenesis.*** Mechanical obstacles to fetal birth and pathological processes of the muscular layer of uterus, which arise before or during pregnancy and delivery, are considered the main reasons for hysterorrhexis. The mechanical theory of hysterorrhexis emergence belongs to Bandl (1875). He explained hysterorrhexis during pregnancy by inconsistency of the presenting fetal part dimensions with the dimensions of the mother's pelvis. If there is an obstacle to fetus expulsion, rapid birth activity develops, the superior uterine segment contracts more and more, the fetus gradually moves into the thin-walled stretched inferior segment. Its superdistension and rupture happen especially easily if the uterine neck has not moved behind the fetal head and is jammed between it and a pelvic wall. At that, the contraction ring reaches the level of the navel; the uterus acquires the form of an hourglass. If birth activity is prolonged, superdistension and thinning of the inferior

segment reaches the highest level, its rupture takes place. At complete hysterorrhexis and great vessels damage hemorrhage into the abdominal cavity begins. If the uterus is ruptured in the anterior part of the inferior segment, or if it is torn from the vaginal vaults, the urinary bladder is sometimes drawn into the rupture. At incomplete hysterorrhexis there forms a hematoma depending on injure localization: between the leaves of broad ligament, under the uterine serosa, in the prevesical fat.

The theory of histopathic hysterorrhexis belongs to N.Z. Ivanov (1901) and Y.F. Verbov (1911). According to it, hysterorrhexis happens because of degenerative-inflammatory myometrium processes, its scar changes after surgical interventions on the uterus. Presently, it has been detected that at prolonged labor the metabolism is imbalanced, which is accompanied by accumulation of toxic compounds damaging the tissues — "biochemical uterine injure". Hysterorrhexis takes place against the background of weak and discoordinated contractions of the uterus.

Today, because of the expansion of indications to abdominal delivery, frequent reconstructive surgeries on the uterus, hysterorrhexis along the scar is observed more often.

According to the American Association of Gynecology and Obstetrics, when women with a scar on the uterus are delivering a child, hysterorrhexis is observed in 0.2—1.5 % at transversal dissection of the inferior segment, in 1—7 % cases at longitudinal dissection, and in 4—9 % — at corporal or T-incision of the uterus. I.F. Zhordaniya and L.S. Persianinov pay attention to mechanical and histopathic factors at hysterorrhexis. At that, histopathic myometrium changes are the background, against which the smallest errors in labor management may lead to hysterorrhexis. This rupture type differs from the one described by Bandl by the fact that pathological changes do not rupture, but kind of tear apart in the place of the deepest focal changes, therefore foreign authors use the terms "dehiscence, separation scar" and not "hysterorrhexis". When the scar tears apart, the extraembryonic membranes are intact, the fetus does not move into the abdominal cavity.

There are differentiated *force factors leading to hysterorrhexis*. They include: the Kristeller's maneuver, embryotomies, application of obstetric forceps, vacuum



extraction in the absence of conditions and violations of surgery technique. Hysterorrhexis may take place at an attempt to turn the fetus at neglected transverse lie, at fetal extraction by the pelvic pole under the condition of incomplete opening of the uterine mouth, at releasing the thrown back fetal arms and extracting the following extended fetal head.

Hysterorrhexis is promoted by long-term birth activity stimulation with oxytocin (10 IU), especially in women older than 30, mul-tipara, at multiple pregnancy, a large fetus, narrow pelvis.

***Clinical presentation and diagnostics.*** Hysterorrhexis clinical presentation is versatile. There are differentiated a threatening rupture, a rupture, which has already begun, and a rupture, which has taken place.

1. A "typical" hysterorrhexis takes place at inconsistent dimensions of the fetus and the mother's pelvis. A *threatening rupture* is conditioned by superdistension of the inferior segment. It is characterised by painful parodynia, the woman's wish to bear down at the high standing of the presenting part. The parturient woman screams, holds her hands on the stomach, asks for help, does not know what to do with herself. The face is frightened, the pupils are dilated, the pulse is accelerated, the lips and tongue are dry, body temperature rises, urination is complicated.

Examination and objective inspection show sharp painfulness at palpation of the inferior uterine segment, its tension, positive overriding symptom. Lower, at the level of the navel, the contraction ring is detected, the uterus acquires the form of an hourglass, the round ligaments are located asymmetrically, sometimes there is observed an edema of the external genitals and vagina.

Fetal heartbeat is difficult to auscultate because of abdomen tension and frequent labor pains; there develops acute fetal hypoxia, the fetus may die. A cardiotocogram records decelerations of different degree of intensity.

Vaginal examination not infrequently shows sufficient cervical dilatation, the uterine neck sags into the vagina since the presenting part is located high. A labor tumor is detected on the fetal head, head configuration is not infrequent. During parodynia at clinical inadequacy the head does not perform progressive motions, the

neck does not pull on the head, its edema takes place.

*At a rupture, which has begun*, the clinical presentation is conditioned by uterine wall integrity violation, blood vessel rupture, hematoma appearance in the myometrium. The parturient woman is excited, screams, has a strong feeling of fear, the pupils are dilated. The symptoms of the erectile stage of shock are observed.

Parodynia is painful, of convulsive character. There appears an irresistible wish to bear down at the high standing of the presenting part and sufficient cervical dilation. Blood-tinged discharge appear from the genital tracts, blood traces are found in the urine. Fetal cardiac function is violated, active fetal movements appear, sudden death may take place.

Vaginal examination usually shows sufficient cervical dilation, the head stands high, a labor tumor is found, there are no progressive motions of the fetus at sufficient cervical dilation, positive overriding symptom.

The clinical picture of *the rupture, which has taken place*, is characterized by the following signs: sharp pain in the abdomen at the height of one of labor pains, birth activity arrest, symptoms of the torpid stage of shock and intra-abdominal hemorrhage. The skin and mucous tunics become pale, the pupils dilate, the eyes are "sunken", the pulse is accelerated and weak, breathing is shallow, there appear nausea, vomiting, vertigo, loss of consciousness, arterial pressure decreases. After hysterorrhexis there quickly appears and increases meteorism as a result of bowels atony, hemorrhage from the vagina is observed, which increases at pushing the presenting fetal part. The fetus dies. When the fetus moves into the abdominal cavity, the abdomen of the parturient woman acquires irregular shape, small fetal parts are easily palpated through the abdominal wall. The well-contracted uterus is detected by the fetus. Symptoms of peritoneum irritation appear in connection with blood getting into the abdominal cavity.

2. The course of hysterorrhexis at histopathic myometrium changes has no evident clinical presentation.

During pregnancy histopathic hysterorrhexis happens at the presence of a scar on the uterus, its inability to stretch at fetal weight increase. The symptoms of rupture

threat are conditioned by overdistension of the scar tissue and peritoneum covering it. At that, vomiting, nausea, pain in the epigastric region appear due to reflexes; then they localize in the inferior parts of the abdomen, more on the right side. At uterus palpation attention is attracted by painful palpation of the uterus along the scar, sometimes the painfulness is local; indirect signs of its inability: recesses, roughness.

The clinical presentation of the rupture, which began during pregnancy, is detected by the presence of hematoma in the region of the scar. Nausea, vomiting, vertigo, pain along the scar, uterine hypertension, the signs of acute fetal hypoxia are characteristic. There may appear bloody discharge from the genital tracts.

During delivery at threatening histopathic hysterorrhexis the symptoms enumerated above are accompanied by the violation of the uterine birth activity: dystocia, weakness, restlessness of the parturient woman, painful, unproductive parodynia.

At a rupture, which has begun, during the first stage of delivery, in connection with hematoma presence in the uterine wall, the uterus remain tense between labor pains, becomes painful at palpation. Fetal hypoxia develops because of hypertension. There may appear bloody discharge from the genital tracts, especially against the background of parodynia weakening or arrest.

At the second stage of labor hysterorrhexis is characterised by parturient woman restlessness, pain in the underbelly, sacrum, weak and painful parodynia, which has a tendency to arrest, bloody discharge from the vagina, acute fetal hypoxia.

Symptoms of the histopathic hysterorrhexis, which has taken place, resemble the symptoms observed at a mechanical rupture, only that at the morphologically changed uterus they are not clearly marked and appear gradually. Hemorrhagic shock symptoms prevail. At histopathic hysterorrhexis due to gradual increase of tissue defect the fetus may be born alive through the natural maternal passages.

Hysterorrhexis may be suspected in the puerperal period on the basis of hemorrhagic shock symptoms.

In the course of any labor stage incomplete hysterorrhexis may take place. More often it is located in the lower uterine segment, between the leaves of the broad

uterine ligament, or under its serosa. Pains in the underbelly are characteristic, with irradiation onto the sacral part and into the leg. External hemorrhage may be absent. Internal hemorrhage symptoms appear in case of profuse bleeding. The woman's condition deteriorates, paleness of cutaneous coverings appears, the pulse is accelerated, ABP reduces. If the fetus was born without assistance at incomplete hysterorrhexis, a defect of the uterine wall may be detected at manual examination of the uterine cavity. Ultrasonography is used to clarify the diagnosis.

If a hematoma forms in the parametrium, during abdominal-vaginal inspection the uterus moves to the side opposite to the rupture, a mass without clear contours is palpated on its side, sometimes reaching the pelvic walls.

In some cases incomplete hysterorrhexis declares itself in a couple of days after delivery with the following symptoms: skin and mucous tunics pallor, pulse acceleration, ABT decrease, pains in the underbelly, meteorism, body temperature rise.

Abruption of the uterus from the vaults is a rather rare complication observed during delivery. The reason for this pathology is most often inadequacy between the presenting part and pelvic dimensions. The clinical picture of this complication is characterised by rapid birth activity or, vice versa, prolonged labor. The parturient woman feels severe tensive pains in the underbelly in the sacrum region. The presenting part does not perform progressive motions, it is tightly fixed in the pelvic inlet. The lower uterine segment is painful at palpation. Fetal condition worsens. Urination delay is marked, presence of blood in the urine. Moderate or profuse bloody discharge from the genital tracts is observed. Vaginal examination shows the edematous uterine neck, insufficient dilation. A defect of the vaginal fornix is found, which reaches the parametrium.

Hysterorrhexis is diagnosed on the basis of the clinical signs enumerated above. Differential diagnostics of threatening hysterorrhexis, hysterorrhexis, which has begun, and hysterorrhexis, which has taken place, is conducted with clinically contracted pelvis, acute appendicitis, detachment of normally located placenta, amniotic fluid embolism. Symptoms of the threat of uterus rupture along the scar

during pregnancy (usually in the 3rd period) not infrequently resemble the clinical presentation of appendicitis (nausea, vomiting, stomachache). At appendicitis the tongue is furred with farina, leucocytosis is detected, symptoms of peritoneum irritation are observed in the lower parts of abdomen on the right. To diagnose the disease one should find in the anamnesis the possibility of scar changes of the uterine muscle, perform ultrasonography with uterine walls investigation, measure the thickness and assess the structure of the region of possible scar presence.

Differential diagnostics of the threat and the rupture, which has begun, and clinically contracted pelvis is complicated. Clinically contracted pelvis is characterised by: 1) appearance of painful parodynia at the high standing of the presenting fetal part; 2) head fitting characteristic of the form of pelvic contraction; 3) evident head configuration or the absence of configuration at overmature pregnancy, evident labor tumor; 4) the absence of progressing motions of the head or buttocks at sufficient cervical dilation and energetic birth activity; 5) fetal hypoxia signs onset; 6) positive overriding symptom; 7) evident symptom of urinary bladder compression.

Histopathic hysterorrhesis, which has begun, during pregnancy and delivery should be differentiated from premature detachment of the normally located placenta. The diagnosis may be clarified with the help of ultrasonography. If it is impossible to differentiate hysterorrhesis, which has begun, from premature detachment of the normally located placenta, one should remember that both complications are indications to surgical treatment.

Hysterorrhesis, which has begun, should be differentiated from amniotic fluid embolism, which is most often observed at the end of the 1<sup>st</sup> and 2<sup>nd</sup> delivery stages. At embolism there quickly develops shock with symptoms of acute cardiovascular collapse, with a sharp pressure drop, onset of cyanosis, tachypnoe, dyspnea.

**Treatment.** If a pregnant woman belongs to the risk group of hysterorrhesis threat, a plan of delivery is worked out during pregnancy observation and by the 38<sup>th</sup>—39<sup>th</sup> week of pregnancy a decision is taken concerning the method of delivery (abdominal or through the natural maternal passages). Symptoms of anatomico-functional inferiority of the scar are:

- painful sensation in the region of the lower segment;
- pain at palpation of the lower segment through the anterior vaginal fornix, its heterogeneity, recess;
- at ultrasonography: lower segment thickness less than 4.0 mm, different sound conduction and thickness, balloon-like form.

Cesarean section in women with a threat of hysterorrhexis is performed:

- at a combination of contracted pelvis of the 1<sup>st</sup>—2<sup>nd</sup> degree and large fetal weight (388 g and more);
- at frontal fitting, at the high straight standing of the sagittal suture;
- at contracted pelvis of the 3<sup>rd</sup>—4<sup>th</sup> degree;
- at the maternal passages blacked with tumors;
- at cicatricial changes of the uterine neck, vagina.

During pregnancy at a threat of hysterorrhexis emergency cesarean section is carried out. During delivery at a threat of hysterorrhexis it is necessary to stop birth activity urgently and narcotize. If the fetus is alive, cesarean section is carried out. After abdominal wall section there may be observed serous exudate, urinary bladder edema, hemorrhages on the uterine serosa. The lower segment is usually thinned. The uterus is dissected in the lower segment very carefully not to damage vessels in the region of uterine sidewalls. After extraction of the fetus and placenta the uterus is to be thoroughly examined.

If the fetus is dead and there are necessary conditions, an embryo-tomy is carried out. If the doctor does not know the technique of the surgery, cesarean section is preferable. At transverse lie of the fetus cesarean section is also expedient. Such surgeries as fetal turning with its consequent extraction, application of obstetric forceps and vacuum extractor are absolutely contraindicated because of hysterorrhexis threat. Corporeal cesarean section is performed because of lower segment overdistension; if there is a scar in the lower uterine segment, its wall is dissected along the scar; before suturing the wound on the uterus the scar tissue is to be removed. Cesarean section peculiarities: the uterus is obligatorily withdrawn from the pelvic

cavity for thorough revision of its walls integrity.

An urgent surgery is indicated if hysterorrhexis has been detected. The parturient woman is transported to the operating theater immediately; if the woman's condition is grave, surgery is conducted in the labor ward. Urgent antishock therapy is conducted with central veins mobilization. Transfusion of blood components and substitutes is begun before the operation, continued during the operation and in the postoperative period till hemodynamics indices are stabilized.

The question of surgery extent is decided individually depending on the dimensions and localization of the rupture, the time, which has passed after the rupture, blood loss degree, infection, the woman's condition.

*Indications to an organ-sparing surgery:*

- incomplete hysterorrhexis;
- a linear rupture with even edges;
- the absence of infection signs;
- a small anhydrous space;
- preserved uterine activity.

*Indications to supravaginal amputation:*

—fresh ruptures of the uterine body with uneven crushed edges, preserved vascular bundle, moderate blood loss with any signs of THS and infection.

At terminal state of the patient surgical treatment is conducted in two—three stages with a surgical pause after arrest of bleeding, during which shock is fought.

*Indications to hysterectomy:*

- rupture of the body or lower segment of the womb, which has passed to the neck with crushed edges;
- impossibility to detect the inferior angle of the wound;
- rupture of the uterine neck passing to the body.

*Indications to extirpation of the uterus with uterine tubes:*

- preliminary indications at long-term anhydrous space (more than 10-12 h);
- manifestations of chorioamnionitis, endometritis;
- presence of a chronic infection.

In all cases of surgical treatment concerning hysterorrhexis or at cesarean section concerning threatening hysterorrhexis abdominal cavity draining is conducted.

At the end of the operation the urinary bladder, bowels, and ureters are examined.

At abruption of the uterus from the vaults hysterectomy is indicated. If hysterorrhexis is accompanied by bladder perforation, the bladder is sutured from the side of the abdominal cavity. If a ureter injure is suspected, methylene blue is introduced i.v. and its arrival to the abdominal cavity or into the urinary bladder at cystoscopy is traced.

At profuse hemorrhage the internal femoral arteries are ligated. At a big injure and considerable hemorrhage the internal femoral arteries are ligated before the beginning of the main extent of operation.

If there is no qualified specialist, who may ligate the internal femoral arteries, the operation is begun with clamping the mam vessels along the uterine sidewall.

The abdominal cavity is drained through an opening in the posterior fornix after extirpation and through counteropenings at the level of the femoral bones:

—at extraperitoneal hematomas formation the peritoneum is not sutured above them, drainage is conducted;

—in the postoperative period antishock, infusion-transfusion, and abacterial therapy is carried out together with thromboembolic complications prevention.

Even given the present state of medical aid at delivery, if complete hysterorrhexis takes place, prognosis for the fetus remains unfavorable because of placenta abruption. Prognosis for the mother depends on the volume of blood loss, severity of general condition, urgency of the rendered qualified aid.

Perinatal mortality at hysterorrhexis makes about 46 % (R.D. Eden et al., 1986) to 70 % (S.P. Rachagan et al., 1991).

Maternal and perinatal mortality at hysterorrhexis during pregnancy and delivery makes 3—4 % and 40 % accordingly.



## INVERSION OF UTERUS

Inversion of uterus is a severe pathology, at which the fundus of uterus falls out with its internal surface. If uterus inversion takes place at the placental stage, the placenta, which has not detached, falls out together with the uterus.

***Etiology and pathogenesis.*** Uterus inversion usually takes place at uterine hypotonia. Spontaneous uterus inversion is infrequent. Usually uterus inversion is promoted by a combination of the relaxed uterus and big pressure on it from above when conducting the Crede—Lazarevich's maneuver without preliminary massage of the uterus, and also sharp pulling by the umbilical cord at the placenta, which has not detached.

***Clinical presentation.*** In the placental or early puerperal periods severe sharp pains in the abdomen and shock signs appear (rapid pulse, skin pallor, ABP decrease).

The pain is caused by peritoneum irritation, tension and draw of the ligaments due to the change of organ topography. Inversion may be partial if only the body of uterus is everted, and complete, if the whole uterus is ectropic. If the uterus is not replaced, its necrosis takes place.

***Treatment.*** Uterine inversion requires urgent antishock measures and uterus replacement under deep anesthesia. After replacement the uterus is plugged with a sterile bandage, drugs contracting the uterus are introduced i.v.

If an attempt to replace the uterus was not successful, the uterus is to be extracted, preferably through the vagina.

### **Placenta praevia**

Placenta praevia develops when the impregnated egg implants on or near the isthmic part of the uterus. The growing placenta thus covers a portion of the lower uterine segment to close (partly or completely) the internal os of the uterus and underlie the presenting part. Classification: complete and incomplete placenta praevia (central or complete, lateral, marginal), low implantation of placenta.

1. Marginal placenta praevia. The placenta does not extend beyond the margin

of the internal os. When the endocervical canal opens to pass two or three fingers, smooth membranes and a narrow margin of the placenta can be palpated.

2. Lateral placenta praevia. The placenta covers the internal os by its margin and can be palpated by the examining finger (with the cervix dilated to pass 2-3 fingers) along almost the entire area except a small portion where the membranes show.

3. Complete, or central, placenta praevia. The centre (or almost the entire central part) of the placenta covers the internal os. When the cervix is dilated to pass 2 or 3 fingers, the placenta alone can be palpated. It is impossible to establish with certainty by the vaginal examination if the centre of the placenta lies over the internal os. The diagnosis of central placenta praevia is always stated in cases where the placenta alone can be palpated through the cervix dilated to pass 2 or 3 fingers.

4. Low attached type is also distinguished. The placenta is attached in lower uterine segment but its margin is impalpable by the examining finger even if the cervix is fully dilated. (Low implantation of the placenta.)

One type of placenta praevia sometimes passes to another during labor. For example, when the internal cervix is only slightly dilated (to pass 1 or 1½ finger) a small margin of the placenta can only be palpated (the marginal placenta praevia), but as the cervix is further dilated, a considerable portion of the placenta becomes palpable, i.e. the marginal placenta praevia turns into the lateral placenta praevia.

Since this classification is only schematic and conventional, some authors suggest that total and partial placenta praevia should only be differentiated. If the placental tissue alone is palpable through the cervix dilated to pass 2 or 3 fingers, the placenta praevia is referred to as total, and if both the placenta and the membranes can be palpated through the cervix, this would be referred to as partial placenta praevia. The degree of placental presentation is specified at dilatation of cervix uterus 5-6 cm.

In very rare cases implantation occurs in the cervix, and the placenta grows and develops in the endocervical canal of the uterus (or in the upper cervix and the isthmus).

## **Etiology**

The exact cause of implantation of the placenta in the lower segment is not known. The following theories are postulated.

- Dropping down theory: The fertilized ovum drops down and is implanted in the lower segment. Poor decidual reaction in the upper uterine segment may be the cause. Failure of zona pellucida to disappear in time can be a hypothetical possibility. This explains the formation of central placenta praevia.

- Persistence of chorionic activity in the decidua capsularis and its subsequent development into capsular placenta which comes in contact with decidua vera of the lower segment can explain the formation of lesser degrees of placenta praevia

- Defective decidua, results in spreading of the chorionic villi over a wide area in the uterine wall to get nourishment. During this process, not only the placenta becomes membranous but encroaches onto the lower segment. Such a placenta praevia may invade the underlying decidua or myometrium to cause placenta accreta, increta or percreta.

- Big surface area of the placenta as in twins may encroach onto the lower segment.

The predisposing factors for placenta praevia are - Multiparity, Increased maternal age (>35 years), History of previous caesarean section or any other scar in the uterus (myomectomy or hysterotomy), Placental size and abnormality (succenturiate lobes), Smoking - causes placental hypertrophy to compensate carbonmonoxide induced hypoxaemia. The causes: chronic endometritis, degenerative changes after abortion (especially repetitive, and abortions complicated with inflammatory diseases, seams and tumours of a uterus, late exhibitings of proteolytic properties of a trophoblast.

**Sequclacs of placenta praevia.** The condition is unfavourable for both the mother and the foetus. The central (total) placenta praevia is especially dangerous.

Cause of bleeding: As the placental growth slows down in later months and the lower segment progressively dilates, the inelastic placenta is sheared off the wall of the

lower segment. This leads to opening up of utero-placental vessels and leads to an episode of bleeding. As it is a physiological phenomenon which leads to the separation of the placenta, the bleeding is said to be inevitable. However, the separation of the placenta may be provoked by trauma including vaginal examination, coital act, external version or during high rupture of the membranes. The blood is almost always maternal, although fetal blood may escape from the torn villi especially when the placenta is separated during trauma.

Clinic: any bleeding in duration of gestation of 20-25 weeks in the absence of morphological changes of cervix uterus should be surveyed as a possible placenta praevia.

The unique symptom of placenta praevia is vaginal bleeding. Uterine bleeding - unique clinical manifestation of placenta praevia. The classical features of bleeding in placenta praevia are sudden onset, painless, apparently causeless and recurrent. The bleeding is unrelated to activity and often occurs during sleep and the patient becomes frightened on awakening to find herself in a pool of blood. The bleeding is unassociated with pain unless labour starts simultaneously. Obvious cause for the placental separation such as trauma or hypertension are usually absent. However, preeclampsia may complicate a case of placenta praevia. The first bout of bleeding is usually not alarming but subsequent bouts may be heavier than the previous one due to separation of fresh areas of placenta. In majority of cases, bleeding occurs before 38 weeks and earlier bleeding is more likely to occur in major degrees. However, there may not be any bleeding in central placenta praevia until labor starts. Asymptomatic cases may be detected by sonography or at the time of caesarean section.

Signs: General condition and anaemia are proportionate to the visible blood loss. But in the topics, the picture is often confusing due to pre-existing anaemia.

Abdominal examination:

- The size of the uterus is proportionate to the period of gestation.
- The uterus feels relaxed, soft and elastic without any localized area of tenderness.

- Persistence of malpresentation like breech or transverse or unstable lie is more frequent. There is also increased frequency of twin pregnancy.

- The head is floating in contrast to the period of gestation. Persistent displacement of the fetal head is very suggestive. The head cannot be pushed down into the pelvis.

- Fetal heart sound is usually present, unless there is major separation of the placenta with the patient in exsanguinated condition. Slowing of the fetal heart rate on pressing the head down into the pelvis which soon recovers promptly as the pressure is released is suggestive of the presence of low lying placenta especially of posterior type (Stallworthy's sign). But this sign is not always significant because it may be due to fetal head compression even in an otherwise normal case.

Vulval inspection: only inspection is to be done to note whether the bleeding is still occurring or has ceased, character of the blood - bright red or dark coloured and the amount of blood loss — to be assessed from the blood stained clothings. Atn placenta praevia, it is bright red as the bleeding occurs from the separated utero-placental sinuses close to the cervical opening and escapes out immediately.

Vaginal examination must not be done outside the operation theatre in the hospital, as it can provoke further separation of placenta with torrential haemorrhage and may be fatal. It should only be done prior to termination of pregnancy in the operation theatre under anaesthesia, keeping very thing ready for caesarean section.

Contra-indications for vaginal examination are:

Rate of a bleeding not always corresponds to a degree of a presentation and is much more connected to character contractive activity of the uterus. The bleeding at placenta praevia has wavy flow. Diagnostics bases on the data of an anamnesis, external and internal obstetric examinations, padding methods of examination. From results external obstetric examination the pelvic presentation or an improper lie of a fetus, a multiple pregnancy, the high level of the presenting part in a normal bony pelvis confirms, auscultation of pulsating hum of a placenta above a bosom are taken into account. Internal obstetric examination is carried out only in conditions of developed operational. Padding methods: ultrasonic.

## **Conducting pregnancy and labor**

Formulation of the line of treatment:

The definitive treatment depends upon the duration of pregnancy, fetal and maternal extent of the haemorrhage, the amount of the blood loss, the degree of the anaemia developed, preparedness of the birth canal for delivery, and the status of the foetus (viability, asphyxia, etc.).

Methods of the treatment:

Expectant treatment,           Active interference

Conduct of expectant treatment: bed rest with bathroom privileges, diet rich in vitamins, investigations - like haemoglobin estimation, blood grouping and urine for protein are done. The status of the pregnant should be strictly observed: her pulse rate and arterial pressure should be taken regularly. Periodic inspection of the vulval pads and fetal surveillance with USG at interval of 2-3 weeks. Supplementary haematinics should be given and the blood loss is replaced by adequate cross matched blood transfusion, if the patient is anaemic. When the patient is allowed out of the bed (2-3 days after the bleeding stops), a gentle speculum (Cusco's) examinations made to exclude local cervical and vaginal lesions for bleeding. However, their presence does not negate placenta praevia. Use of tocolytics and cervical circlage are not helpful.

If bleeding persists and haemoglobin and erythrocyte counts fall, operative delivery is indicated. In cases with profuse haemorrhage the patient should be operated on immediately for vital indications.

Termination of the expectant treatment: the expectant treatment is carried up to 37 weeks of pregnancy. By this time, the baby becomes sufficiently mature.

However, premature termination may have to be done in conditions, such as: recurrence of brisk haemorrhage and which is continuing, the foetus is dead, the foetus is found congenitally malformed on investigation. Repeated small bouts of haemorrhage is not an indication for termination of expectant treatment. Replacement of the blood loss can be made by blood transfusion. However, there is the risk of IUGR.

Steroid therapy is indicated if the duration of pregnancy is less than 34 weeks. Betamethasone reduces the risk of respiratory distress of the newborn when preterm delivery is considered.

Active interference:

The indications of active treatment are: bleeding occurs at or after 37 weeks of pregnancy. Patient is in labour. Patient is in exsanguinated state on admission. Bleeding is continuing and of moderate degree. Baby is dead or known to be congenitally deformed.

These are also contraindications for putting the patients to expectant regime. Depending upon the urgency of the situation, definitive treatment should be instituted as soon as possible.

Urgent hospitalization, at presence of an intensive bleeding a urgent delivery by cesarean section.

At a slight bleeding and premature pregnancy the woman remains in a hospital until to a delivery or until to an establishment of migration of a placenta by ultrasonic.

The best method of a delivery at placenta praevia considers operation cesarean section in scheduled order.

The delivery through natural birth canal can be carried out only then when the woman has arrived in a hospital in labor, without a bleeding, with incomplete placenta praevia, at absence of any padding complicating moments (the large fetus, a narrow pelvic). In such cases it is necessary immediately to rupture amniotic membranes, and labor to conduct expectantly, that is at presence of a bleeding to change tactics on operative.

One of the following operations should be used depending on the bleeding intensity, the status of the patient, the type of placenta praevia, etc.

Rupture of foetal membranes. The foetal membranes are recommended to be ruptured in marginal placenta praevia with longitudinal presentation and with the cervix dilated to pass 2 or 3 fingers. If intense bleeding, or other indications for urgent delivery are absent, the membranes can also be ruptured at lateral placenta praevia as well.

After the rupture of the membranes the placental separation discontinues, the head descends into the pelvis to compress the placenta praevia and thus to stop bleeding. The further labour is spontaneous. The membranes are often ruptured as a preparative step to some other operation (metreurynter, application of forceps, etc.).

**Metreurynter.** After the membranes have been punctured, a sterile pearshaped rubber bag, known as a metreurynter (or Voorhees' bag), is introduced into the uterus (in the coiled state). The bag is then unflated with a physiological saline solution through a tube, and a weight (200-400 g) is suspended by the tube. The inflated metreurynter presses by its weight the separated portion of the placenta to the lower uterine segment thus ensuring the intrauterine tamponade. The bleeding discontinues and the cervix dilates. When the dilation is sufficient, first the metreurynter and the foetus are delivered. Metreurynter is usually used in lateral (less frequently in marginal) placenta praevia. When after the rupture of the membranes, the head fails to descend and bleeding persists. This situation may occur in placenta praevia concurrent with uterine inertia.

**Forceps delivery.** If the head does not descend after rupture of the membranes in marginal and lateral placenta praevia and the bleeding persists, obstetric forceps can be applied. The skin fold on the foetal head is taken by the forceps of special design and a small weight (200-400 g) is hanged by the forceps handle to pull the head down into the pelvis. The engaged head presses the placenta against the lower uterine segment and the pelvic walls to stop bleeding. After the head is engaged and bleeding stopped, the forceps are removed and labour is continued spontaneously.

**Podalic version at incomplete dilation of the cervix (Braxton Hicks' version).** The Braxton Hicks version was often performed in past years when the cervix was dilated only enough to admit 2 or 2½ fingers. The foot of the foetus was extracted from the pudendal cleft to the knee level with subsequent traction by a small weight (200-400 g). The pelvic end of the foetus would descend to press the placenta against the lower uterine segment and the pelvic bones to discontinue bleeding. The Braxton Hicks version is now rarely used with incomplete dilation of the cervix (only



if the foetus is dead or premature, or if other obstetrical operations cannot be performed) because of its complexity: the cervix may be easily injured, or the foetus may be born dead.

The cervix may be ruptured in placenta praevia even by a moderate effort with development of fatal bleeding. The version should therefore be performed very carefully without traction by the foot or extraction of the leg above the knee. Extraction of the foetus by the leg is prohibited: the cervix will rupture and fatal bleeding develops.

**Caesarean section.** Placenta praevia is frequently an indication for an abdominal hysterotomy. This operation is performed in urgent cases with profuse bleeding which usually occurs in the central (total) and sometimes lateral placenta praevia.

Caesarean section is indicated also in placenta praevia concurrent with malpresentation of the foetus, and also in 'elderly' primiparous women provided they insist on delivery of a live infant).

Patients with placenta praevia should be treated during labour and post partum by blood transfusion, subcutaneous administration of physiological saline solution with glucose in order to prevent anaemia; cardiac drugs should also be given.

The puerperium in patients with placenta praevia is often complicated: the placental stage is prolonged because the placenta is attached in the lower uterine segment whose contractions are not intense. The placenta may be partly adherent. The abnormal separation of the placenta provokes more intense bleeding which may endanger the mother.

The general status of the woman, her pulse and arterial pressure should therefore be constantly observed and the amount of the blood lost strictly accounted. If the blood loss exceeds the allowable limit and anaemia develops, manual separation of the placenta should be performed immediately. After the placenta has been removed, the uterine cervix should be examined with specula and laceration, if any, sutured.

Infectious diseases may develop post partum because the placental site is close to the vagina and the resistance of the woman is impaired after loss of blood. The puerpera requires careful attendance and observation. General tonics and repeated blood transfusion are prescribed if necessary. Diseases of infectious etiology should be appropriately treated.

At presence of a dead fetus on his head impose skin-head forceps and to hang a load no more than 400.

At originating a bleeding even at a dead fetus it is necessary to apply operative tactics. At a placenta praevia operations of applying obstetric forceps or extraction of a fetus pelvic end counterindicative.

The third stage of labor is conducted awakely, with operation of manual separation and removal of placenta as partial adherence or even true adherence of the placenta frequently can be at placenta praevia.

**Premature separation of normally implanted placenta** (Syn: Accidental haemorrhage, Ablatio placentae, Premature separation of placenta)

Definition: It is one form of antepartum haemorrhage where the bleeding occurs due to premature separation of normally situated placenta. Out of the nomenclatures, abruptio placentae seems to be appropriate one.

### **Etiology**

The prevalence is more with (a) high birth order pregnancies with gravida 5 and above - three times more common than in first birth, (b) advancing age of the mother, (c) poor socio-economic condition, (d) malnutrition, smoking and (e) a tendency of recurrence in subsequent pregnancy is ten fold.

Hypertension in pregnancy is the most important predisposing factor. Preeclampsia, gestational hypertension and essential hypertension, all are associated with placental abruption. The association of preeclampsia in abruptio placenta varies 10-50 per cent. The mechanism of the placenta separation in preeclampsia is: Spasm of the vessels in the utero placental bed (decidual spiral arteries) → anoxic endothelial damage → rupture of vessels or extravasation of blood in the decidua basalis (retroplacental haematoma).

Trauma: traumatic separation of the placenta usually leads to its marginal separation with escape of blood outside. The trauma may be due to (i) Attempted external cephalic version especially under anaesthesia using great force, (ii) Road traffic accidents or blow on the abdomen, (iii) Needle puncture at amniocentesis.

Sudden uterine decompression: Sudden decompression of the uterus leads to diminished surface area of the uterus adjacent to the placental attachment and results in separation of the placenta. This may occur following - a) delivery of the first baby of twins (b) sudden escape of liquor amnio in hydramnions and (c) premature rupture of membranes.

Short cord, either relative or absolute, can bring about placental separation during labour by mechanical pull.

Supine hypotension syndrome: In this condition which occurs in pregnancy there is passive engorgement of the uterine and placental vessels resulting in rupture and extravasation of the blood.

Sick placenta: Poor placentation, evidenced by abnormal uterine artery Doppler waveforms, is associated with placental abruption.

Folic acid deficiency: Deficiency of folic acid without evidence of overt megaloblastic erythropoiesis has been blamed to be the cause of separation of placenta.

Torsion of the uterus leads to increased venous pressure and rupture of the veins with separation of the placenta.

Cocaine abuse is associated with increased risk of transit hypertension and placental abruption.

Thrombophilias inherited or acquired have been associated with increased risk of placental infarcts or abruption.

Depending upon the etiological factors, premature placental separation is initiated by haemorrhage into decidua basalis. The collected blood (decidual haematoma) at the early phase, hardly produces any morbid pathological changes in the uterine wall or the placenta. However, depending upon the extent of pathology, there may be degeneration and necrosis of the decidua basalis as well as the placenta adjacent to it.

Rupture of the basal plate may also occur, thus communicating the haematoma with the intervillous space. The decidual haematoma may be small and self limited; the entity is evident only after the expulsion of the placenta (retroplacental haematoma). The features of retroplacental haematoma are (a) Depression found on the maternal surface of the placenta with a clot which may be found firmly attached to the area. (b) Areas of infarction with varying degree of organisation.

The blood, so accumulated finds its way in the following directions:

- Complete accumulation behind the placenta which may be separated totally upto the margin where it is adherent to the uterine wall.

- Blood may dissect downwards in between the membranes and the uterine wall and ultimately escapes out through the cervix or may be kept concealed by the pressure of the fetal head on the lower uterine segment.

- The blood may gain access to the amniotic cavity after rupturing through the membranes.

It has to be remembered that absence of rhythmic uterine contractions plays a significant role for the blood to remain concealed.

Couvellaire uterus (utero-placental apoplexy): It is a pathological entity first described by Couvellaire and is met with in association with severe form of concealed abruptio placentae. There is massive intravasation of blood into uterine musculature upto the serous coat. The condition can only be diagnosed on laparotomy.

The causes: toxemia, chronic diseases which invoke sclerotic changes of tissues and vessels - an idiopathic hypertensia, a nephritis, a diabetes, postterme pregnancies, a multiple pregnancy, a hydramnion, heart diseases, lack of vitamin C.

The causes which invoke: a short navel, a trauma, fast reduction of a hyperinflated uterus.

Variants of clinical current:

1. Grade - 0: Slight separation it is not diagnosed till the moment of fetus birth. Clinical feature may be absent. The diagnosis is made after inspection of placenta following delivery.

2. Grade - 1: (i) External bleeding is slight. (ii) Uterus - irritable, tenderness may or may not be present. (iii) Shock is absent. (iv) FHS is good.

3. Grade - 2: Local separation in the dimension from one quarter of a placenta routinely has the acute beginning, local pains, hypertone of a uterus, fetal hypoxia (or intra-uterine death of fetus), internal, sometimes outside bleeding. External bleeding mild to moderate. Uterine tenderness is always present. Shock is absent.

4. Grade - 3: The placental separation on the big surface (or complete) has a pattern of a pain or hemorrhagic shock: vertigo, noise in the ears, arterial pressure falls, pulse is frequent, soft, accelerated, cool sweat, hypertone of uterus, the uterus grows in size, its consistency becomes firm (may be as hard as wood), and the shapes become ovoid or irregular, small fetal parts become impalpable, intra-uterine death of fetus. Bleeding is moderate to severe or may be concealed. Shock is pronounced. Associated coagulation defect or anuria may complicate.

The clinical features depend on: (i) degree of separation of placenta, (ii) speed at which separation occurs and (iii) amount of blood concealed inside the uterine cavity. But they may be very deceptive in posteriorly implanted placenta.

Treatment:

Only at slight placental separation it is possible to carry out waiting tactics, immediately rupture amniotic membranes, that sometimes prevents the further placental separation. In all other cases the immediate delivery is recommended by operation of applying obstetric forceps (at presence of conditions) or (more often) cesarean section. After uterus bleeding it is necessary to decide the problem of uteroectomy as development of the DIC-syndrome is possible.

Urgent obstetrical aid is required. The following main principles underlie the treatment of premature placental separation: (1) sparing stimulation of complete vaginal delivery; (2) control of acute anaemia and shock.

The choice of the method of delivery depends on the degree of anaemia and the conditions for obstetrical operations.

If the placenta is separated during pregnancy or in the beginning of labour

(dilation stage), a caesarean section is indicated because the foetus cannot be born rapidly by normal delivery through the natural birth canal.

If the cervix is fully dilated, the foetal membranes should be ruptured, the foetus turned (podalic version) and extracted from the birth canal. The placenta should then be immediately removed.

If the foetal head has entered the pelvic cavity and the foetus is alive, obstetrical forceps should be applied. If the foetus is dead, the head should be perforated and the foetus extracted quickly using a cranioclast.

If the cervix is not fully dilated, the blood loss is not considerable, and the condition of the mother and foetus is satisfactory, the foetal membranes are ruptured. After the rupture of the membranes further separation of the placenta may discontinue and the labour may end by normal delivery. If the contractions are not strong enough, metreurysis is indicated to stimulate the uterine contractions and thus to accelerate labour.

Revealed type:

The patient is in labour: the labour is accelerated by low rupture of the membranes. Rupture of the membranes with escape of liquor amnii not only accelerates labour but it increases the uterine tone, thereby allowing the separated placenta to be compressed between the fetal bulk and the uterine wall. Oxytocin drip may be started to accelerate labour.

The patient is not in labour:

Pregnancy 37 weeks or more: Induction of labour is to be done by low rupture of the membranes with or without oxytocin.

Indications of Caesarean section are - (a) appearance of fetal distress, (b) amniotomy could not be done or amniotomy fails to control bleeding and (c) associated complicating factors. Whenever, there is confusion in the diagnosis with placenta praevia, the internal examination is to be done in operation theatre.

Pregnancy less than 37 weeks: (1) Bleeding, moderate to severe and continuing - low rupture of the membranes is quite effective. Oxytocin drip may be added. Labour

usually starts soon, Caesarean section is rarely indicated. (2) Bleeding slight or has stopped - the patient is put on conservative treatment as outlined in placenta praevia. Close observation of the mother and careful fetal monitoring (preferably CTG) is essential.

Mixed or concealed type:

Principles in the management of concealed type are: (1) To correct hypovolaemia and to restore the blood loss. Normal saline or haemaccel infusion is started. (2) To bring about effective uterine contraction and termination of the abruption process. Unlike placenta praevia, correction of hypovolaemia cannot solve the problem unless simultaneous termination of pregnancy is done. Initiation of uterine contraction is the only effective means to control haemorrhage in abruptio placentae. (3) To observe blood coagulation profiles at two hourly interval. (4) Close monitoring of maternal and fetal condition is maintained.

Definitive treatment: Blood sample is taken (as mentioned in revealed type).

Artificial rupture of the membranes is to be done at the earliest moment if the membranes are found intact. Oxytocin drip should be started, if not contraindicated. The advantages of amniotomy are: (1) to expedite delivery and (2) to minimise two other grave complications -renal cortical necrosis and blood coagulation disorders.

Vaginal delivery: Following rupture of the membranes with or without oxytocin, labour is usually completed quickly (usually within 6 hrs). Placenta with varying amount of retroplacental clot, is expelled most often simultaneously with the delivery of the baby.

Caesarean section: Place of caesarean section in concealed abruptio placentae is difficult to define unlike that of placenta praevia. Baby is invariably dead in severe cases and/or premature and for the mother vaginal delivery is safer than caesarean section. It is indicated in two extreme groups of cases.

Early - In early cases with unfavourable cervix where speedy vaginal delivery is not possible and there is good prospect of fetal survival.

Late - If, in spite of amniotomy and oxytocin, the progress of labour is delayed

(6-8 hrs) and instead, the general condition gradually deteriorates with appearance of complicating factors like oliguria or falling fibrinogen level or there is evidence of fetal distress. As previously mentioned, presence of Couvelaire's uterus per se is not an indication for caesarean hysterectomy. Caesarean delivery is now done much more frequently.

**Main causes of obstetric bleedings in III and postnatal stages:**

- Infringement of motor function of a uterus;
- Infringement of separation and abjection of a placenta;
- Infringement of a blood coagulation system; traumas of birth canal;
- Retention of placentas lobal.

The causes of increment of a placenta:

- After inflammatory processes;
- Owing to postoperative seams on uterus;
- Abortions in anamnesis;
- Leuomyoma of uterus;
- Development anomalies of uterus;
- Increased proteolytic activity of chorion.

**Degrees of placenta increment:** placenta adhaerens - increment at which chorion villi penetrate into decidua basal stratum, placenta accreta - chorion villi penetrate through all decidua basal stratum up to muscle stratum of uterus, placenta increta - chorion villi penetrate into depth of muscle stratum of uterus, placenta percreta — chorion villi penetrate muscle and serous stratum of uterus.

Obstetric tactics at pathology of attachment and elimination of placenta:

- careful awake - waiting tactics; duration of the third stage of labor compounds from 10 up to 30 minutes, for establishment of the fact of placenta separation there are enough 2-3 sings and if it does not it is necessary to apply outside methods of extraction afterbirth;

- at volume of hemorrhage up to 0,5% of mass of a body and a proceeding bleeding, deterioration of the puerpera common state at absence of outside bleeding



it is necessary to carry out manual removal placenta and extraction afterbirth;

- if during 30-40 minutes of absence of attributes of abruption of a placenta and outside and internal bleedings, it is necessary to establish the diagnosis of true increment placenta and attempt of separation placentae to carry out only at developed operational At establishment of true increment placentae the attempt of its violent abruptio leads to intensifying bleeding and perforation of the uterus. The stopping of bleeding is possible in this case only in the operative way - a hysterectomy;

- establishment of afterbirth defect at its survey is the indication to manual revision of the uterine cavity irrespective of presence of bleeding.

Parent bleedings in early hours of puerperium more often are connected with disorders contractive activity of the uterus (hypo-and atonic uterus). In hypotonic haemorrhage, the uterus loses the normal tone and contractive ability, but on mechanical, physical and pharmacological stimulations the uterus routinely answers by contraction. For an atonicity of the uterus are typical an absence of contractions and falloff tone of the uterus which does not react to above named stimulations. Blood dyscrasias coagulation disorders are less common cases of postpartum haemorrhage and have, as a rule, the secondary character. The conditions where such disorders may occur are abruptio placentae, jaundice in pregnancy, thrombocytopenic purpura, HELLP syndrome or in IUD.

Algorithm of rendering assistance (steps of management):

- a) To empty the bladder, if it is found full;
- b) Massage the uterus;
- c) Injective uterotics drip is started (10-20 units Oxytocin in 500 ml of normal saline) at the rate of 30-40 drops per minute;
- d) Manual examination of the uterus and uterine massage on a fist;
- e) Survey of birth canal and the tears are repaired;
- f) If bleeding continues - misoprostol 800 µg per rectum;
- g) Regeneration of circulating blood volume and hemorrhages;

h) At renewal of a bleeding and at volume hemorrhage of 1,5% and it is more from mass of a body - operative treatment: hysterectomy without appendages, and at continued of bleeding - ligation of internal iliac arterias.

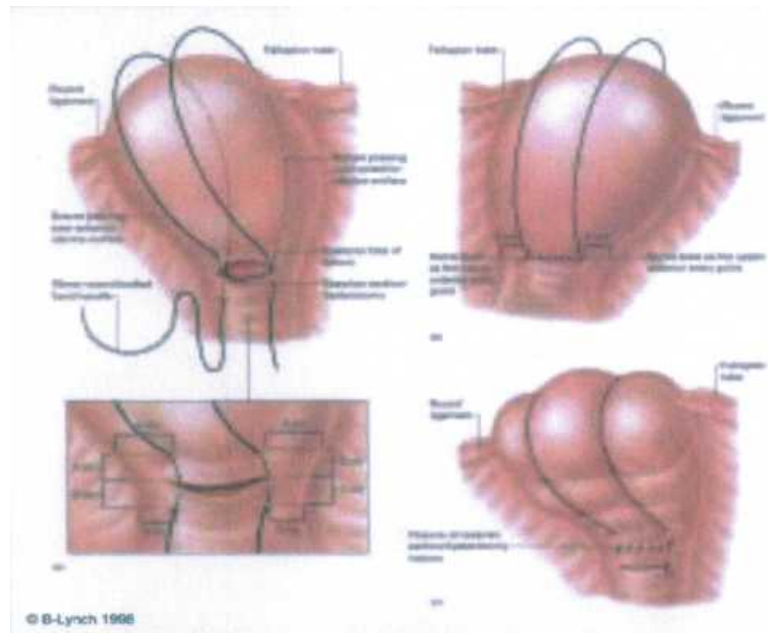


Fig.22. Hemostatic seam by B-Lynch

### Intensive Therapy of Massive Obstetric Hemorrhages

Physiological blood loss during delivery makes 0.5 % of body weight. At a blood loss exceeding the physiological (>0.8—1.2 % of body weight) microcirculation crisis arises — **hemorrhagic shock** (HS; Table 1).

Table 1. **HS Classification by the Clinical Course and Severity Degree**

(L.P. Chepyki with co-authors, 2003)

Severity degree	Shock stage	Blood loss volume	
		% blood volume	% body weight
1	Compensated	15-20	0.8-1.2
2	Subcompensated	21-30	1.3-1.8
3	Decompensated	31-40	1.9-2.4
4	Irreversible	>40	>2.4

HS is an acute cardiovascular collapse conditioned by inadequacy of the circulating blood volume with the bloodstream capacity, which is caused by blood loss and is characterised by the imbalance between tissue need in oxygen and the speed of its real supply. This is the severest complication at pathological bleeding.

*The 1<sup>st</sup> degree of HS* (moderate — blood loss makes 0.8—1.2 % of body weight) — moderate hypovolemia. General condition is moderately severe. Consciousness is not lost, weakness, palpitation. Cutaneous coverings are pale. Pulse — 90—100 bpm, ABP > 100 mm Hg, CVT - 80-100 mm of water.

The balance between blood volume and bloodstream capacity is maintained at the expense of a spasm of mostly venous vessels of the parenchymal organs, as a result of emission of catecholamines, aldosterone, ACTH, antidiuretic hormone, glucocorticoids, rennin-angiotensin, which sustains central hemodynamics for some time and provides normal functioning of vitally important organs (the brain, heart, kidneys).

*The 2<sup>nd</sup> degree of HS* (evident - blood loss of 1.3-1.8 % of body weight) — evident hypovolemia. Pulse up to 120 bpm, ABP < 100 mm Hg, CVT — less than 60 mm of water. General condition is grave. Weakness, vertigo, blackout, thirst, hyperhidrosis, dyspnea, muffled heart sounds, lethargy. Evident paleness of cutaneous coverings, acrocyanosis, extremity coldness. There develops severe tissue hypoxia, decompensated acidosis, activated emission of biologically active substances (serotonin, kinin, prostaglandins, histamine, etc.), vessel dilation. Disproportion between blood volume and bloodstream capacity increases.

*The 3<sup>rd</sup> degree of HS* (severe - blood loss of 1.9-2.4 % of body weight) — severe hypovolemia. Hemodynamics is considerably violated, the patient's condition is grave and is assessed as critical, psychataxia, stupor, anxiety, body temperature reduction, sharp paleness of cutaneous coverings, peripheral cyanosis. Pulse up to 140 bpm, ABP < 70 mm Hg, CVT - very low (40-0 mm of water).

*The 4<sup>th</sup> degree of HS* — extreme — blood loss more than 2.5—3 % of body weight. The woman's condition is critical, consciousness is lost. General paleness, mottled

extremities. Pulse is weak, sometimes can not be detected, only heart rate can be calculated, breathing is shallow, tachypnea, pathological motile excitation, hyporeflexia, anuria, low body temperature. Decompensated metabolic acidosis. Depending on the individual peculiarities of the organism, on the degree of anatomical and functional adequacy of vitally important organs, on the critical reserves of organs, dysfunction of an organ declares itself: shock kidney, shock lungs, shock liver.

***Basic principles of treating obstetric hemorrhages and HS:***

- 1) arrest of bleeding;
- 2) detecting the stage of compensated blood loss;
- 3) blood volume adjustment;
- 4) normalization of blood stream tone;
- 5) correction of hemorheology, blood structural, biochemical, and electrolytic composition, colloid-osmotic properties;
- 6) desintoxication;
- 7) desensitization;
- 8) correction of the clotting, anticoagulative, fibrinolytic and protease systems;
- 9) regulation of the activity of vitally important organs;
- 10) prophylaxis of infectious complications.

Blood volume adjustment is the basis of infusion program at acute blood loss. Organism can survive having lost 2/3 of corpuscular volume, but will not sustain a loss of 1/3 plasma, besides, hypoxia at massive blood loss is a result of circulatory, and not hematic insufficiency.

At the 1<sup>st</sup> degree of HS there are used blood substitutes with rheological action (rheopolyglucin with albumin, lactosol in different combinations), hydroxyethylized starch (6 % solution of refortan and stabisol) in combination with crystalloids (Ringer's solution, lactasol, quartasol) in the ratio 1:2. It is not expedient to use glucose solutions to adjust blood volume at HS, since glucose quickly moves to the in-tracellular centre not increasing blood volume considerably but only causing cellular hyperhydration.

At accompanying THS and also with the purpose to prevent it one is recommended to use fresh frozen plasma (up to 600—800 ml/day), cryoprecipitate.

At blood loss exceeding 1.0 % of body weight, to restore system hemodynamics and increase blood oxygenation (at hemoglobin content less than 80 % and hematocrit less than 25 %), after introducing blood substitutes one should start blood preparations transfusion. At blood loss of 2—2.5 % of body weight it is possible to connect artificial oxygen carrier — perftoran in the dose of 1.5—5 ml/kg. Transfusion of untested donor blood (so-called 'direct') according to the Law of Ukraine On the Prevention of Developing Acquired Immunodeficiency Syndrome (AIDS) and Social Security of Population, Chapter II, Article 10, is carried out in exceptional cases, "when the patient's life is really threatened and the only way to save the patient is urgent blood transfusion, and there is no examined blood in reserve, 'direct' transfusion of blood not tested for HIV-infection is allowed under the agreement of the patient or her legal representative. At that, the patient or her legal representative must be warned about the possible contagion risk. If the patient is unconscious, the decision about transfusing blood not tested for HIV-infection is made by a council of physicians, which must be testified in writing in the medical history" (the Order No. 5.09.05/671 of the Ministry of Public Health of Ukraine of 11.26.98). A specimen of transfused untested blood must be immediately sent for appropriate laboratory investigation.

At HS of the 2<sup>nd</sup> degree active therapy is necessary and the most important is transfusion of fresh donor blood and administration of colloidal and crystalloid solutions in the ratio 1:1.

ITT should be begun with blood substitutes on the basis starch (refortan, stabisol) and gelatin (gelofuzin).

If i.v. introduction of 800—1000 ml of any blood substitute with the speed of 50—100 ml/min does not lead to a change (increase) of ABP, there is evident pathological depositing and further increase of the volume velocity of infusion is inexpedient. In this case, not stopping the infusion of blood substitutes, vasopressors are used (remestyp — from 0.2 to 1.0 mg; dopamine to 5 mcg/kg/min or glucocorticoids — hydrocortisone up to 1.5—2.0 g/day and other). Repeated infusion of FFP is

pathogenetically justified as well as at previous stages (up to 400-600 ml 2-4 times a day).

At the 3<sup>rd</sup> stage of HS all the measures mentioned above last. Transfusion of concentrated red cells is expedient only after stabilization of hemodynamics and peripheral circulation. With antifibrinolytic purpose there are introduced inhibitors of proteases and tranexame acid — 500—700 mg on physiologic saline (Table 2).

After the surgery is over (hysterectomy) and till microcirculation crisis is eliminated, adequate functions of the respiratory, cardiovascular and excretory systems are recovered, prolonged ALV is conducted. Prevention and treatment of respiratory distress are also necessary.

At all stages of HS for simultaneous multicomponent therapy one should use 2—4 veins at one stage (one or two of them — central).

Infusion-transfusion therapy should be carried out taking control of pulse, ABP, CVT, hourly diuresis, hemoglobin, hematocrit.

Untimely or inadequate HS treatment causes a prolonged period of microcirculatory bloodstream dilatation, which is accompanied by transition of the intravascular fluid and fine-dispersed protein (albumin) into the interstitial stream. The blood serum clots, its rheology is violated, erythrocytes, thrombocytes and cells of vascular endothelium disintegrate and aggregate, thromboplastin accumulates, sedimentation processes activate, prothrombin changes to thrombin, fibrinogen — to fibrin. THS of blood develops.

**THS** is a complex pathological syndrome based on the activation of vascular-thrombocyte or coagulation hemostasis (external or internal), as a result of which at first blood clots in the blood stream, blocks it with fibrin and cellular aggregates, and if the potential of the coagulation and anticoagulation systems is exhausted, loses the ability to coagulate, which declares itself as profuse bleeding and development of the symptom of multiple organ failure.

***Classification:***

1. By the clinical course: acute, subacute, chronic, recurrent.
2. By the clinical stages of the course (Table 3,4):

- the 1<sup>st</sup> — hypercoagulation;
- the 2<sup>nd</sup> — hypocoagulation without generalized activation of fibrinolysis;
- the 3<sup>rd</sup> — hypocoagulation with generalized activation of fibrinolysis;
- the 4<sup>th</sup> — complete incoagulability of blood.

THS develops against the background of HS and is characterised by pathological changes in the systems of coagulation and anticoagulation, vascular-thrombocyte hemostasis, in the fibrinolytic and protease blood systems.

**Clinical presentation:** clinical manifestations of acute THS are connected with ischemic and hemorrhagic lesions of organs and tissues, which have a branched network and declare themselves with:

- 1) hemorrhages of skin, mucous tunics;
- 2) hemorrhages from injection sites, incisional wounds, uterus, etc.;
- 3) necroses of some areas of skin and mucous tunics;
- 4) CNS manifestations — euphoria, disorientation, clouded state;
- 5) acute renal, hepatic, pulmonary, adrenal insufficiency.

**Table 2. Infusion-Transfusion Therapy of Obstetric Blood Loss (O.M. Klytunenko, 2002)**

Infusion-transfusion media				Thrombo-concentrate	
Colloids	Natural	Packed red blood cells, ml/kg			
		FFP, ml/kg	Albumin (10-20 %), ml		
Synthetic					
Refortan, gelifusin, etc., ml/kg					
10	-	-	-	-	-
10	5-10	-	-	5	-
7	10-15	200	200	10-20	-
10-15	15-20	200	200	30	-
Up to 20	>20	>200	>200	>30	4-10 U

Blood loss volume	CBV deficit, %	10-20	20-30	30-40	40-70	>70	Crystalloids (0.9%,NaCl solution, Ringer's solution, etc.), ml/kg		
		Total transfusion volume (in % to CBV deficit)	500.0-1000.0	1000.0-1500.0	1500.0-2000.0	2500.0-3000.0		> 3000.0	10-15
			1-1.5	1.5-2.0	2.0-2.5	2.5-3.6		>3.6	200 (up to 3 L)
			180 (up to 4 L)	170 (up to 5 L)	150 (>6 L)	7		7	10
			200 (up to 3 L)	180 (up to 4 L)	170 (up to 5 L)	7		7	10
			200 (up to 3 L)	180 (up to 4 L)	170 (up to 5 L)	7		7	10
			200 (up to 3 L)	180 (up to 4 L)	170 (up to 5 L)	7		7	10
200 (up to 3 L)	180 (up to 4 L)	170 (up to 5 L)	7	7	10				

Table 3. THS Diagnostics

THS stages	Clinical manifestations	The character of coagulation properties of blood
I	Hyperemia of the cutaneous coverings with cyanosis, cutis marmorata, rigor, restlessness	Activization of the kalikrein ki-nin system, intravascular blood cell aggregation
II	Increase of hemorrhage from the genital tracts, injured surfaces, petechial skin rash, nose bleeding. The blood, which is running out, contains loose clots, which are lysed quickly	Exhaustion of the hemostatic potential, consumption of the VIII, V, XIII factors, fibrinogen, thrombocytes, activation of local fibrinolysis
III	Discharge of liquid blood, which does not coagulate. General bleeding sickness of injection sites, operative field, hematuria, hemorrhagic exudates in the serous sac	Sharp exhaustion of coagulation factors as a result of the formation of a large quantity of thrombin. Inflow of plasminogen activators into the bloodstream
IV	Discharge of liquid blood, which does not coagulate. General bleeding sickness of injection sites, operative field, hematuria, hemorrhagic exudates in the serous sac	Extreme hypocoagulation. High fibrinolytic and anticoagulation activity



Table 4. Laboratory Criteria of THS Stages

THS stages	Basic laboratory indices						
	Time of blood clotting by Lee-White, min	Spontaneous clot lysis	ACTC sec	Thrombocyte number • 10 <sup>9</sup> /L	Prothrombin time, sec	Thrombin time, sec	Fibrinogen, g/L
I	<5	No	<30	175-425	<10	<24	>5
II	5-12	No	<30	100-150	12-15	>60	1.5-3.0
III	>12	Quick	60-80	50-100	15-18	>100	0.5-1.5
IV	>60	Clots do not form	>80	<50	>18	>180	Not detected or traces
Norm	6-9	No	30-40	150-300	11-12	16-20	2.0-4.5

**Treatment:**

1. The treatment of the fundamental illness, which has caused THS development (surgical intervention, medicamental and infusion therapy).

2. Intravenous stream introduction of 700—1,000 ml of warmed to 37° C fresh frozen plasma (FFP) containing antithrombin III. If bleeding does not stop, additional introduction of 1000 ml of FFP is necessary. On the following 2nd-3rd day FFP is used in the dose of 400—600 ml/day. If it is possible, antithrombin III is introduced every 3h.

3. Given the speed of the hypercoagulation stage changing into the hypocoagulation stage, no possibility of clear laboratory diagnostics of THS stage one should refuse from the routine use of the heparin.

4. Beginning from the 2nd stage protease inhibitors introduction is indicated depending on the stage (Table 5).

Table 5. Recommended Doses of Proteolysis Inhibitors Depending on the THS Stage

Drug, IU	THS stage
----------	-----------

	I	II	III	IV
Trasilol	-	50,000-100,000	100,000-300,000	300,000-500,000
Contrical	-	20,000-60,000	60,000-100,000	100,000-300,000
Gordox	-	200,000-600,000	600,000-100,0000	1,000,000-4,000,000

5. Restoration of blood clotting factors by means of introducing plasma cryoprecipitate (200 IU - the 2<sup>nd</sup> stage, 400 IU - the 3<sup>rd</sup> stage, 600 IU - the 4<sup>th</sup> stage). If it is possible, male recombinant VIIa factor (novoseven) is introduced, 60-90 mcg/kg (1-2 doses).

6. Thromboconcentrate - in case of thrombocyte number reduction to less than  $50 \cdot 10^9/L$  Thromboconcentrate dose is chosen depending on the clinical situation.

7. Local bleeding arrest from the wound surface in all cases by means of coagulation, vessels ligation, wound tamponade, application of local hemostatics.

HS treatment, especially with THS development, should be conducted by the obstetrician-gynecologist only together with the anesthesiologist and hematologist.

Autohemotransfusion (AHT) is applied in the group of women of high risk of uterine hemorrhages development.

**TERMINAL CONDITIONS IN OBSTETRICS:  
HEMORRHAGE SHOCK, DIC-SYNDROM**

**DIC-syndrome**

Educes at a dead fetus, premature separation normally implanted placenta, an embolism amniotic waters, after a massive hemorrhage which has arisen in afterbirth or postpartum stage, at septic states.

About presence of the DIC-syndrome it is possible to judge, if:

1) There is a bleeding which does not explained other cause: for example, the long bleeding though the uterus also was reduced well, and is not present damages of the birth canal;

2) The blood which follows from the uterus or from a wound, does not coagulate or coagulates badly;

3) General bleeding;

4) Comes not connected with other causes olig(an)uria;

5) The maintenance of Fibrinogenum and quantity of thrombocytes drops below critical level.

Main principles of treatment obstetrics bleedings:

1) Stopping of bleeding;

2) Definition of stage of the compensated hemorrhage;

3) Regeneration of circulating blood volume;

4) Normalization of tone of the vascular bed;

5) Correction of hemorheology, its structural, biochemical, electrolytic composition, colloidal - osmotic properties;

6) Desintoxication;

7) Deallergization;

8) Correction coagulative, anticoagulative, fibrinolytic and protease systems;

9) A regulation of activity of the vital organs;

10) Prophylaxis of infectious complications

Hemorrhagic shock and DIC-syndrome

Shock — crisis of microcirculation, its disability to provide adequate histic metabolism, to satisfy the requirements of tissues in Oxygenium, energetic products, to remove from organism toxic matters of metabolism. The leading pathogenetic moment is disharmony between the blood volume and the capacity of vascular bed.

## Classification of hemorrhagic shock (Bacer, P.G.Brjusov):

I degree: hemorrhage of 1,0-1,5% from body mass, the general average state, weakness, mental status is normal, integuments pallid, pulse 90-100, arterial pressure >100 mm Hg, CVP 80-100 mm H<sub>2</sub>O;

II degree: hemorrhage of 1,5-2,0% from body mass, general grave state, weakness, mental status is disordered, thirst, a sweating, a short wind, heart tones are deaf, block, the expressed paleness of integuments, acrocyanosis, cool inferior extremities, pulse <120, arterial pressure <100 mm Hg, CVP <60 mm H<sub>2</sub>O;

III degree: hemorrhage more than 1500 ml (2,0-2,5% from mass of a body), the general state grave extremely, mental status is obtunded, a stupor, disturbing, increase of body temperature, sharp paleness of integuments, peripheric cyanosis, pulse <140, arterial pressure <70 mm Hg, CVP <40 mm H<sub>2</sub>O;

IV degree: hemorrhage is more than 2,5-3 % mass of a body, general state grave extremely, consciousness is absent, general paleness, "marbling" extremities, pulse weak, sometimes is not defined, respiration superficial, tachypnoea, pathological motorial exaltation, hyporeflexia, anuria, increase of body temperature.

### Treatment:

At compensated haemorrhage (haemorrhage 15-20 % of circulating blood volume) is shown the infusion colloidal blood substitutes (rhefortan, stabisol, Polyglucinum, Gelatinolum, blood plasma) in a combination to crystalloids (solution Rhinger, laktosalt, quartasait) in the ratio 1:2.

At concomitant set of DIC-syndrome, and also with the purpose of its prophylaxis is recommended early use chilled plasma (600-800 ml), cryoprecipitatum.

At subindemnification of a circulation (hemorrhagic shock II stage) transfusion just prepared donor blood, colloidal and crystalloid solutions in the ratio 1:1.

In a stage of a reversible decompensation (a hemorrhagic shock III stage) with the antifibrinolytic purpose transfusion erythrocytic mass after stabilization of hemodynamic and peripheric circulation, inhibitors of proteases.

Energetic complex therapy: antiaggregates (Trentalum, niacin), cardiotonics (Korglykonum, strophanthin), antihypoxants (natrii succinate, cytochrome C), vaso-awake agents, correction of metabolic acidosis.

**DIC-syndrome** - complex pathological syndrome, in which basis massive coagulation of blood lays, which results to blockage of microcirculation by loose masses of fibrin and cells aggregantes in the vital organs (lungs, nephroses, liver, paranephroses, etc.) with development of their dysfunction.

**Classification of the DIC-syndrome:**

- I a stage - hypercoagulation. Clinics: hyperemia of skin with cyanosis, "marbling" drawing, chill, disturbing of the patient. In a blood - a hypercoagulation, intravascular aggregation of blood cells.

- II stage - generalized activation of fibrinolysis. Clinics: intensifying of bleeding from generative organs, from the damage surfaces, petechialis eruptions on the skin, the nasal bleedings, following blood contains loose clots of blood which are quickly lysed. In a blood - attrition hemostatic potential, intake VIII, V, XIII factors, Fibrinogenum, thrombocytes, activation of local fibrinolysis.

- III stage - hypocoagulation with generalized activation of fibrinolysis, repeated fibrinolysis. Clinics: abjection of fluid blood which is not coagulated, generalized bleeding of places of injections, of surgery field, hematuria, haemorrhagic exudates in serous sinuses. In blood - sharp attrition of factors of coagulation as a result of formation of plenty of Thrombinum, entering into blood-groove of plasminogen activators.

- IV stage - complete uncoagulation blood. Clinics: abjection of fluid blood which is not coagulated, generalized bleeding of places of injections, surgery field, hypocoagulation of extreme degree, high fibrinolytic and anticoagulative activity.

The causes of development of the DIC-syndrome:

- All types of shock (hemorrhagic, septic, anaphylactic);
- Premature separation normally implanted placenta;
- Embolism amniotic waters;

- Intra-uterine death of a fetus;
- Toxemia pregnant;
- Hypotonic bleedings;
- Hysterorrheses;
- Excessive stimulation of patrimonial activity;
- Cesarcian section;
- Destructive operations;
- Extragenital pathology;
- Septic abortion;
- Postpartum endometritis;
- Intensive uterine massage on a fist.

### **Classification:**

#### I. On clinical course:

- Acute;
- Subacute;
- Chronic.

#### II. On stages of flow:

- I a stage - hypercoagulation;
- II stage - hypocoagulation without the generalized activation of fibrinolysis (consumption coagulopathy);
- III stage - hypocoagulation with generalized activation of fibrinolysis;
- IV stage - complete uncoagulation blood.

### **Clinic:**

- 1) Haemorrhages on a skin, on mucosas;
- 2) Haemorrhages from places of injections, operational wounds, the uterus;
- 3) Necroses of some fields of skin and mucosas;
- 4) Manifeststions from the side central nervous system as euphoria, desorientation of blackout of consciousness;
- 5) Acute renal, hepatic, pulmonary, adrenal failure.

It is necessary to pay attention of students on the clinic signs, coagulating capacity of blood and laboratory parameters at the different stages of the DIC-syndrome

**Treatment:**

Infusions of chilled plasma are effective at all stages of DIC-syndrome.

Use of inhibitors of proteases (contrical, Trasylolum, Gordoxum).

Stimulation vascular-trombocytic link of hemostasis (Dicy-nonum, Etamsylatum).

Use tranexamic acid.

For improvement of microcirculation use drugs of deaggregative action (Trentalum, Curantylum).

Therapy of subacute DIC-syndrome on a background of purulent - septic processes and acute renal failure supposes wide use of the gravitational surgery of blood: plasmapheresis, plasmacytopheresis.

Amniotic fluid embolism.

The teacher explains that this pathology is one of the most problems in obstetrics. Many cases are unrecognized, the diagnostics being obstetric shock, postpartum hemorrhage, or acute pulmonary edema. It is necessary to stop on the predisposing factors (multiparity, age over 30, large fetus, intrauterine fetal death, meconium in amniotic fluid, strong uterine contractions, high incidence of operative delivery). The students describe clinical picture which includes the following: respiratory distress, cyanosis, cardiovascular collapse, failure of coagulation and hemorrhage, coma, death.

**Haemorrhagic shock in obstetrics**

**The hemorrhagic shock** - the acute cardiovascular failure caused by disharmony of volume of the circulating blood to container of a vascular bed which arises owing to a hemorrhage and is characterized by a disbalance between

requirement of tissues for Oxygenium and rate of its realy delivery.

Danger of a hemorrhagic shock arises at hemorrhage 15-20 % VCB (0,8-1,2% from mass of a body) or 750-1000 ml The hemorrhage which exceeds 1,5% from mass of a body or from VCB (-1500 ml) is considered 25-30 % massive.

Risk factors of development of a hemorrhagic shock in obstetrics:

1. Pathological premorbidal background:

- oligemia pregnant;
- . - congenital faults of a hemostasis;
- got infringements of a hemostasis.

2. Bleedings in early terms of gestation:

- abortion;
- ectopic pregnancy;
- hydatidiform mole.

3. Bleedings in late terms of gestation or in labors:

- premature placental detachment;
- placental presentation;
- hysterrrheses;
- embolism amniotic waters.

4. Bleedings after labors:

- hipo-or an atony of a uterus;
- delay of a placenta or its fragments;
- breakages of patrimonial pathes.



**Criteria of gravity haemorrhagic shock**

Index	Degree of the shock				
	O	I	II	III	IV
Volume of haemorrhage	? ml	750-1000	1000-1500	1500-2000	>2500
	% body mass	0,8-1,2	1,3-1,8	1,9-2,4	>2,4
	% CBV	<15%	15-20	21-30	31-40
Pulse, bmp	<100	100-110	110-120	120-140	>140 or<40
Systolic AP mmHg	N	90-100	70-90	50-70	<50
Shock index	0,54-0,8	0,8-1	1-1,5	1,5-2	>2
CVP, mm	60-80	40-60	30-40	0-30	? 0
The test "white stain"	N(2c)	2-3 c	>3 c	>3 c	>3 c
Hematocrit I/I	0,38-0,42	0,30-0,38	0,25-0,30	0,20-0,25	<0,20
Respirations	14-20	20-25	25-30	30-40	>40
Urine output ml/hr	50	30-50	30-50	5-15	0-5
Mental status	normal	slight disturbing	alarm, moderate disturbing	disturbing, pavor, confusion of consciousness	confusion of consciousness

Classification of a hemorrhagic shock on clinical coursing and a degree of gravity (Chepkij L.P., 2003)

Degree of the shock gravity	Stage of shock	Volume of haemorrhage	
		% CBV	% body mass
I	compensated	15-20	0,8-1,2
II	subcompensated	.21-30	1,3-1,8
III	decompensated	31-40	1,9-2,4
IV	irreversible	>40	>2,4

Difficulties of determining of haemorrhage in obstetrics are caused by an appreciable haemodilution of following blood by amniotic water, and also concealment of plenty blood in a vagina or a cavity of the uterus.

For rough determining a haemorrhage at pregnant is possible using of modified formula Moore:

$$BL = M \cdot 75 \cdot \frac{Ht_{init} - Ht_{act}}{Ht_{init}}$$

Where: BL - blood loss (ml); M - body mass pregnant (kg);  $Ht_{init}$  - initial hematocrit patient (l/l);  $Ht_{act}$  - actual hematocrit patient (l/l).

The arterial hypotension is considered a late and unreliable clinical sign of a haemorrhagic shock. Due to physiological hypervolemic autohaemodilution at pregnant the AP can remain invariable until the volume of a haemorrhage will not achieve 30%. Indemnification of an oligemia at pregnant passes, first of all, due to an activation sympathoadrenal system that shows a vasospasm and a tachycardia. The oliguria early joins.

Intensive therapy of haemorrhagic shock.

The general principles of treatment of an acute haemorrhage:

1. urgent stopping of a bleeding by conservative or surgical methods, in dependence on the cause of development of a bleeding.

2. regeneration CBV.
3. maintenance adequate gas exchange.
4. treatment of organ dysfunctions and prophylaxis poliorgan failures.
5. correction of metabolic infringements.

Prime actions at originating a hemorrhagic shock:

1. estimate the vital functions (pulse, arterial pressure, respiration rate, the mental status).

2. notify the responsible duty doctor obstetric-gynecologist or the substituent of the head physician on medical work about originating of bleeding and development of a haemorrhagic shock and to mobilize the personnel.

3. lift legs or the podal end of a bed (Trendelenburg's position) for rising venous recovery to heart.

4. turn pregnant on the left side for an avoidance of development aorto-caval syndrome, decreases of risk of an aspiration at a vomiting and maintenance of loose permeability of respiratory pathes.

5. catheterization of the one - two peripheric veins by catheters big diameter (№№ 14-16G).

If there is condition of possibility of approach of several peripheric veins does not have to catheterize the central veins since there is a danger of complications.

If there is condition of development of shock III-IV degree the catheterization of three veins is necessary, thus one of them should be central. Advantage at a catheterization of a vein should be given venesections v.brachiales or punctures and eatheterizations by Seldmger v.jugularis interna.

6. Collect 10 ml of a blood for definition group and Rhesus-accessories, two-dimensional compatibility, a haemo-globin content and hematocrit, carry out the Li-White's test prior to the beginning of an infusion of solutions.

7. Inhalation of 100 % of Oxygenium with rate of 6-8 l/minutes. Through a nose-facial mask or nasal cannula.

The further actions for liquidation of a haemorrhagic shock

1. jet intravenous infusion of crystalloids (0,9% solution NaCl, Ringer's solution, other) and colloids (gelofusin),

Rate, volume and components infusion therapy are determined by i shock degree and hemorrhage dimension.

At II-III degree of a shock, rate of an infusion should compound 100-300 ml/minutes.

Treatment of a hemorrhagic shock is the most efficient at the beginning of an infusion not later than 30 minutes from development of the first exhibiting a shock.

At a bleeding more than 2-2,5% from body mass it is necessary to include a synthetic oxygen carrier in therapy - perfortan in a dose of 1,5-5 mVkg.

Counterindicative using the solution of glucose in the program of infusion-transfusion therapy. Using of dextran (rhepolyglucin), 5% Al~ buminum solution is not recommended.

At haemorrhage no more than 20% CBV introduction of one crystalloids is possible (0,9% NaCl solution, Ringer's solution) in volume in 2-3 times more than hemorrhage volume.

Indications for a hemotransfusion define individually in each separate case, but it is necessary to be oriented on parameters of a haemoglobin and a hematocrit ( $Hb < 70 \text{ g/l}$ ,  $Ht < 0,25 \text{ l/l}$ ).

The woman in shock condition is not given fluid perorally.

2. Stop a bleeding by conservative or surgical methods, in dependence of the cause of bleeding occurrence.

3. Warm the woman, but do not overheat her as thus peripheral microcirculation is improved, and it can result in decrease blood supply in the vital organs. Introduced solutions also are preheated up to  $36^{\circ}\text{C}$ .

4. Catheterization of urinary bladder.

5. Inhalation of 100% Oxygenium with rate of 6-8 l/minutes, if necessary - AVL proceeds.

### Infusion-Transfusion therapy of obstetric haemorrhage

Volume of haemorrhage			Infusion-transfusion media										
CBV deficit %	%from body mass	Haemor-rhage (ml)	Common volume of Transfusion (% to CBV deficit)	Crystalloids (0.9%,NaCl solution, Ringer's sol.)	Colloids	Erythr. mass	Thrombo-concentrate						
					<table border="1" style="width: 100%; border-collapse: collapse;"> <thead> <tr> <th>Synthetic</th> <th>Natural</th> </tr> </thead> <tbody> <tr> <td>Refortan, gelofusin, etc.</td> <td>Freshly frozen plasma</td> </tr> <tr> <td></td> <td>Albumin (10-20 %)</td> </tr> </tbody> </table>	Synthetic	Natural	Refortan, gelofusin, etc.	Freshly frozen plasma		Albumin (10-20 %)		
Synthetic	Natural												
Refortan, gelofusin, etc.	Freshly frozen plasma												
	Albumin (10-20 %)												
10-20	1-1.5	500.0-1000.0	200-300 (2.5 L)	10-15 ml/kg	-	-	-						
20-30	1.5-2.0	1000.0-1500.0	200 (until 3 L)	10 ml/kg	5-10 ml/kg	5 ml/kg	-						
30-40	2.0-2.5	1500.0-2000.0	180 (until 4 L)	7 ml/kg	10-15 ml/kg	10-20 ml/kg	-						
40-70	2.5-3.6	2500.0-3000.0	170 (until 5 L)	7 ml/kg	15-20 ml/kg	30 ml/kg	-						
More 70	More 3.6	More 3000.0	150 (more 6 L)	Until 10 ml/kg	More 20 ml/kg	More 30 ml/kg	4-10 un.						

Indications for AVL:

- Anoxemia ( $\text{PaO}_2 < 60$  mm Hg at  $\text{Fi O}_2 > 0,5$ );
- Respiration rate is more 40 for a minute;
- Low respiratory effort (the patient is not capable to frame negative pressure in respiratory pathes of more than 15 sm  $\text{H}_2\text{O}$  at maximal effort);
- Hemorrhage 3% from body mass or is more than 35 ml/kg.

Criteria of arrest AVL:

- Stabilization of clinical state of the patient;
- Respiration rate is less 30 for a minute;
- Inspiratory effort is less than 15 sm  $\text{H}_2\text{O}$ ;
- $\text{PaO}_2/\text{FiO}_2 > 80$  mm Hg;
- Opportunity of the patient self-contained to increase volume of air which exhausts during one minute.

6. Laboratory observation: common analysis of blood, calculation of thrombocytes, a blood clotting time, coagulogram, electrolytic composition of a blood, ABC and blood gases.

7. Monitor observation: noninvasive definition of AP (at IV degree shock - invasive definition of AP), heart rate, pulsoxymetry, ECG, a thermometry, the control of a hourly diuresis. At a shock of III-IV degree on a background of carrying out of infusion-transfusion therapy - control CVP each 30-45 minutes.

8. At absence of attributes of decrease of cardiovascular failure (rising the AP, decrease tachycardia) carry out inotropic support of a myocardium with the help vasopressors (Dofaminum of 5-20 mkg/kg/min., Dobutaminum of 5-20 mkg/kg/min).

9. At appearance of signs of a coagulopathy carry out therapy of the DIC-syndrom in dependence of stage.

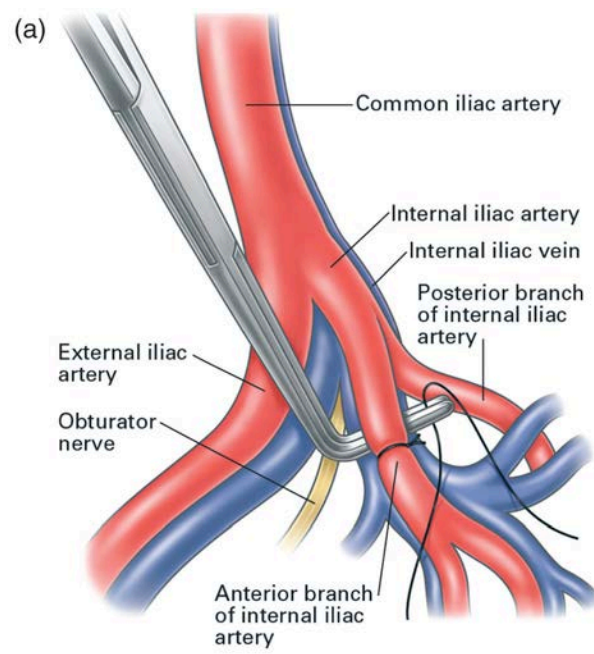
10. Correction of an acidbsis by soda provided that pH blood  $< 7,1$ .

After removing the patient from shock condition continue treatment in department of intensive therapy.

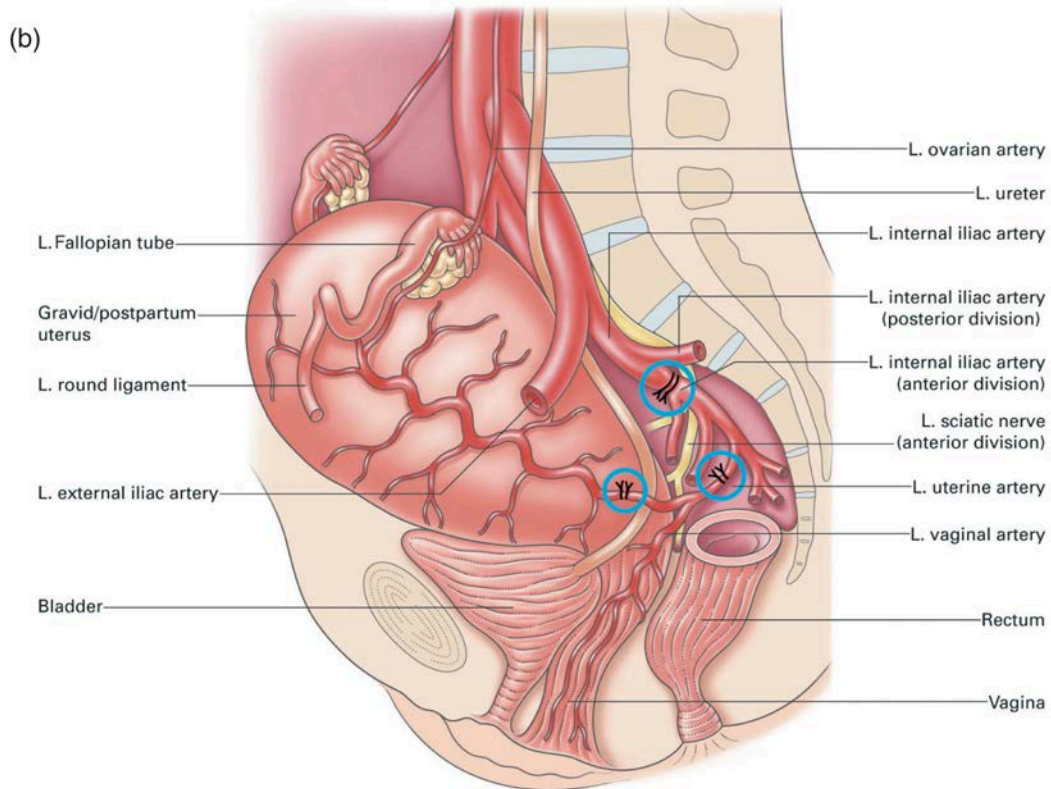
## Literature.

1. Клінічні протоколи з акушерства та гінекології МОЗ України. Наказ № 205 від 21.03.2014 — Київ
2. Ткаченко Р.О., Камінський В.В., Дубов О.М. та співавт. Комплексна інтенсивна терапія масивної коагулопатичної кровотечі в акушерстві/Методичні рекомендації-Київ.-2013.-22 стор./
3. Bakri balloon effectiveness for postpartum hemorrhage: a «real world experience»/ Olsen R., Reisner D.P., Benedetti T.J. // J. Matern. Fetal. Neonatal. Med. - 2013. - Vol. 26. – №17.- P.1720–1723.
4. Howkins and Bourne. Shaw's Textbook of Gynaecology. Edited by VG Padubidri and ets. Elsevier, India. 2002. – 508 p.
5. Obstetrics. D.C. Dutta. New Central book Agency, India, 2004. — 660 p.
6. Obstetrics / І.Б. Венцьковська та ін. — К.: Медицина, 2008. — 336 с.
7. Obstetrics ( clinical lectures) Zharkih A.V., Kabachenko E.V., Gaidai N.V., Nerjanov K.U. — «Просвіта», 2009. — 245 с.
8. Obstetrics and Gynaecology in 2 books. V.M. Zaporozhan, V.P. Mishchenko. — Odessa, The Odessa State Medical University, 2007. — 369 p.
9. Study of the uterine blood supply and its application in minimal surgical procedures / Palacios-Jaraquemada JM. // Minim Invasive Ther Allied Technol. – 2009. - Vol. 18. – №6. – P. 1-2.

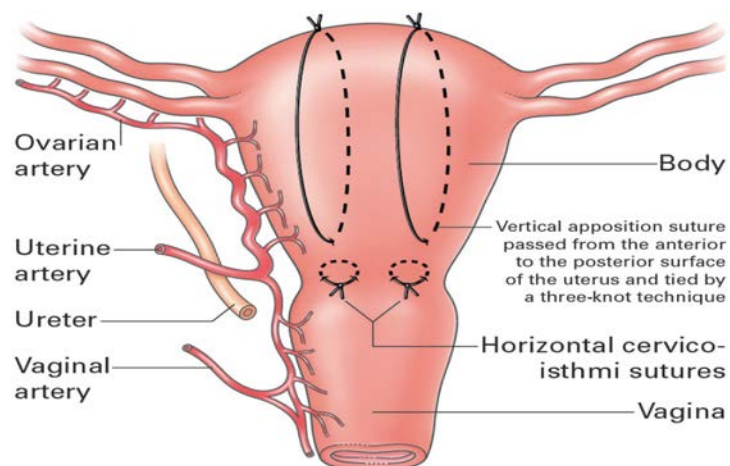
## Supplement



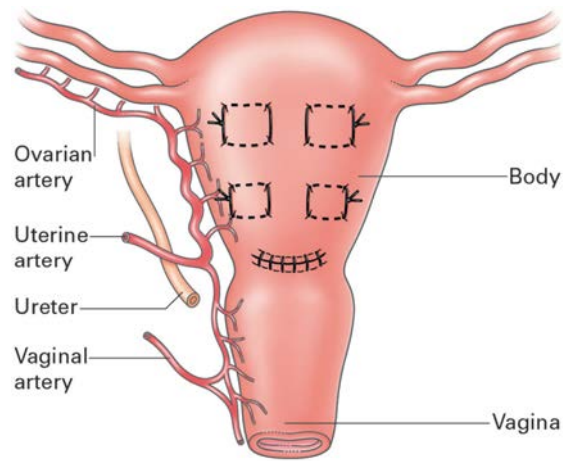




The complex vascular distribution to the pelvic organs. In this procedure of stepwise devascularization, the patient must be in the Lloyd Davis or modified lithotomy position, with one of the assistants able to access and swab the vagina to assess bleeding control

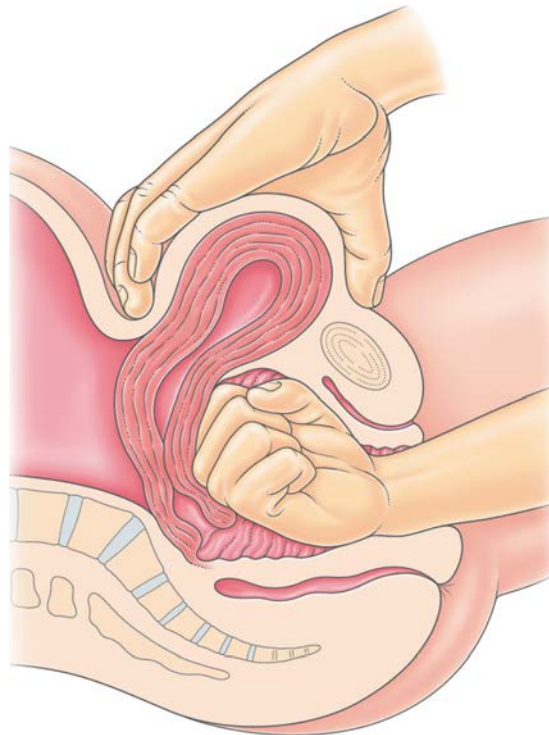
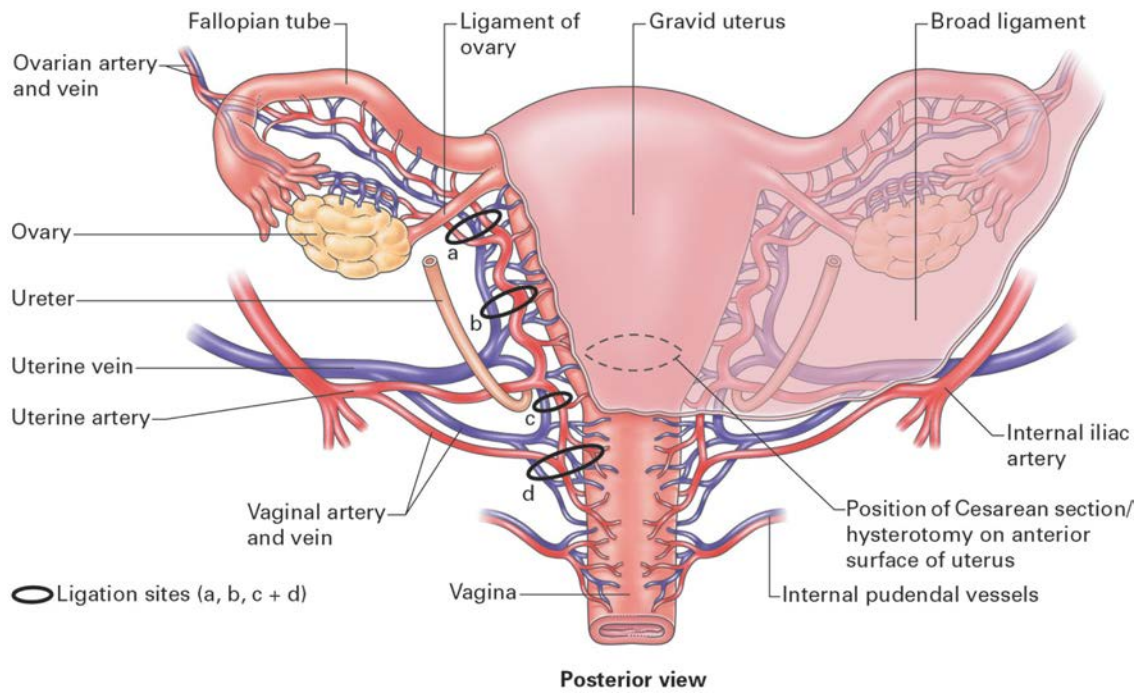


The Hayman uterine compression suture without opening the uterine cavity

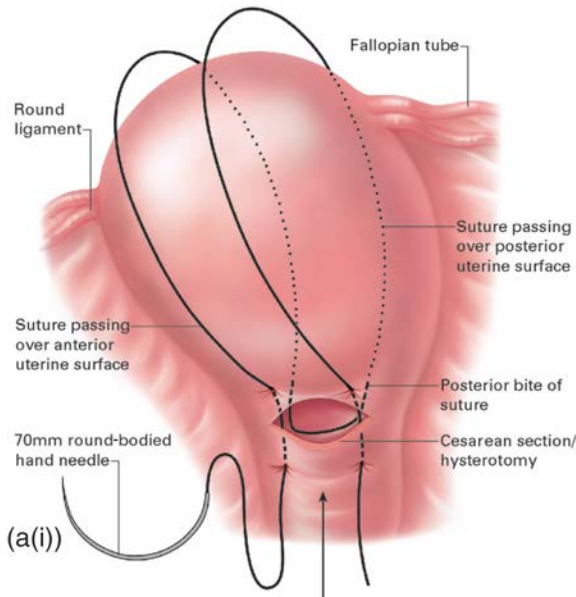


The Cho multiple square sutures compressing anterior to posterior uterine walls

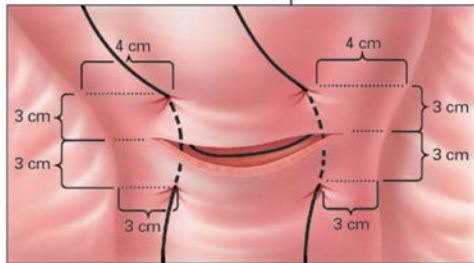
Placement of ligatures in the process of stepwise devascularization, including ligature of the descending uterine and vaginal arteries



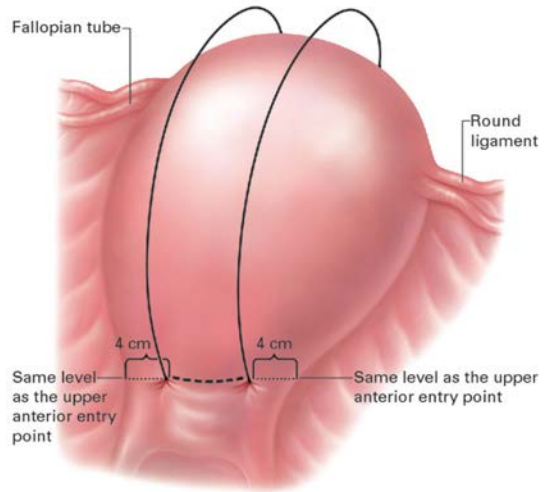
Bimanual compression of the uterus, illustrating the first-line approach to mechanical hemostasis. This in itself might control bleeding significantly by assisting the uterus to use its anatomical and physiological properties such as the cross-over interlinked network of myometrial fibers for vascular compression and bleeding control.



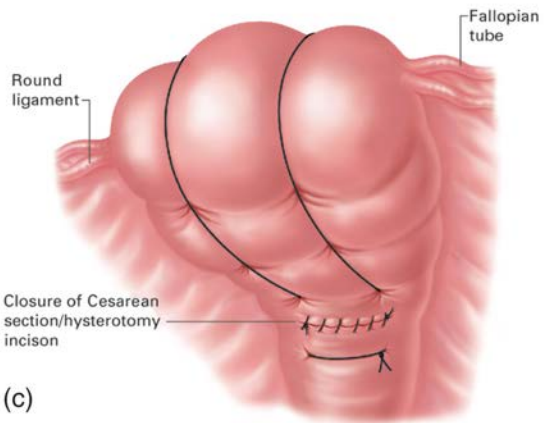
(a(i))



(a(ii))



(b)



(c)