

O.A. Hryhorieva
Yu.Yu. Abrosimov
V.V. Chorny

Zaporizhzhia State Medical University,
Zaporizhzhia, Ukraine

Надійшла: 23.08.2021

Прийнята: 15.09.2021

DOI: <https://doi.org/10.26641/1997-9665.2021.3.57-61>

UDC 616.718.5-001.5-089.2:616.71-007.234]-092.8

CARBON-CARBON COMPOSITE NAIL FOR INTRAMEDULLARY OSTEOSYNTHESIS IN RATS WITH EXPERIMENTAL OSTEOPOROSIS

Hryhorieva O.A. , Abrosimov Yu.Yu.  ✉, Chorny V.V.  Carbon-carbon composite nail for intramedullary osteosynthesis in rats with experimental osteoporosis.

Zaporizhzhia State Medical University, Zaporizhzhia, Ukraine

ABSTRACT. Background. In Ukraine, there has recently been an increase in the number of limb bone fractures among the population, in particular, due to increase in the number of elderly people, which is associated with the development of age-related osteoporosis and fragility of bones. Therefore, the use of artificial implants in traumatology is becoming increasingly important. The search for new bioinert and biodegradable materials, that are capable of providing rapid fracture consolidation and do not require repeated surgical intervention, continues. **Objective.** To elaborate a model for the research of using carbon-carbon composite nail for intramedullary osteosynthesis in laboratory rats with fractures of femur and tibia in norm and with experimental osteoporosis. **Methods.** The work investigated the lower limbs of 6 groups of Wistar rats. The first part of the study involved 4 groups of rats with modeled tibial fracture with subsequent osteosynthesis in norm and with experimental osteoporosis. The second part of the research included two groups of laboratory rats with modeled femur fracture. In both parts we used metal injection needle, as well as carbon-carbon composite nail for osteosynthesis. **Results.** All animals underwent surgery well, stepped on the injured limb. X-ray examination after the osteosynthesis demonstrated satisfactory reposition of the fragments. One month after modeled fracture in rats with experimental osteoporosis a violation of the normal consolidation of the fracture was observed, especially in the group where carbon-carbon composite nails were used for osteosynthesis. Further, until the 180th day after the surgery there were no peculiarities, function of the limbs was restored, mainly without expressed angular deformities. **Conclusion.** The above mentioned model was successfully elaborated for the research of using carbon-carbon composite nail for intramedullary osteosynthesis in laboratory rats with fractures of femur and tibia in norm and with experimental osteoporosis.


Key words: rat, tibia, femur, fracture, osteoporosis, osteosynthesis, carbon-carbon composite nail.


Citation:

Hryhorieva OA, Abrosimov YuYu, Chorny VV. Carbon-carbon composite nail for intramedullary osteosynthesis in rats with experimental osteoporosis. *Morphologia*. 2021;15(3):57-61.

DOI: <https://doi.org/10.26641/1997-9665.2021.3.57-61>

 Hryhorieva O.A. 0000-0002-6101-8322

 Abrosimov Yu. Yu. 0000-0001-5581-0463

 Chorny V.V. 0000-0003-0902-7616

✉ abrosimov1387@gmail.com

© Dnipro State Medical University, «Morphologia»

Background

In Ukraine, there has recently been an increase in the number of limb bone fractures among the population, in particular, due to increase in the number of elderly people, which is associated with the development of age-related osteoporosis and fragility of bones. Osteoporosis causes 0.3 million femoral fractures per year in the United States and 1.7 million femoral fractures in Europe. In Ukraine, osteoporosis affects more than 2.5 million women and 900 thousand men, with an annual increase in inci-

dence by 5% [1, 2].

Therefore, the use of artificial implants in traumatology is becoming increasingly important. The search for new bioinert and biodegradable materials, that are capable of providing rapid fracture consolidation and do not require repeated surgical intervention, continues. One of the directions of scientific research in improving the results of osteosynthesis may be the search for new materials that will have more similar mechanical characteristics compared to bone and can be used in osteosynthesis.

For many years, stainless steel, cobalt-chromium and titanium alloys have been the main materials used to make various implants in traumatology [3; 4].

It is known that standard surgical alloys, such as stainless steel, cobalt and chromium alloys, are susceptible to corrosion, the products of which cause local inflammation [5; 6]. Issues of connective tissue reactivity in this context remain insufficiently studied and require comprehensive study [7].

Recently, carbon composite porous materials have been studied, in which due to the physicochemical properties of the pores and irregularities of the material are filled with bone tissue, providing implants with biological fixation with the formation of a strong bone-carbon block, which promotes rapid and reliable consolidation. [8]

Carbon composite materials and carbon polymers are new materials in medical practice. They are successfully used in reconstructive surgery, dentistry, traumatology and orthopedics. The use of implants made of carbon-carbon composite materials (CCCM) can solve not only the problem of osteosynthesis of any location and length bone diaphysis, but also provide a reliable long-term mechanical connection of bone fragments of metaphyseal parts.

Purpose

To elaborate a model for the research of using carbon-carbon composite nail for intramedullary osteosynthesis in laboratory rats with fractures of femur and tibia in norm and with experimental osteoporosis.

Materials and methods

The work investigated the lower limbs of 6 groups of Wistar rats, weighing 170-230 g (10-12 weeks at the beginning of the experiment), which were pre-acclimatized for 14 days. The first part of the study involved 4 groups of Wistar rats with modeled tibial fracture with subsequent osteosynthesis in norm and with experimental osteoporosis. The second part of the research included two groups of laboratory rats with modeled femur fracture. Based on the literature data [9, 10], we have chosen the optimal model.

The first experimental group consisted of 15 animals. In order to create the experimental osteoporosis, animals of this group were injected intraperitoneally during 14 days with oil solution of retinol acetate (34.4 mg / ml) at a dosage of 70 mg / kg. Subsequently, the rats underwent modeling of a fracture of the left tibia. For this, after anesthesia and treatment of the operating field, approach was performed along the anteromedial surface of the left leg. Using Liston bone cutting forceps, a fracture of the left tibia was performed at the level of the proximal metaphysis, followed by intramedullary osteosynthesis using a metal injection needle (0.7 mm thick). The wound was sutured in layers.

The second group consisted of 15 rats. Animals of the control group underwent a similar operation -

modeling a fracture of the left tibia with intramedullary osteosynthesis using a metal injection needle (0.7 mm thick), without preliminary osteoporosis modeling.

The third experimental group consisted of 15 animals. In order to create the experimental osteoporosis, animals of this group were injected intraperitoneally during 14 days with oil solution of retinol acetate (34.4 mg / ml) at a dosage of 70 mg / kg. Subsequently, the rats underwent modeling of a fracture of the left tibia. For this, after anesthesia and treatment of the operating field, approach was performed along the anteromedial surface of the left leg. Using Liston bone cutting forceps, a fracture of the left tibia was performed at the level of the proximal metaphysis, followed by intramedullary osteosynthesis using a carbon-carbon composite nail (1.0 mm thick). The wound was sutured in layers.

The fourth group consisted of 15 rats. Animals of the control group underwent a similar operation - modeling a fracture of the left tibia with intramedullary osteosynthesis using a carbon-carbon composite nail (1.0 mm thick), without preliminary osteoporosis modeling.

The fifth group (18 rats) underwent modeling of a fracture of the left femur. For this, after anesthesia and treatment of the operating field, approach was performed along the anteromedial surface of the left thigh. Using Liston bone cutting forceps, a fracture of the left tibia was performed at the level of the diaphysis, followed by intramedullary osteosynthesis using a carbon-carbon composite nail (1.2 mm thick). The wound was sutured in layers.

The sixth group (18 rats) also underwent modeling of a fracture of the left femur, followed by intramedullary osteosynthesis using a metal injection needle (0.7 mm thick).

Throughout the experiment, the animals were under daily supervision; appetite, weight of animals, condition of fur and mucous membranes, behavior were noted. Every group was divided into three equal parts (5-6 animals), then 30, 180 and 360 days after the operation, laboratory animals were taken out from the experiment for the further study of the fracture site. X-ray examination was performed after surgery and before withdrawal from the experiment

When working with animals we were guided by «European Convention for the Protection of Vertebrate Animals used for Experimental and Other Scientific Purposes» (Strasbourg, 18.03.86) and Law of Ukraine «On the protection of animals against cruel treatment» (№ 3447-IV).

Results and discussion

All animals underwent surgery well, stepped on the injured limb. X-ray examination after the osteosynthesis demonstrated satisfactory reposition of the fragments (Fig. 1, Fig.2).

One month after modeled fracture in rats with experimental osteoporosis a violation of the normal consolidation of the fracture was noted, especially in

the group where carbon-carbon composite nails were used for osteosynthesis (Fig. 3). We associate this with intraoperative longitudinal bone split, which we observed in some cases in rats with experimental osteoporosis.

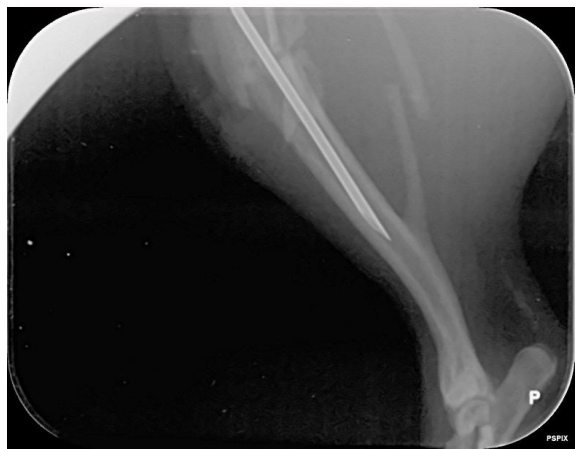


Fig. 1. X-ray of the tibial fracture after osteosynthesis using metal injection needle, the 1st day, group without osteoporosis.

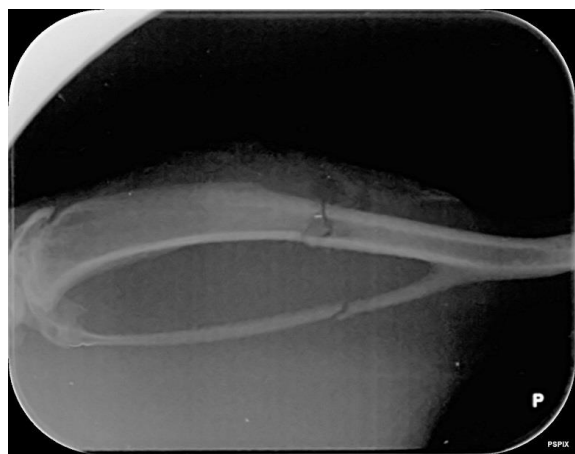


Fig. 2. X-ray of the tibial fracture after osteosynthesis using carbon-carbon composite nail, the 1st day, group with osteoporosis.

Further, until the 180th day after the surgery there were no peculiarities, function of the limbs was restored, mainly without expressed angular deformities (Fig. 4).

Conclusion

The above mentioned model was successfully elaborated for the research of using carbon-carbon composite nail for intramedullary osteosynthesis in laboratory rats with fractures of femur and tibia in

norm and with experimental osteoporosis.

Prospects for further research

Next step of the research will include histological, histochemical, immunohistochemical study of the fracture site in all groups of laboratory animals.

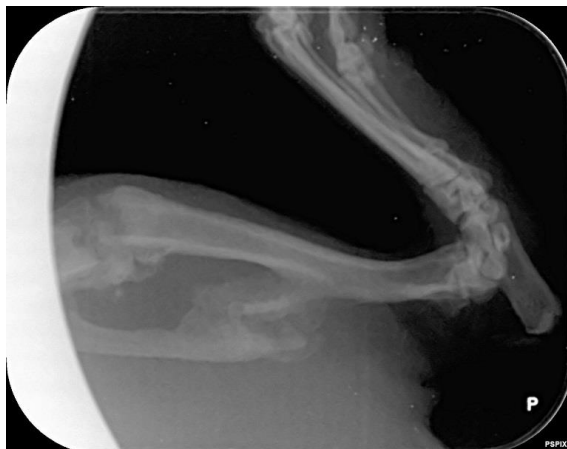


Fig. 3. X-ray of the tibial fracture after osteosynthesis using carbon-carbon composite nail, the 30th day, group with osteoporosis.

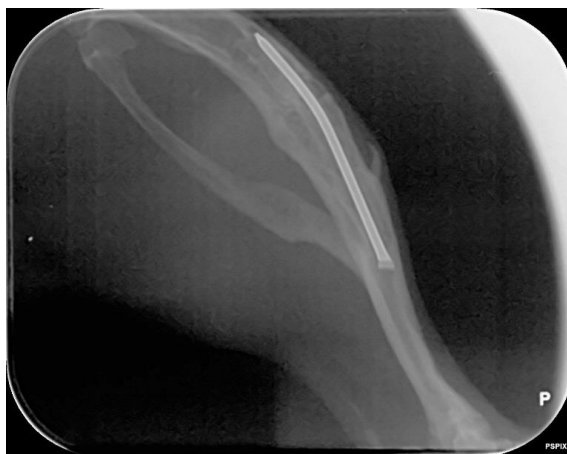


Fig. 4. X-ray of the tibial fracture after osteosynthesis using metal injection needle, the 180th day, group with osteoporosis.

Funding sources

The study is a part of the research project “Morphological features of bone remodeling under conditions of their polysegmental damage and surgical correction” (state registration 0120U103164).

Conflicts of interest

Authors have no conflict of interest to declare.

References

1. Zavorodnii AS. [Complex treatment of patients with compression fractures of vertebral bodies on the background of systemic osteoporosis]. In: [Medicine of the third millennium: a collection of

abstracts of the interuniversity conference of young scientists and students; 2017 January 16-17; Kharkiv]. Kharkiv: KNMU; 2017. p. 179-180. Ukrainian.

2. Rosen CJ. Pathogenesis of osteoporosis. *Best Practice & Research Clinical Endocrinology & Metabolism*. 2000;14(2):181-93.

3. Golovakha ML, Chornyi VN, Yatsun EV, Tertyshnyi SI, Dikii KL. [Bone tissue regeneration during osteosynthesis with implants made of magnesium-based alloys in experiment]. *Orthopedics, traumatology and prosthetics*. 2013;2:45-50. Russian.

4. Radchenko VA, Dedukh NV, Malyshkina S, Bengus LM. [Bioresorbable polymers in orthopedics and traumatology]. *Orthopedics, traumatology and prosthetics*. 2006;3:116-124. Russian.

5. Pohorielov MV. [Mineral metabolism of injured bone in norm and in violation of water-salt balance]. *Morphologia*. 2009;3(3):90-94. Ukrainian.

6. Daniels AU, Chang MK, Kirk PA. Mechanical properties of biodegradable polymers and composites proposed for internal fixation of bone. *J. Appl. Biomat*. 2004;1(1):57-78.

7. Hryhorieva OA, Pivtorak VI, Popovych YI, Abrosimov YY, Tavrog ML. Peculiarities of synovocytes and chondrocytes proliferative activity in rats with experimental model of undifferentiated dysplasia of connective tissue. *World of Medicine and Biology*. 2021;17(76):198-202. DOI:10.26724/2079-8334-2021-2-76-198-202.

8. Maslennikov SO, Golovakha ML, Chornyi VN. [Study of the degree of integration of soft tissues into elements made of carbon-carbon composite material in the zone of transition of the internal and external environment during implantation of endo-exoprostheses]. *Trauma*. 2017;18(1):39-44. Russian.

9. Sigurdson UE, Reikeras O, Utvag SE. External fixation compared to intramedullary nailing of tibial fractures in the rat. *Acta Orthop*. 2009;80(3):375-379.

DOI:10.3109/17453670903035567

10. Yuce HB, Toker H, Ozdemir H, Goze F. Effects of two experimental models of osteoporosis on alveolar bone: histopathologic and densitometric study. *Oral Health Dent Manag*. 2014;13(4):915-920.

Григор'єва Е.А., Абросімов Ю.Ю., Чорний В.В. Вуглець-вуглецевий композитний стрижень для інтрамедулярного остеосинтезу у щурів з експериментальним остеопорозом.

РЕФЕРАТ. Актуальність. В Україні протягом останнього часу спостерігається зростання кількості переломів кісток кінцівок серед населення, зокрема, через збільшення чисельності осіб похилого віку, що пов'язано із розвитком вікового остеопорозу та ламкості кісток. Тому застосування штучних імплантатів в травматології набуває все більшої актуальності. Продовжується пошук нових біоінертних та біорозкладаних матеріалів, які здатні забезпечити швидку консолідацію переломів та не потребують повторного оперативного втручання. **Мета.** Розробити модель для дослідження використання вуглець-вуглецевого композитного стрижня для інтрамедулярного остеосинтезу у лабораторних щурів з переломами стегна і голілки в нормі і з експериментальним остеопорозом. **Методи.** В роботі досліджували нижні кінцівки 6 груп щурів лінії Вістар. У першій частині дослідження брали участь 4 групи щурів з модельованим переломом великогомілкової кістки з подальшим остеосинтезом в нормі та з експериментальним остеопорозом. Друга частина дослідження включала дві групи лабораторних щурів з модельованим переломом стегнової кістки. В обох частинах використовувалася металева ін'єкційна голка, а також стрижень з вуглець-вуглецевого композиту для остеосинтезу. **Результати.** Всі тварини добре перенесли операцію, ступали на травмовану кінцівку. Рентгенологічне дослідження після остеосинтезу показало задовільну репозицію уламків. Через місяць після моделювання перелому у щурів з експериментальним остеопорозом спостерігалось порушення нормальної консолідації перелому, особливо в групі, де для остеосинтезу використовувалися стрижні з вуглець-вуглецевого композиту. Надалі до 180-го дня після операції ніяких особливостей не відзначалося, функція кінцівок відновилася, в основному, без виражених кутових деформацій. **Висновки.** Вищезазначена модель була успішно розроблена для дослідження використання вуглець-вуглецевого композитного стрижня для інтрамедулярного остеосинтезу у лабораторних щурів з переломами стегнової і великогомілкової кістки в нормі та з експериментальним остеопорозом.

Ключові слова: щур, великогомілкова кістка, стегнова кістка, перелом, остеопороз, остеосинтез, стрижень з вуглець-вуглецевого композитного матеріалу (ВВКМ).

Григорьева Е.А., Абросимов Ю.Ю., Черный В.В. Углерод-углеродный композитный стержень для интрамедулярного остеосинтеза у крыс с экспериментальным остеопорозом.

РЕФЕРАТ. Актуальность. В Украине в последнее время наблюдается рост числа переломов костей конечностей среди населения, в частности, из-за роста числа пожилых людей, что связано с развитием возрастного остеопороза и ломкости костей. Поэтому использование искусственных имплантатов в травматологии становится все более актуальным. Продолжаются поиски новых биоинертных и биоразла-

гаемых материалов, способных обеспечить быстрое сращение переломов и не требующих повторного хирургического вмешательства. **Цель.** Разработать модель для исследования использования углерод-углеродного композитного стержня для интрамедуллярного остеосинтеза у лабораторных крыс с переломами бедра и голени в норме и с экспериментальным остеопорозом. **Методы.** В работе исследовали нижние конечности 6 групп крыс линии Вистар. В первой части исследования участвовали 4 группы крыс с моделированным переломом большеберцовой кости с последующим остеосинтезом в норме и с экспериментальным остеопорозом. Вторая часть исследования включала две группы лабораторных крыс с моделированным переломом бедренной кости. В обеих частях использовалась металлическая инъекционная игла, а также стержень из углеродно-углеродного композита для остеосинтеза. **Результаты.** Все животные хорошо перенесли операцию, ступали на травмированную конечность. Рентгенологическое исследование после остеосинтеза показало удовлетворительную репозицию отломков. Через месяц после моделирования перелома у крыс с экспериментальным остеопорозом наблюдалось нарушение нормальной консолидации перелома, особенно в группе, где для остеосинтеза использовались стержни из углерод-углеродного композита. В дальнейшем до 180-го дня после операции никаких особенностей не отмечалось, функция конечностей восстановилась, в основном, без выраженных угловых деформаций. **Выводы.** Вышеупомянутая модель была успешно разработана для исследования использования углерод-углеродного композитного стержня для интрамедуллярного остеосинтеза у лабораторных крыс с переломами бедренной и большеберцовой кости в норме и с экспериментальным остеопорозом.

Ключевые слова: крыса, большеберцовая кость, бедренная кость, перелом, остеопороз, остеосинтез, стержень из углеродно-углеродного композитного материала (УУКМ).