

DOI: 10.21802/artm.2022.1.21.103

UDC 616.831:577.217]:616.36-008.64]-092.9-091.8-074/078

## IMMUNOHISTOCHEMICAL STUDY OF THE BRAIN AQUAPORIN-4 IN THE RAT ACUTE LIVER FAILURE MODEL

T.V. Shulyatnikova, V.O. Tumanskiy

Zaporizhzhia State Medical University,  
Department of Pathological Anatomy and Forensic Medicine, Zaporizhzhia, Ukraine,  
ORCID ID: 0000-0002-0196-9935,  
ORCID ID: 0000-0001-8267-2350,  
e-mail: shulyatnikova.tv@gmail.com

**Abstract.** Acute liver failure as well as acute-on-chronic liver failure result in the development of acute hepatic encephalopathy (HE) characterized by the major pathophysiologic event in form of the brain edema formation. Among brain cells, astrocytes are considered to be a central cellular population most sensitive to ammonia exposure in HE being the primarily cellular source of glutamine synthetase for ammonia metabolism. Astrocyte swelling is considered to be a principal sign of acute HE, while the exact molecular mechanisms of this event are still not fully understood. According to current concepts on HE, alteration in AQP4 regulation can play one of the central roles in the brain edema development and progression in hyperammonemia states. Considering high region- and context-specific heterogeneity of astroglial populations in the CNS, AQP4 involvement in the links of HE can also sustain mentioned conventional diversity.

**The aim of the study:** to determine the immunohistochemical level of the brain aquaporin 4 (AQP4) expression in the experimental acute liver failure in rats.

**Materials and methods.** The study was conducted in Wistar rats: 5 sham (control) animals and 10 rats with acetaminophen induced liver failure model (AILF). The immunohistochemical study of AQP4 expression was carried out in the sensorimotor cortex, white matter, hippocampus, thalamus and caudate nucleus/putamen regions between 12 and 24 h after acetaminophen treatment.

**Results.** Starting from the 6<sup>th</sup> hour after acetaminophen treatment all AILF-animals showed the progressive impairment of clinical signs of acute liver failure, evidenced histologically by spread liver centrilobular necrosis and finished in 6 rats by comatose state up to 24 h (constituted subgroup AILF-B, “non-survived”). 4 animals survived until the 24 h - subgroup AILF-A, “survived”. In the AILF-B group, starting from 16 to 24 hours after acetaminophen treatment, a significant (relative to control) regionally-specific dynamic increase AQP4 levels was observed in the brain: in the cortex – by 405.17 %, hippocampus – by 387.38%, caudate nucleus/putamen – by 314.11%; from 12<sup>th</sup> hour: in the thalamus – by 342.66% and subcortical white matter – by 297.77%; with the highest elevation of AQP4 expression in the cortex among other studied regions: by 5.05 times.

**Conclusions.** AILF in rats induces dynamic increase in AQP4 levels in the cortex, hippocampus and caudate nucleus/putamen by 12<sup>th</sup> hours and in the white matter and thalamus – by 16<sup>th</sup> h after the acetaminophen overdosing with the highest elevation in the cortical region. The heterogeneity in the degree of AQP4 elevation among different brain regions potentially may indicate brain territories more susceptible for systemic toxic exposure and damage in acute liver failure. Furthermore, the earliest reliable increase of AQP4 levels in the cortex, hippocampus and caudate/putamen might propose the faster reactivity of the local astroglial populations in response to the hyperammonemia among other regions. Consequently, the later and lower rates of AQP4 elevation in the white matter might indicate local astroglia as less reactive and/or more protected from the harmful exposure at a certain time period of the experiment. The higher cortical levels of AQP4 in the non-survived animals compared to survived ones reflect the significance of AQP4-involving mechanisms in the aggravation of acute HE, as well as the role of AQP4 alterations in thanatogenesis in the conditions of acute liver failure.

**Keywords:** acute hepatic encephalopathy, astroglial reactivity, AQP4.

**Introduction.** Hepatic encephalopathy (HE) was defined as a neuropsychiatric syndrome caused by liver pathologies and manifesting by symptoms ranging from sub-clinical neurological or psychiatric alterations to hepatic coma finished by brain herniation and death [1]. Acute liver failure (ALF) as well as acute-on-chronic liver failure (ACLF) result in acute hepatic encephalopathy (AHE) characterized by the major pathophysiologic event in form of the brain edema formation [2]. Thus, Liotta E.M. and colleagues using analysis of computed tomography scans have confirmed brain edema development in both ALF and ACLF patients corresponded to AHE severity measured by

the Glasgow Coma Scale [3]. Besides series of the recent mentioned human studies by Liotta's and other teams, there is growing body evidence obtained from animal and culture studies that edema formation in AHE is based on a very complicated mechanism including links of: (i) «hyperosmotic hypothesis», (ii) «the Trojan Horse hypothesis» involving the mitochondrial permeability transition (MPT) pore opening, (iii) influence of oxidative and nitrosative stress, (iv) systemic infection/inflammation-neuroinflammation, (v) increase of brain lactate and energy failure, (vi) impairment of blood-brain barrier (BBB) and glymphatic functions, and finally (vii) ion and water

channels dysfunction [4, 5, 2]. All listed constituents seem to be closely interrelated and triggered by similar settings. Among brain cells, astrocytes are considered to be a central cellular population the most sensitive to ammonia exposure in HE conditions being the primarily cellular source of glutamine synthetase for ammonia metabolism [6]. Astrocyte swelling is considered to be a principal feature of AHE brain, while the exact molecular mechanisms of this event are still not fully understood [7]. Aquaporin-4 (AQP4) is one of the central astrocyte specific proteins mostly responsible for a water homeostasis and cell volume in healthy and diseased brain [8]. Among 8 types of aquaporins expressed in the central nervous system (CNS), AQP4 presents the most abundant water channel [9]. The highest concentrations of AQP4 were detected in the end foot membranes of astrocytic processes along the BBB, brain-CSF meningeal barrier, blood-cerebrospinal fluid (CSF) barrier (BCSFB), and CSF-brain ventricular barrier, including regions for osmoregulation of water balance (subfornical organ and supraoptic nucleus) [8]. According to current concepts on HE pathophysiology evidenced by animal studies demonstrating increased AQP4 expression in AHE and hyperammonemia states [10], alteration in AQP4 regulation can play one of the central roles in the brain edema development and progression in mentioned conditions. Considering high region- and context-specific morpho-functional heterogeneity of astroglial populations in the CNS, AQP4 involvement in the links of HE mechanisms can also sustain mentioned conventional diversity. Accordingly, determining the region-specific features of AQP4 reactivity in the condition of ALF might shed the light on some gaps in the knowledge on AHE mechanisms. Thus, the purpose of the present study is determining the immunohistochemical level of AQP4 expression in different brain regions in the conditions of rat experimental acute liver failure.

**Materials and methods.** The experiment was performed on Wistar rats of 200-300 g body weight. All procedures were conducted according to the European convention for the protection of vertebrate animals (Strasbourg, 18 March 1986; ETS No. 123) and the Directive 2010/63/EU. For induction of AHE type “A” (“Acute liver failure” – according to the American Association for the Study of Liver Disease updated guidelines), we used acetaminophen (paracetamol, N-acetyl-p-aminophenol [APAP]) induced liver failure (AILF) model [11]. The detailed characteristics of all steps of the model were described in our recent paper [12]. Paracetamol overdosing leads to ALF development both in humans and rodents; therefore, noted model can be used for studying the links of AHE similar to those occur in human pathology [11]. Rats were distributed into control (n = 5) and AILF-group (n = 10). In the AILF-group, after intraperitoneal (i.p.) acetaminophen injection, animals were examined for signs of altered major physiological parameters. Six rats were euthanized up to 24 h after the treatment by an i.p. administration of sodium thiopental overdosing due to the severe clinical symptoms of ALF up to coma – they constituted group “AILF-B” – decompensated AILF (non-survived). Rats that showed

compensated clinical signs (n = 4) and survived up to 24 h after treatment were designated to group “AILF-A” – compensated AILF. In control “AILF-C” group, all animals survived up to 24 hours. All survived and control animals were euthanized at 24 h. The brain and liver samples were processed according to standard procedures with formation of paraffin blocks. For general histopathological observations hematoxylin-eosin stained sections were used. Immunohistochemical (IHC) study included conventional steps of tissue processing protocols followed by detection of immunopositive labels using rabbit polyclonal anti-AQP4 primary antibody (Thermo Scientific, USA) and Ultra Vision Quanto Detection imaging system with diaminobenzidine (Thermo Scientific Inc., USA). The results of IHC were assessed at x200 in a standardized field of view (SFV) of the microscope Scope. A1 “Carl Zeiss” (Germany) using Jenoptik Progres Gryphax 60N-C1"1,0x426114 (Germany) camera and the program Videotest-Morphology 5.2.0.158 (Video Test LLC, RF). The expression of AQP4 was assessed as a percentage of the relative area (S rel., %) of labels<sup>+</sup> to the total area of the tissue section in the SFV. For the comparative analysis of the AQP4 expression were collected sensorimotor cortex, subcortical white matter, and hippocampus, thalamus and caudate nucleus/putamen regions. Five SFVs of each region were examined for 1 animal. Digital data were statistically processed by Statistica® for Windows 13.0 (StatSoft Inc., license № JPZ804I382130ARCN10-J) with evaluating median (Me), lower and upper quartiles (Q1; Q3). For comparison between groups Mann-Whitney and Kruskal-Wallis tests were used. The results were considered significant at 95 % (p < 0.05).

**Results.** Control brains demonstrated heterogeneous staining on AQP4 among different 5 regions with the highest level in the sensorimotor cortex – 2.32 (2.12; 3.45) % and the lowest in the subcortical white matter – 0.45 (0.25; 1.06) % (Table 1). AQP4<sup>+</sup> labeling in all brain regions of control cases was related to astroglial endfeet processes both vascular and, in lesser extent, parenchymal ones (fig. 1).

During 6<sup>th</sup> h after acetaminophen treatment all animals began to show dynamic impairment of clinical signs of acute liver failure and aggravation of brain disfunction resulted in comatose state up to 24 h in 6 animals. Pathohistological study of the liver samples of all AILF-rats have evidenced foci of centrilobular necrosis, local hemorrhages and balloon dystrophy of hepatocytes, all characterized by dynamic aggravation over time after treatment.

Histological examination of ICH-stained sections of all studied brain regions of AILF-rats revealed substantive increase in AQP4 labeling, which was predominantly associated to astroglial end-feet processes ensheathing capillary blood vessels and in case of cortex, AQP4 also appeared abundant in glia limitans processes, however neuropil of all regions both demonstrated moderate-to-weak staining (fig. 2).

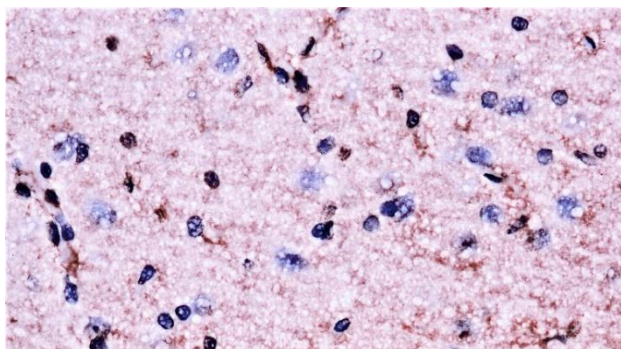
Table 1

Brain AQP4 expression in different experimental groups expressed in the percent of immune<sup>+</sup> labels in the SFV.

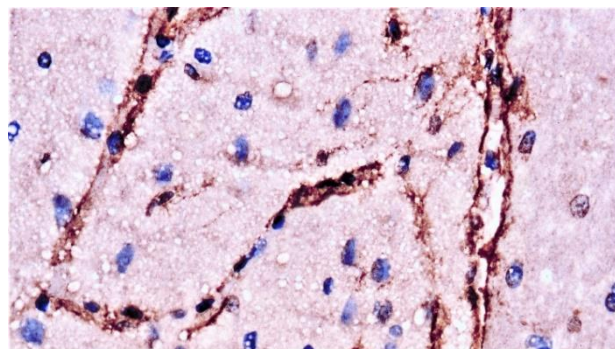
Data are presented as median (Me) and lower, upper quartiles (Q1; Q3)

Brain region	AILF-A	AILF-B	AILF-C
Cortex	9.46 (7.68; 9.72) *†	11.72 (10.11; 12.54) *†	2.32 (2.12; 3.45)
Subcortical white matter	1.53 (1.10; 1.85) *	1.79 (1.27; 1.92) *	0.45 (0.25; 1.06)
Hippocampus	10.21 (8.93; 10.54) *	10.43 (9.15; 10.87) *	2.14 (2.07; 3.23)
Thalamus	3.20 (2.89; 4.43) *	3.32 (3.10; 4.56) *	0.75 (0.43; 1.68)
Caudate/putamen	3.43 (2.91; 4.59) *	3.52 (3.25; 4.77) *	0.85 (0.36; 1.72)

**Notes:** Reliable differences in indicators compared to the control animals ( $p < 0.05$ ) are marked with an asterisk (\*). Reliable differences between AILF-A and AILF-B groups in the same brain region ( $p < 0.05$ ) are marked with the dagger (†); “AILF-A” – survived; “AILF-B” – non-survived; “AILF-C” – control.



**Fig. 1.** AQP4 expression in the cortex of the control rat (AILF-C group) 24 h after the sham procedure. (anti-AQP4, Thermo Scientific, USA). X400.



**Fig. 2.** AQP4 expression in the cortex of the non-survived rat (AILF-B group) 24 h after the AILF procedure. (anti-AQP4, Thermo Scientific, USA). X400.

In the survived and non-survived treated animals, the alteration of AQP4 expression was heterogeneous among different brain regions with the highest increase in the cortical region compared to control, respectively: 11.72 (10.11; 12.54) % and 2.32 (2.12; 3.45) %,  $p < 0.05$ , which was equal to 405.17 % or 5.05-fold increase if compare medians of indicators. Furthermore, AQP4 expression in the cortex appeared more substantive in AILF-B compared to AILF-A, respectively: 11.72 (10.11; 12.54) % and 9.46 (7.68; 9.72) %,  $p < 0.05$ , contrary to other regions which showed no statistical validity of differences between survived and non-survived groups ( $p > 0.05$ ) (Table 1).

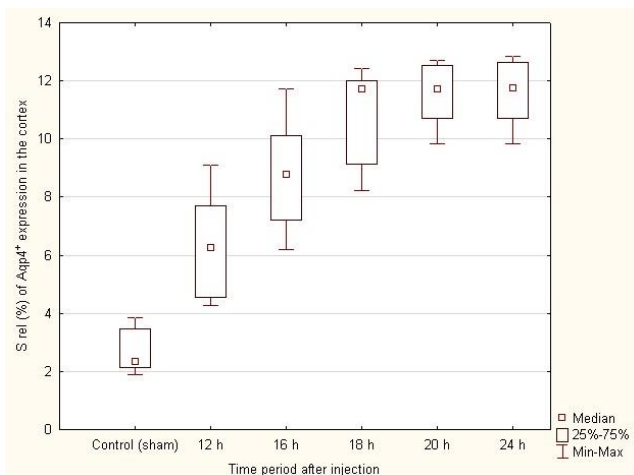
Hippocampus, thalamus and caudate nucleus/putamen of AILF-B group also displayed notable elevation of AQP4 staining, respectively: 10.43 (9.15; 10.87) % (4.87-fold or 387.38 % comparing medians to control values), 3.32 (3.10; 4.56) % (4.42-fold or 342.66 % increase), 3.52 (3.25; 4.77) % (4.14-fold or 314.11 % increase), ( $p < 0.05$ ) (Table 1).

The least significant but reliable comparing to control increase in AQP4 expression in AILF-B rats was detected in the subcortical white matter, respectively: 1.79 (1.27; 1.92) % vs. 0.45 (0.25; 1.06) % respectively, with an excess of 297.77 % or 3.97-fold increase (Table 1).

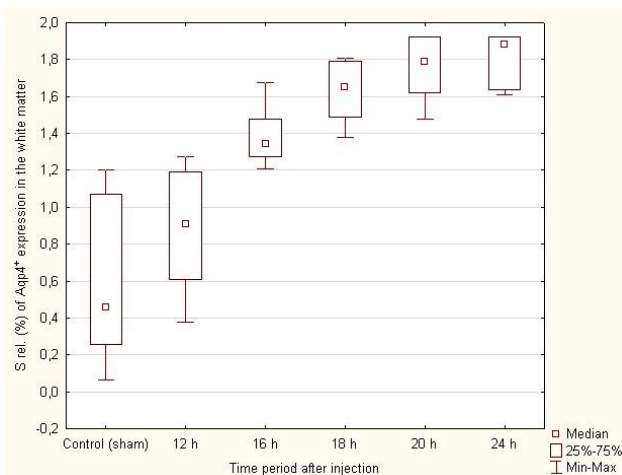
After AILF-procedure, non-survived animals displayed the growing dynamics in AQP4 expression in all 5 studied brain regions with the highest values 24 h after the injection. As early as 12 h, sacrificed animals of AILF-B group displayed reliable gain in AQP4 staining

compared to control in the cortex, hippocampus and caudate/putamen, whereas white matter and thalamic elevation reached statistical validity only by 16 h after acetaminophen administration (fig. 3-7).

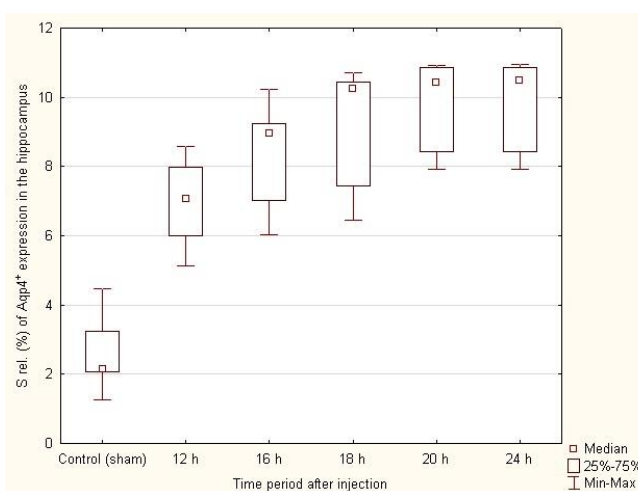
**Discussion.** Our present study partially confirms the results of the previous reports postulated that experimental ALF induced by thioacetamide and other hepatotoxins as well as hyperammonemia conditioned media, are characterized by enhanced AQP4 immunoreactivity in the plasma membranes of perivascular astrocytic end feet which correlates with the severity of the edematous changes [10]. Furthermore, silencing the AQP4 gene in cultured astrocytes and in AQP4-null mice prevented ammonia-induced astrocytes swelling, as well as remarkably decreased the neurological deficit in animal studies [13]. Interestingly, total tissue mRNA and AQP4 protein levels were not altered in ALF indicating that increased AQP4 is likely due to a more resistant anchoring of the protein to the astroglial perivascular endfeet plasma membranes which was confirmed by increased levels of co-localized  $\alpha$ -syntrophin adjacent to AQP4 [14]. The protein  $\alpha$ -syntrophin involved in AQP4 anchoring to the endfeet membranes was shown to be inhibited by L-histidine, an inhibitor of mitochondria glutamine transport, suggesting involvement of glutamine in the AQP4 plasma membrane rearrangement [14]. Postmortem IHC and mRNA studies of human cortex in ALF have also demonstrated substantive increase in Aqp-4 immunoreactivity in the astroglial vascular end-feet accompanied with loss of EAAT-2 and GFAP proteins in astrocytes [15].



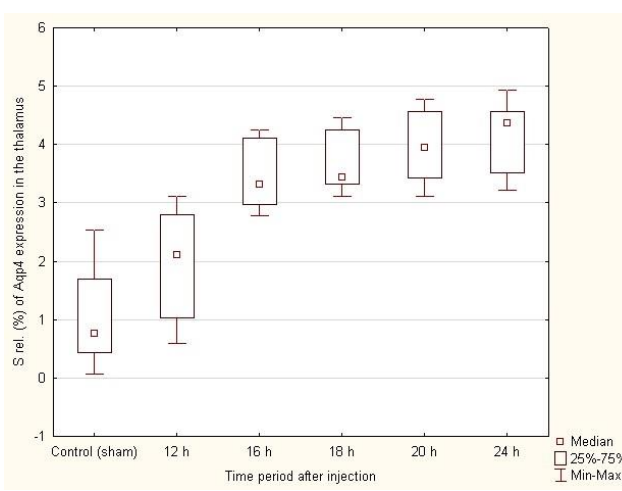
**Fig. 3. Dynamics of the AQP4 expression in the cerebral cortex of AILF-B rats after acetaminophen treatment.**



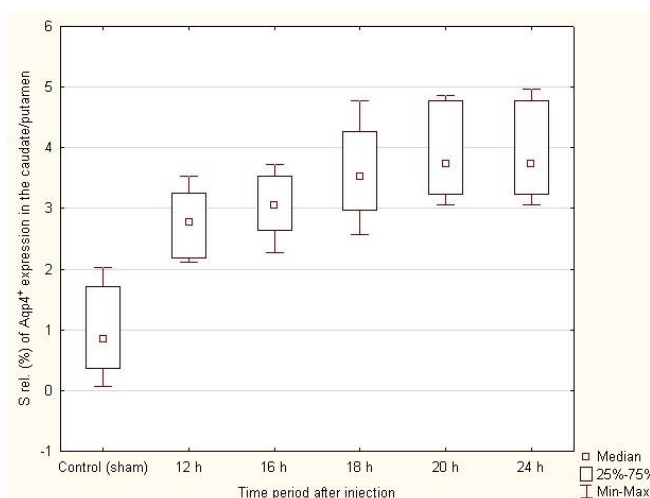
**Fig. 4. Dynamics of the AQP4 expression in the subcortical white matter of AILF-B rats after acetaminophen treatment.**



**Fig. 5. Dynamics of the AQP4 expression in the hippocampus of AILF-B rats after acetaminophen treatment.**



**Fig. 6. Dynamics of the AQP4 expression in the thalamus of AILF-B rats after acetaminophen treatment.**



**Fig. 7. Dynamics of the AQP4 expression in the caudate nucleus/putamen of AILF-B rats after acetaminophen treatment.**

AQP4 being a passive transmembrane channel, presents the main water channel in astrocytes which allows osmotic gradient water movement [16]. ALF is known to determine serum hyperosmolality which subsequently accompanied by increase in astrocytes AQP4 expression making cells in turn more susceptible to osmotic challenges [17]. In hyperammonemia conditions, upregulation of AQP4 in astrocytes is supposed to be conditioned by glutamine accumulation and excess uptake it by mitochondria («Trojan Horse» hypothesis) [4]. Furthermore, Aqp-4 is co-localized in the astrocyte membrane with potassium channels, including the inwardly rectifying potassium channel and the Na-K-2Cl cotransporter, which may be involved in the brain edema in ALF considering that ammonium ions can pass through potassium channels due to the similar ionic properties of two molecules [4]. From the other hand, Assentoft M. and colleagues in their recent study have proposed that AQP4 may belong to one of the ammonia-(NH<sub>3</sub>)-permeable water channels [18], which might suggest AQP4 direct contribution to increase

cellular ammonia levels and astrocyte swelling in hyperammonemic conditions.

Among other assumptions of AHE and chronic HE mechanisms involving AQP4 role, there is hypothesis of impaired glymphatic drainage in the conditions of systemic toxemia, including hyperammonemia, which may cause both retaining of deleterious molecules inside the brain parenchyma and lead to the violation of solute exchange between interstitial fluid and CSF [19]. AQP4, a central water channel supporting the functioning of the glymphatic system [2], being dysregulated might play a key role in the abnormal clearing from incoming toxic substances in the condition of ALF.

The present study evidenced that AILF-model provokes reliable increase in the AQP4 IHC levels in the sensorimotor cortex, hippocampus and caudate nucleus/putamen region by 12<sup>th</sup> h after acetaminophen treatment and by 16<sup>th</sup> h – in the white matter and thalamic regions. The obtained data are comparable with our previous study [20], where AILF model caused upregulation of glutamine synthetase (GS) in the same brain regions, however, in the cortical and hippocampal regions in later terms – by 16 h. The latter suggests that AQP4 alterations in mentioned regions could precede changes in the astrocytic glutamate-glutamine shuttle and means that AQP4 elevation can be reasoned by other factors than the glutamine hyperosmolarity. Nevertheless, increase in AQP4 and GS levels in the white matter and thalamus was found to be simultaneous indicating the potential overlapping regulatory mechanisms for these two proteins in the conditions of AHE.

An early and the highest rates of AQP4 elevation in the cortex might suppose this region as one of the most susceptible to deleterious factors entering the brain parenchyma in ALF, including putative ammonia load. Moreover, this fact might suggest more harmful influence of the incoming agents on this region and given brain edema as a key sign of the AHE, the highest AQP4 suggests the cortex as one of the principal territories for unfolding the critical events in these conditions. The earliest reliable increase of AQP4 levels in the cortex, hippocampus and caudate/putamen might propose the faster reactivity of the local astroglial populations in response to the hyperammonemia among other regions. Consequently, the later and lowest rates of AQP4 growth in the white matter might indicate local astroglia as less reactive and/or more protected from the harmful exposure. The higher cortical levels of AQP4 in the non-survived animals compared to survived ones reflect the significance of AQP4-involving mechanisms in the aggravation of AHE and thanatogenesis in the conditions of ALF.

**Conclusions.** AILF in rats induces dynamic increase in AQP4 levels in the cortex, hippocampus and caudate nucleus/putamen by 12<sup>th</sup> hours and in the white matter and thalamus – by 16<sup>th</sup> h after the acetaminophen treatment with the highest elevation in the cortex. The heterogeneity in the degree of AQP4 elevation among different brain regions potentially indicate brain territories more susceptible for systemic toxic influence in ALF as well as heterogeneous reactive response of local astroglia during specific time-period. The higher levels of AQP4 in the cortex of non-survived animals in the conditions of

ALF might reflect the importance of AQP4 alterations in the thanatogenetic mechanisms.

#### References:

1. Amodio P, Montagnese S. Lights and Shadows in Hepatic Encephalopathy Diagnosis. *J Clin Med.* 2021 Jan 18; 10(2):341. DOI: 10.3390/jcm10020341.
2. Shulyatnikova T, Shavrin V. Modern view on hepatic encephalopathy: basic terms and concepts of pathogenesis. *Pathologia.* 2017; 14(3):371-380. DOI: 10.14739/2310-1237.2017.3.118773
3. Liotta EM, Romanova AL, Lizza BD, Rasmussen-Torvik LJ, Kim M, Francis B, et al. Osmotic shifts, cerebral edema, and neurologic deterioration in severe hepatic encephalopathy. *Critical care medicine.* 2018 Feb; 46(2):280-289. DOI: 10.1097/CCM.0000000000002831
4. Liotta EM, Kimberly WT. Cerebral edema and liver disease: Classic perspectives and contemporary hypotheses on mechanism. *Neurosci Lett.* 2020 Mar 16; 721:134818. DOI: 10.1016/j.neulet.2020.134818.
5. Claeys W, Van Hoecke L, Lefere S, Geerts A, Verhelst X, Van Vlierberghe H, Degroote H, Devisscher L, Vandenbroucke RE, Van Steenkiste C. The neuroglivascular unit in hepatic encephalopathy. *JHEP Rep.* 2021 Aug 11; 3(5):100352. DOI: 10.1016/j.jhepr.2021.100352.
6. Jayakumar AR, Norenberg MD. Hyperammonemia in Hepatic Encephalopathy. *J Clin Exp Hepatol.* 2018 Sep; 8(3):272-280. DOI: 10.1016/j.jceh.2018.06.007.
7. Sepehrinezhad A, Zarifkar A, Namvar G, Shahbazi A, Williams R. Astrocyte swelling in hepatic encephalopathy: molecular perspective of cytotoxic edema. *Metab Brain Dis.* 2020 Apr; 35(4):559-578. DOI: 10.1007/s11011-020-00549-8.
8. Potokar M, Jorgačevski J, Zorec R. Astrocyte Aquaporin Dynamics in Health and Disease. *Int J Mol Sci.* 2016 Jul 13; 17(7):1121. DOI: 10.3390/ijms17071121.
9. Filippidis AS, Carozza RB, ReKate HL. Aquaporins in Brain Edema and Neuropathological Conditions. *Int J Mol Sci.* 2016 Dec 28; 18(1):55. DOI: 10.3390/ijms18010055.
10. Jaeger V, DeMorrow S, McMillin M. The Direct Contribution of Astrocytes and Microglia to the Pathogenesis of Hepatic Encephalopathy. *J Clin Transl Hepatol.* 2019 Dec 28; 7(4):352-361. DOI: 10.14218/JCTH.2019.00025.
11. Mossanen JC, Tacke F. Acetaminophen-induced acute liver injury in mice. *Lab Anim.* 2015 Apr; 49(1 Suppl):30-6. DOI: 10.1177/0023677215570992.
12. Shulyatnikova T, Shavrin V. Mobilisation and redistribution of multivesicular bodies to the endfeet of reactive astrocytes in acute endogenous toxic encephalopathies. *Brain Res.* 2021 Jan 15; 1751:147174. DOI: 10.1016/j.brainres.2020.147174.
13. Rama Rao KV, Verkman AS, Curtis KM, Norenberg MD. Aquaporin-4 deletion in mice reduces encephalopathy and brain edema in experimental acute liver failure. *Neurobiol Dis.* 2014 Mar; 63:222-8. DOI: 10.1016/j.nbd.2013.11.018.
14. Rama Rao KV, Jayakumar AR, Tong X, Curtis KM, Norenberg MD. Brain aquaporin-4 in experimental acute liver failure. *J Neuropathol Exp Neurol.* 2010

- Sep; 69(9):869-79. DOI: 10.1097/NEN.0b013e3181e581.
15. Thumburu KK, Dhiman RK, Vasishta RK, Chakraborti A, Butterworth RF, Beauchesne E, Desjardins P, Goyal S, Sharma N, Duseja A, Chawla Y. Expression of astrocytic genes coding for proteins implicated in neural excitation and brain edema is altered after acute liver failure. *J Neurochem.* 2014 Mar; 128(5):617-27. DOI: 10.1111/jnc.12511.
  16. Stokum JA, Kurland DB, Gerzanich V, Simard JM. Mechanisms of astrocyte-mediated cerebral edema. *Neurochem Res.* 2015 Feb; 40(2):317-28. DOI: 10.1007/s11064-014-1374-3.
  17. Liotta EM, Karvellas CJ, Kim M, Batra A, Naidech A, Prabhakaran S, Sorond FA, Kimberly WT, Maas MB. Serum osmolality, cerebrospinal fluid specific gravity and overt hepatic encephalopathy severity in patients with liver failure. *Liver Int.* 2020 Aug; 40(8):1977-1986. DOI: 10.1111/liv.14400.
  18. Assentoft M, Kaptan S, Schneider HP, Deitmer JW, de Groot BL, MacAulay N. Aquaporin 4 as a NH3 Channel. *J Biol Chem.* 2016 Sep 2; 291(36):19184-95. DOI: 10.1074/jbc.M116.740217.
  19. Hadjihambi A, Harrison IF, Costas-Rodríguez M, Vanhaecke F, Arias N, Gallego-Durán R, Mastitskaya S, Hosford PS, Olde Damink SWM, Davies N, Habtesion A, Lythgoe MF, Gourine AV, Jalan R. Impaired brain glymphatic flow in experimental hepatic encephalopathy. *J Hepatol.* 2019 Jan; 70(1):40-49. DOI: 10.1016/j.jhep.2018.08.021.
  20. Shulyatnikova T, Tumanskiy V. Glutamine synthetase expression in the brain during experimental acute liver failure (immunohistochemical study). *J Educ Health Sport.* 2021 Oct; 11(10):342-356. DOI: 10.12775/JEHS.2021.11.10.033.

УДК 616.831:577.217]:616.36-008.64]-092.9-091.8-074/078

#### ІМУНОГІСТОХІМІЧНЕ ДОСЛІДЖЕННЯ МОЗКОВОГО АКВАПОРИНУ-4 У МОДЕЛІ ГОСТРОЇ ПЕЧІНКОВОЇ НЕДОСТАТНОСТІ У ЩУРІВ

Т. В. Шулятнікова, В. О. Туманський

Запорізький державний медичний університет,  
кафедра патологічної анатомії і судової медицини,  
м. Запоріжжя, Україна,  
ORCID ID: 0000-0002-0196-9935,  
ORCID ID: 0000-0001-8267-2350,  
e-mail: shulyatnikova.tv@gmail.com

**Резюме.** Астроцитарний набряк вважається ключовою ознакою гострої печінкової енцефалопатії, проте точні молекулярні механізми цього явища вимагають подальшого вивчення.

**Мета.** Імуногістохімічне визначення рівня експресії мозкового аквапорину-4 (AQP4) при експериментальній гострій печінковій недостатності у щурів.

**Матеріали та методи.** Дослідження проведено на щурах лінії Вістар: 5 контрольних тварин та 10 щурів з моделлю гострої печінкової недостатності (ГПН), індукованої ацетамінофеном (AIF). Імуногістохімічне дослідження експресії AQP4 проводили у сенсомоторній корі, підкірковій білій речовині, гіпокампі, таламусі та хвостатому ядрі/скорлупі в період між 12 і 24 год після ін'єкції ацетамінофену.

**Результати.** У групі померлих щурів AIF-B з 16 до 24 год спостерігалось достовірне регіон-специфічне динамічне підвищення рівня AQP4: у корі – на 405.17%, гіпокампі – на 387.38%, хвостатому ядрі/скорлупі – на 314.11%; з 12 год: у таламусі – на 342.66% та підкірковій білій речовині – на 297.77%; з найбільшим підвищенням у корі серед інших областей: у 5.05 раза порівняно з контролем.

**Висновки.** AIF у щурів викликає динамічне підвищення рівня AQP4 у корі, гіпокампі та хвостатому ядрі/скорлупі до 12 год, а в білій речовині та таламусі – до 16 год після ін'єкції ацетамінофену з найбільшим підвищенням у корі. Неоднорідність підвищення AQP4 у різних відділах мозку потенційно вказує на області, більш сприйнятливі до системного токсичного впливу при ГПН, а також на неоднорідну реактивну відповідь локальної астроглії протягом певного періоду. Більш високі рівні AQP4 у корі тварин, що вижили, в умовах ГПН можуть відображати значущість змін AQP4 у танатогенетичних механізмах.

**Ключові слова:** гостра печінкова енцефалопатія, астрогліальна реактивність, AQP4.

Стаття надійшла в редакцію 12.01.2022 р.  
Стаття прийнята до друку 08.02.2022 р.