

MORPHOLOGICAL CHARACTERISTICS OF GUINEA PIGS BRONCHUS ASSOCIATED LYMPHOID TISSUE IN THE DYNAMICS OF EXPERIMENTAL OVALBUMIN-INDUCED ALLERGIC INFLAMMATION

©S. S. Popko

Zaporizhzhia State Medical University

SUMMARY. The actual problem of modern medicine is the reaction of Bronchus associated lymphoid tissue in airways chronic allergic diseases, because the full functioning of the respiratory system depends on the state of its local immune system.

The aim – to study morphological changes in Bronchus associated lymphoid tissue of guinea pigs in the dynamics of experimental ovalbumin-induced allergic inflammation.

Material and Methods. We have studied the lung of 48 guinea pigs, using histological and morphometric methods, under conditions of experimental ovalbumin-induced allergic inflammation. To assess the structural and functional rearrangement of pulmonary lymphoid nodules, their diameter and number were determined.

Results. We have shown that sensitization and allergization with ovalbumin leads to a significant structural and functional rearrangement of Bronchus associated lymphoid tissue of guinea pigs in the form of the elevation in their number and diameter. We found more pronounced morphological changes in the late period of development of allergic inflammation in peribronchial lymphoid nodules, confirmed by the maximum magnification factor – 2.6 ($p^{***}<0.001$) of the diameter of peribronchial lymphoid nodules in the 4th experimental group compared to the control.

Conclusions. Sensitization and inhalation with ovalbumin leads to structural reorganization of Bronchus associated lymphoid tissue of guinea pigs in the form of the elevation in their number and diameter, had the unidirectional staged character depending on localization of lymphoid nodules and the duration of the experiment and claimed proliferative changes in the cellular adaptive link of local lung immunity of guinea pigs in late period of allergic inflammatory process.

KEY WORDS: Bronchus associated lymphoid tissue; experimental allergic inflammation; ovalbumin; guinea pig.

Introduction. The organs of the immune system consist of lymphoid tissue, which is the "working" parenchyma of the organs of immunogenesis, can be diffuse and in the form of Mucosa associated lymphoid tissue and defends the constant state of the internal environment of the body throughout the life of the individual [1–3]. The cellular component of Bronchus associated lymphoid tissue is represented by immunocompetent cells: first of all, small lymphocytes, as well as plasma cells, included in the immune process, ensure the recognition and destruction of inhaled foreign substances carried signs of genetically foreign information by T- and B-lymphocytes, which function together and with the participation of macrophages provide immune response in the body [4–7]. Proceeding from the importance of Bronchus associated lymphoid tissue, there is a need for a detailed study of it in the dynamics of allergic inflammatory process, it is of current importance for the search for new methods of its correction.

The aim of this work is to study morphological changes in Bronchus associated lymphoid tissue of guinea pigs in the dynamics of experimental ovalbumin-induced allergic inflammation.

Materials and Methods. The object of the experimental study was lung, removed from 48 sexually mature male guinea pigs weighing 450-600 g, which were kept in standard conditions of Zaporizhzhia State Medical University vivarium. All ma-

nipulations were carried out in compliance with the basic principles of working with experimental animals in accordance with the provisions of the European Convention for the Protection of Vertebrate Animals used for Experimental and Other Scientific Purposes (Strasbourg, 1986), the General Ethical Principles for Animal Experiments adopted by the First National Congress on Bioethics (Kiev, 2001), the Law of Ukraine "On the protection of animals from cruelty" (from 21.02.2006).

Allergic airway inflammation induced by subcutaneous sensitization and followed challenging by intranasal inhalation with ovalbumin (OVA) (Sigma Aldrich, USA). Guinea pigs were actively sensitized by subcutaneous injections into the interscapular region of ovalbumin (0,5 mg/mL) with alum (10 mg/mL in saline) as an adjuvant (AlumVax Hydroxide vaccine adjuvant, OZ Biosciences France) on days 0, 7 and 14. From 21 to 28 days of the experiment, guinea pigs were challenged for 15 min with inhalation of either OVA (10 mg/mL in saline) via a nebulizer (Little Doctor International, Singapore, LD-211C) coupled to a plastic box. We divided animals into 6 groups (8 animals per group). The first four groups are animals sensitized and challenged OVA, withdrawn from the experiment, respectively, on the 23rd, 30th, 36th and 44th days after its start; 5 - control group, received injections and challenged with saline only; 6 – intact group. For the purpose of rational presenta-

Огляди літератури, **оригінальні дослідження**, погляд на проблему, випадок з практики, короткі повідомлення

tion of the obtained data and their interpretation, we conditionally distinguish the early (23rd, 30th days of the experiment) and late (36th and 44th days after the start of the experiment) periods of the development of allergic inflammatory process in lung. Histological sections were stained by hematoxylin-eosin, viewed and photographed by the compound binocular light microscope (Primo Star, Zeiss, Germany). To assess the structural and functional rearrangement of pulmonary lymphoid nodules, their diameter and number per 1 mm² of section were determined.

The research results were processed by modern statistical methods of analysis on a personal computer using the standard software package Microsoft Office 2010 (Microsoft Excel) and STATISTICA® for Windows 6.0 (StatSoft Inc., USA, license 46 No. AXXR712D833214FAN5). We use the Shapiro-Wilk test and the Kolmogorov-Smirnov test of consistency testing the hypothesis about the normal distribution of the studied parameters. We use the Kolmogorov – Smirnov homogeneity criterion testing the hypothesis that two independent samples be-

long to the same distribution law. The mean (M) and deviation of the mean ($\pm m$) were evaluated. The statistical significance of intergroup differences according to the data obtained was established using the parametric Student's t-test (p*) and the nonparametric U-Whitney-Mann test (p**). The obtained data were compared between the median and interquartile range Me (Q1; Q3). Differences between the compared values at the level of 95 % (p<0.05) considered statistically significant.

Results and Discussion. We have shown that the lymphoid nodules represented guinea pigs' Bronchus associated lymphoid tissue have an oval, round or triangular shape and diameter varied from 80 to 220 μ m, located in the wall of the bronchi of different caliber, perivascular or subpleural. Some lymphoid formations have a well-defined connective tissue capsule according to results of the histological analysis. Blood vessels and fibroblasts are found between lymphoid cells in the lymphoid nodules. We identified lymphocytes, plasma cells and macrophages among immunocompetent cells in lymphoid nodules (fig. 1).

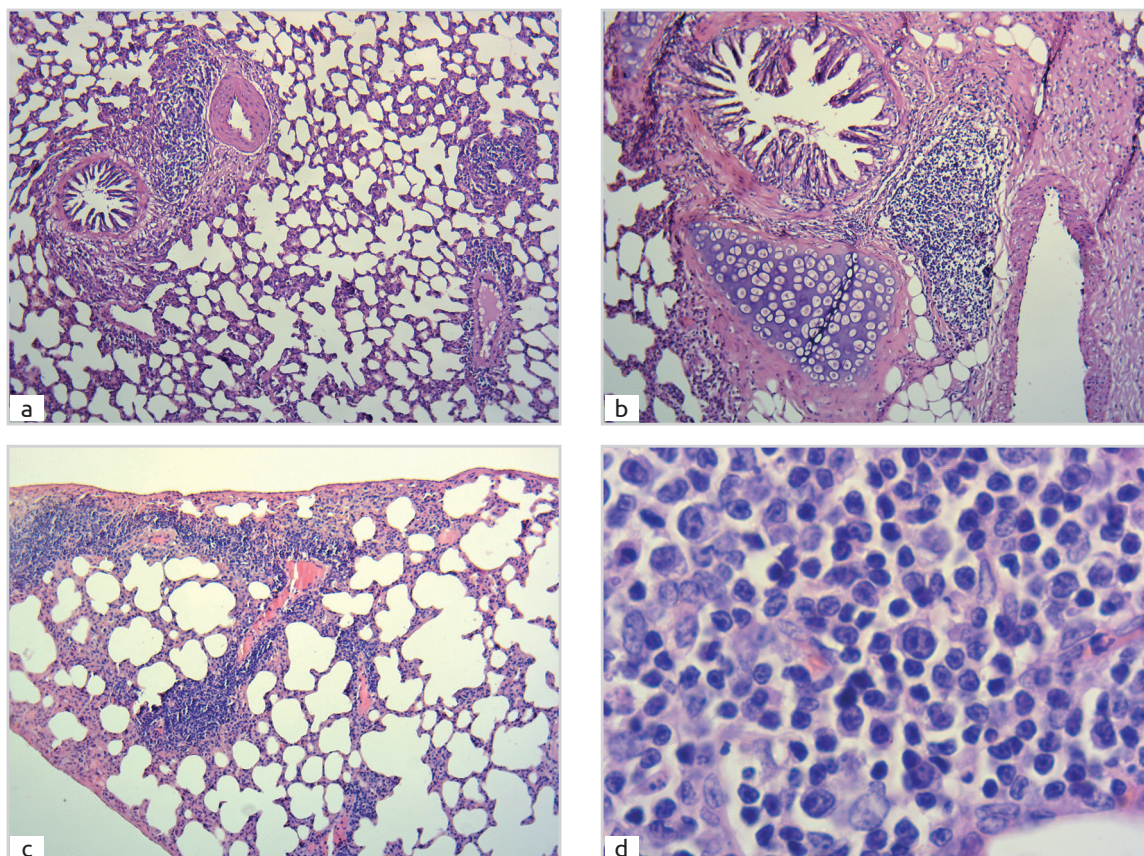


Fig. 1. Lymphoid nodules in guinea pigs' lung on the 30th (a, d), 44th days (b, c) after the start of the experiment. a – lymphoid nodule in the wall of small bronchus, perivascular lymphoid nodules; b – lymphoid nodule in the wall of cartilaginous bronchus. c – subpleural perivascular lymphoid nodules. d – cellular composition of the lymphoid nodule: 1 – lymphocyte; 2 – macrophage; 3 – plasmablasts; 4 – plasma cells; 5 – fibroblasts. Stain H. and E. 1a, 1b, 1c - $\times 100$; 1d - $\times 1000$.

Огляди літератури, **оригінальні дослідження**, погляд на проблему, випадок з практики, короткі повідомлення

There is a tendency to an increase in average number and diameter of lymphoid nodules in the dynamics of experimental ovalbumin-induced allergic inflammation. There was no statistically significant difference between the indices of the number and diameter of perivascular and peribronchial lymphoid nodules in animals of the intact and control groups, indicated that the experiment procedure itself does not affect changes in their morphometric parameters. There is a statistically significant difference between the diameters of lymphoid nodules in the control and experimental groups already in the early period of development of allergic inflammation: peribronchial – from the 23rd day, perivascular – from the 30th day of observation. In the 2nd experimental group the aver-

age diameter of perivascular lymphoid nodules of guinea pigs' lung was $143.10 \pm 3.22 \mu\text{m}$, which is statistically significantly more by 1.6 times ($p^{*/**} < 0.01$) than in the control group. In the late period of the development of allergic inflammation in guinea pigs' lung a statistically significant increase by 1,7 times ($p^{**} < 0.01$) in the diameter of perivascular lymphoid nodules compared with the control appeared in the 3rd experimental group on the 36th day of observation – $150.08 \pm 3.92 \mu\text{m}$. On the 44th day of observation, the average diameter of perivascular lymphoid nodules was $202.20 \pm 3.86 \mu\text{m}$, which is statistically significantly more by 2.3 times ($p^{*/**} < 0.001$) than the same indicator in the control group, by 1.7 times ($p^{*/**} < 0.01$) compared to the 1st experimental group (table).

Table. Morphometric parameters of lymphoid nodules in guinea pigs' lung in the dynamics of ovalbumin-induced allergic inflammation

Group	I	II	III	IV
1	3.12 ± 0.06	1.88 ± 0.30	119.08 ± 3.45	$100.54 \pm 0.78^{*/**}$
2	4.00 ± 0.11	2.25 ± 0.41	$143.10 \pm 3.22^{*/**}$	$134.34 \pm 2.68^{*/**}$
3	$4.38 \pm 0.08^{*/**}$	$2.75 \pm 0.08^{*/**}$	$150.08 \pm 3.92^{*/**}$	$144.96 \pm 0.92^{*/**}$
4	$4.62 \pm 0.37^{*/**}$	$3.12 \pm 0.58^{*/**}$	$202.20 \pm 3.86^{*/**}$	$221.97 \pm 3.96^{*/**}$
5	2.88 ± 0.30	1.62 ± 0.26	87.29 ± 1.33	84.20 ± 0.79
6	3.00 ± 0.27	1.50 ± 0.19	86.72 ± 1.03	86.35 ± 0.78

Note 1. * – $p < 0.05$ (Student's t-test); ** – $p < 0.05$ (U-Whitney-Mann test) compared to the control group. $M \pm m$. (n=8). Note 2. I – the average number of perivascular lymphoid nodules / 1 mm²; II – the average number of peribronchial lymphoid nodules / 1 mm²; III – diameter of perivascular lymphoid nodules (μm); IV – diameter of peribronchial lymphoid nodules (μm).

In animals of the 1st experimental group the average diameter of peribronchial lymphoid nodules of guinea pigs' lung was $100.54 \pm 0.78 \mu\text{m}$, which is statistically significantly by 1.2 times ($p^{**} < 0.01$) more than the same indicator of the control group. Statistically significant increase in the average diameter of peribronchial lymphoid nodules, compared to the control group, is also present in animals of the 2nd experimental group – $134.34 \pm 2.68 \mu\text{m}$, which is by 1.6 times ($p^{*/**} < 0.01$) more than in the control group. Statistically significant elevation in the average diameter of peribronchial lymphoid nodules, compared to the control group, available in animals of the 3rd experimental group – $144.96 \pm 0.92 \mu\text{m}$, which is 1.7 times more than the control and 1.4 times more than the same indicator of the 1st experimental group ($p^{*/**} < 0.001$). On the 44th day of observation, the average diameter of peribronchial lymphoid nodules of guinea pigs' lung was $221.97 \pm 3.96 \mu\text{m}$, which is statistically significantly by 2.6 times ($p^{*/**} < 0.001$) more compared to the control group and by 1,5 times more ($p^{*/**} < 0.01$) compared to the previous observation period (table).

Analyzing the average number of perivascular lymphoid nodules in guinea pigs lung, it turned out that it statistically significantly increased in compari-

son with the control only in the late period of the development of allergic inflammation from the 36th day after the start of the experiment and was 4.38 ± 0.08 in the field of view, which is more than the indicator of the control group by 1.5 times ($p^{*/**} < 0.01$) and more as compared to the 1st experimental group by 1.4 times ($p^{*/**} < 0.05$). On the 44th day of observation in animals of the 4th experimental group, this tendency persists and the average number of perivascular lymphoid nodules increased by 1.6 times ($p^{*/**} < 0.01$) compared to animals in the control group.

Thus, sensitization and allergization with ovalbumin leads to significant structural and functional rearrangement of Bronchus associated lymphoid tissue in the form of an elevation in their number and diameter. A similar trend is observed in the previous reported species [8–10]. The most significant changes occur during the late period of development of allergic inflammation in the peribronchial lymphoid nodules. This fact confirms the maximum magnification coefficient (2.6) of the diameter of peribronchial lymphoid nodules, found in the fourth experimental group compared to the control. Obviously, this study demonstrated that the implementation of the ovalbumin-induced allergic inflammatory process in lung proceeds according to the humoral type and

Огляди літератури, **оригінальні дослідження**, погляд на проблему, випадок з практики, короткі повідомлення
the duration of its course is not limited by the direct effect of the antigen, but also continues after the end of its action, which was in agreement with the previous observations [6, 11].

Conclusions. Sensitization and inhalation with ovalbumin leads to structural reorganization of Bronchus associated lymphoid tissue of guinea pigs in the form of the elevation in their number and diameter, had the unidirectional staged character depending on localization of lymphoid nodules and the duration of the experiment and claimed proliferative changes in the cellular adaptive link of local lung immunity of guinea pigs in late period of allergic in-

flammatory process.

Prospects for further research. We are going to study ultramicroscopical and immunohistochemical changes in Bronchus associated lymphoid tissue of guinea pigs in the dynamics of ovalbumin-induced allergic inflammation.

Funding. This research is a part of the research work of Zaporizhzhya State Medical University "Immunomorphological characteristics of internal organs under the influence of endo and exogenous factors on the body" state registration № 0118U004250.

Conflicts of interest. Author has no conflict of interest to declare.

LITERATURE

1. Hrebniak M. P. Influence of industrial atmospheric pollution on the development of pathology of respiratory organs / M. P. Hrebniak, R. A. Fedorchenko // *Pathologia*. – 2019. – Vol. 16 (1). – P. 81–86.
2. Bronchial response pattern of antigen presenting cells and regulatory T cells in children less than 2 years of age / I. Heier, K. Malmstrom, A. S. Pelkonen [et al.] // *Thorax*. – 2008. – Vol. 63 (8). – P. 703–709.
3. Lambrecht B. N. The immunology of asthma / B. N. Lambrecht, H. Hammad // *Nat. Immunol.* – 2014. – Vol. 16 (1). – P. 45–56.
4. Hwang, J. Y. Inducible Bronchus-Associated Lymphoid Tissue: Taming Inflammation in the Lung / J. Y. Hwang, T. D. Randall, A. Silva-Sanchez // *Front. Immunol.* – 2016. – Vol. 7. – P. 258.
5. Autoreactive T and B cells induce the development of bronchus-associated lymphoid tissue in the lung / R. A. Shilling, J. W. Williams, J. Perera // *Am. J. Resp. Cell Mol. Biol.* – 2013. – Vol. 48 (4). – P. 406–414.
6. Popko S. S. Morphological rearrangement of the metabolic link of the microcirculatory bed of guinea pigs lungs after sensitization with ovalbumin / S. S. Popko //

Current Issues in Pharmacy and Medicine: Science and Practice. – 2021. – Vol. 14 (1). – P. 79–83.

7. Albiflorin alleviates ovalbumin (OVA)-induced pulmonary inflammation in asthmatic mice / Z. Cai, J. Liu, H. Bian, J. Cai // *Am. J. Transl. Res.* – 2019. – Vol. 11 (12). – P. 7300–7309.

8. *Urtica dioica* attenuates ovalbumin-induced inflammation and lipid peroxidation of lung tissues in rat asthma model / H. Zemmouri, O. Sekiou, S. Ammar [et al.] // *Pharm. Biol.* – 2017. – Vol. 55 (1). – P. 1561–1568.

9. Antwi A. O. Stigmasterol modulates allergic airway inflammation in guinea pig model of ovalbumin-induced asthma / A. O. Antwi, D. D. Obiri, N. Osafo // *Mediators Inflamm.* – 2017. – Vol. 2017. – P. 2953930.

10. Pulmonary neuroendocrine cells amplify allergic asthma responses / P. Sui, D. L. Wiesner, J. Xu [et al.] // *Science*. – 2018. – Vol. 360 (6393). – P. eaan8546.

11. Popko S. S. Influence of pulmonary neuroendocrine cells on lung homeostasis / S. S. Popko, V. M. Evtushenko, V. K. Syrtsov // *Zaporozhye Medical Journal*. – 2020. – Vol. 22 (4). – P. 568–575.

REFERENCES

1. Hrebniak, M.P., & Fedorchenko, R.A. (2019). Influence of industrial atmospheric pollution on the development of pathology of respiratory organs. *Pathologia*, 16 (1), 81-86. DOI: <https://doi.org/10.14739/2310-1237.2019.1.166314>.
2. Heier, I., Malmstrom, K., Pelkonen, A.S., Malmberg, L.P., Kajosaari, M., Turpeinen, M., ..., & Makela, M.J. (2008). Bronchial response pattern of antigen presenting cells and regulatory T cells in children less than 2 years of age. *Thorax*, 63 (8), 703-709. DOI: <https://doi.org/10.1136/thx.2007.082974>.
3. Lambrecht, B.N., & Hammad, H. (2014). The immunology of asthma. *Nat. Immunol.*, 16 (1), 45-56. DOI: <https://doi.org/10.1038/ni.3049>.
4. Hwang, J.Y., Randall, T.D., & Silva-Sanchez, A. (2016). Inducible bronchus-associated lymphoid tissue in-

flammation in the lung. *Front. Immunol.*, 7 (258). DOI: <https://doi.org/10.3389/fimmu.2016.00258>.

5. Shilling, R.A., Williams, J.W., Perera, J., Berry, E., Wu, Q., Cummings, O.W., ..., & Huang, H. (2013). Autoreactive T and B cells induce the development of bronchus-associated lymphoid tissue in the lung. *Am. J. Resp. Cell Mol. Biol.*, 48 (4), 406-414. DOI: <https://doi.org/10.1165/rcmb.2012-0065oc>.

6. Popko, S.S. (2021). Morphological rearrangement of the metabolic link of the microcirculatory bed of guinea pigs lungs after sensitization with ovalbumin. *Current Issues in Pharmacy and Medicine: Science and Practice*, 14 (1), 79-83. DOI: <https://doi.org/10.14739/2409-2932.2021.1.226851>.

7. Cai, Z., Liu, J., Bian, H., & Cai, J. (2019). Albiflorin alleviates ovalbumin (OVA)-induced pulmonary inflammation in asthmatic mice. *Am. J. Transl. Res.*, 11 (12), 7300-7309.

- Огляди літератури, **оригінальні дослідження**, погляд на проблему, випадок з практики, короткі повідомлення
DOI: <https://www.ncbi.nlm.nih.gov/pmc/articles/PMC6943473/>.
8. Zemmouri, H., Sekiou, O., Ammar, S., El Feki, A., Bouaziz, M., Messarah, M., & Boumendjel, A. (2017). Urtica dioica attenuates ovalbumin-induced inflammation and lipid peroxidation of lung tissues in rat asthma model. *Pharm. Biol.*, 55 (1), 1561-1568. DOI: <https://doi.org/10.1080/13880209.2017.1310905>.
9. Antwi, A.O., Obiri, D.D., & Osafo, N. (2017). Stigmasterol modulates allergic airway inflammation in guinea pig model of ovalbumin-induced asthma. *Mediators Inflamm.*, 2017, 2953930. DOI: <https://doi.org/10.1155/2017/2953930>.
10. Sui, P., Wiesner, D.L., Xu, J., Zhang, Y., Lee, J., Van Dyken, S., ..., & Sun, X. (2018). Pulmonary neuroendocrine cells amplify allergic asthma responses. *Science*, 360(6393), eaan8546. DOI: <https://doi.org/10.1126/science.aan8546>.
11. Popko, S.S., Evtushenko, V.M., & Syrtsov, V.K. (2020). Influence of pulmonary neuroendocrine cells on lung homeostasis. *Zaporozhye Medical Journal*, 22 (4), 568-575. DOI: <https://doi.org/10.14739/2310-1210.4.208411>.

МОРФОЛОГІЧНА ХАРАКТЕРИСТИКА ЛІМФОЇДНОЇ ТКАНИНИ, АСОЦІЙОВАНОЇ З БРОНХАМИ МОРСЬКИХ СВИНОК, В ДИНАМІЦІ ЕКСПЕРИМЕНТАЛЬНОГО ОВАЛЬБУМІН-ІНДУКОВАНОГО АЛЕРГІЧНОГО ЗАПАЛЕННЯ

©С. С. Попко

Запорізький державний медичний університет

РЕЗЮМЕ. Актуальною проблемою сучасної медицини є реакція лімфоїдної тканини, асоційованої з бронхами, при хронічних алергічних захворюваннях дихальних шляхів, адже саме від стану місцевої імунної системи легень залежить повноцінне функціонування тканин та клітин дихальної системи організму.

Мета – вивчити морфологічні зміни лімфоїдної тканини, асоційованої з бронхами морських свинок, в динаміці експериментального овальбумін-індукованого алергічного запалення.

Матеріал і методи. За допомогою гістологічного, морфометричного та статистичного методів вивчили легені 48 самців морської свинки в умовах експериментального овальбумін-індукованого алергічного запалення. Для визначення структурної та функціональної перебудови лімфоїдних вузликів легень визначали величину їх діаметра та їх кількість.

Результати. Встановлено, що сенсibiliзація та алергізація овальбуміном призводить до суттєвої структурно-функціональної перебудови лімфоїдної тканини, асоційованої з бронхами морської свинки, у вигляді збільшення їх кількості та розмірів. Найсуттєвіші зміни відбуваються протягом пізнього періоду розвитку алергічного запалення у перибронхіальних лімфоїдних вузликах, що підтверджує максимальний коефіцієнт збільшення – 2,6 ($p^{***}<0,001$) діаметра перибронхіальних лімфоїдних вузликів в 4-ій експериментальній групі, порівняно з контролем.

Висновки. Сенсibiliзація та інгаляційна алергізація овальбуміном призводить до структурної реорганізації лімфоїдної тканини, асоційованої з бронхами морських свинок, у вигляді зростання їх кількості та розмірів, яка має односпрямований стадійний характер в залежності від локалізації лімфоїдних вузликів і тривалості експерименту та є проявом проліферативних змін клітинної адаптивної ланки місцевого імунітету легень морських свинок протягом пізнього періоду алергічного запального процесу.

КЛЮЧОВІ СЛОВА: лімфоїдна тканина; асоційована з бронхами; експериментальне алергічне запалення; овальбумін; морська свинка.

Отримано 22.09.2021