

Clinical cases of tattoo-associated dermatoses

H. I. Makurina ^{A,E,F}, L. O. Cherneda ^{*B,C,D}, O. S. Dolia ^{B,E}

Zaporizhzhia State Medical and Pharmaceutical University, Ukraine

A – research concept and design; B – collection and/or assembly of data; C – data analysis and interpretation; D – writing the article; E – critical revision of the article; F – final approval of the article

Ключові слова:

тату-асоційовані дерматози, алергічна реакція, гранулематозне запалення, патогістологічне дослідження.

Key words:

tattoo-associated dermatoses, allergic reaction, granulomatous inflammation, pathohistological examination.

Надійшла до редакції / Received: 08.06.2023

Після доопрацювання / Revised: 27.06.2023

Схвалено до друку / Accepted: 04.07.2023

Конфлікт інтересів: відсутній.

Conflicts of interest: authors have no conflict of interest to declare.

***E-mail:** lillia271212@gmail.com

The aim of the work is to analyze clinical cases of tattoo-associated skin reactions as an example of the algorithm of differential diagnosis of dermatoses of this group.

Materials and methods. The personal observation of two clinical cases related to tattooing for aesthetic reasons and the appearance of a pathological reaction on the skin after the introduction of dyes is described. In addition to the visual assessment of the clinical picture, the final confirmation of the diagnosis was based on pathohistological examination.

Results. Variability of clinical manifestations associated with tattooing is presented. The first clinical case is represented by the symmetrical appearance of a rash in the form of small papules up to 0.3–0.4 cm in diameter with clear borders, pink in color, and rounded in shape in the area of the eyebrows after their tattooing. Morphologically, the effect of black pigment on the skin in this case is represented by non-specific granulomatous inflammation. The second clinical case is characterized by the appearance of a plaque with hyperkeratosis phenomena and subjective complaints of slight itching at the site of red tattoo dye injection. Pathohistological examination indicated dermatitis of the mixed group (lichenoid interface and granulomatous), which is most correspond to an allergic reaction to tattoo pigment.

Conclusions. The increase in the number of patients with tattoos requires a wider consideration of the complications that can be provoked by the artificial injection of dyes into the skin. Despite the advantage of allergic complications after tattooing, the risk of systemic diseases should raise the level of vigilance of practicing physicians regarding the timely diagnosis of sarcoidosis or aggressive neoplasia. The pathohistological examination is the “gold standard” for the final verification of complications after the artificial injection of pigment into the skin.

Modern medical technology. 2023;(3):53-57

Клінічні випадки тату-асоційованих дерматозів

Г. І. Макуріна, Л. О. Чернеда, О. С. Доля

Мета роботи – аналіз клінічних випадків тату-асоційованих реакцій шкіри як приклад алгоритму диференційної діагностики дерматозів цієї групи.

Матеріали та методи. Описано власні спостереження за двома клінічними випадками, що пов'язані з татуванням з естетичних міркувань і виникненням патологічної реакції на шкірі після введення барвників. Здійснили візуальне оцінювання клінічної картини, але остаточне підтвердження діагнозу ґрунтувалося на патогістологічному дослідженні.

Результати. Наведено варіабельність клінічних проявів, що асоційовані з татуванням. Перший клінічний кейс представлений симетричною появою висипу – дрібних (до 0,3–0,4 см у діаметрі) папул з чіткими межами, рожевого кольору, округлої форми в ділянці брів після татуажу. Морфологічно вплив чорного пігменту на шкіру в цьому випадку визначили як неспецифічне гранулематозне запалення.

Для другого клінічного випадку характерні виникнення бляшки з явищами гіперкератозу та суб'єктивні скарги на незначний свербіж у місці введення барвника (тату червоного кольору). За результатами патогістологічного дослідження визначили дерматит змішаної групи (ліхеноїд-інтерфейс і гранулематозний), що найбільше відповідає алергічній реакції на тату-пігмент.

Висновки. Збільшення кількості пацієнтів із татуваннями потребують ширшого вивчення ускладнень, що можуть бути спричинені штучним введенням барвників у шкіру.

Незважаючи на переважання кількості випадків алергічних ускладнень після татуажу, ризик системних захворювань має підвищувати рівень настороженості практичних лікарів щодо вчасної діагностики саркоїдозу або агресивних неоплазій. Патогістологічне дослідження є «золотим стандартом» остаточної верифікації ускладнень після штучного введення пігменту в шкіру.

Сучасні медичні технології. 2023. № 3(58). С. 53-57

Among young and middle-aged people, skin tattooing does not lose its relevance both to correct aesthetic defects and to satisfy the need for self-identification. The nature of the artistic images and color scheme that can be found as a result of the procedure is quite individual and depend on the patient's personal preferences. Statistics on the number of people with tattoos vary widely. Thus, 36 % of US residents between 18 and 29 years old have at least one image on their body, in Great Britain this figure is 35 % for the age cohort older than 30 years [1]. There are no official statistical data in Ukraine, so it is difficult to objectively assess the situation.

But some conditions go beyond the scope of aesthetics, being beyond the competence of the medical field. First of all, this is due to an increase in the number of reports of altered skin reactivity to the injection of dyes into the skin. It is worth noting that the clinical picture of tattoo-associated dermatoses is not always specific, because it depends on many factors: the quality of the chemical composition of inks, the conditions of the procedure, genetic predisposition, and individual characteristics of the patient's body. The prevalence of adverse reactions to ink injection can range from 0.02 % to 1.10 %, depending on the sample and the tasks set in the studies [2]. The phenomena of hypersensitivity to red pigment-containing components, derivatives of mercury, and other metals, causing allergic reactions with a combination of dermal, mainly histiocytic infiltrates are most often described in literary sources [3,4]. Reactions to black dyes due to the following components are no less rare: polycyclic hydrocarbons, iron oxide, or phenols [5]. At the same time, to obtain a more contrasting color, hair dye with a rather powerful allergen – paraphenylenediamine is added to the black henna pigment [6]. But this is only the tip of the iceberg because dyes of other color gamuts can also be clinically represented by the appearance of abnormal efflorescences on the skin [7,8,9].

Aim

This work aims to analyze clinical cases of tattoo-associated skin reactions as an example of the algorithm for differential diagnosis of dermatoses in this group.

Materials and methods

Personal observations of two clinical cases related retrospectively to tattooing for aesthetic reasons and the appearance of a pathological reaction on the skin after the introduction of dyes are described.

Examination and diagnostic search took place at the departments of dermatovenerology and cosmetology with a course in dermatovenerology and aesthetic medicine and general surgery and postgraduate surgical education of the Zaporizhzhia State Medical and Pharmaceutical University.

In addition to the visual assessment of the clinical picture, the final confirmation of the diagnosis was based on a pathohistological examination, which was carried out in the CSD medical laboratory.

Results

Clinical case 1. Patient A. was born in 1980 and turned to a dermatovenerologist with complaints about the presence of a symmetrical rash on the skin within both eyebrows. According to the patient, this reaction occurred 2–3 months after the last tattoo. She noted that she had been doing this procedure for several years, but she had not observed a similar reaction before. Subjectively, apart from aesthetic discomfort, there were no complaints. The clinical picture is represented by small papules up to 0.3–0.4 cm in diameter with clear borders, pink color, and rounded shape (*Fig. 1*).

At the same time, the localization of efflorescences did not go beyond staining with a black dye, which led to the idea of a direct reaction to the pigment.

To establish the final diagnosis and further diagnostic and therapeutic treatment, a punch biopsy of the most elevated and infiltrated element was performed. The histological picture is presented in *Fig. 2*.

The pathohistological conclusion from all this can be done next: densely located non-caseating granulomas consisting of epithelioid histiocytes and multinucleated cells of the Pirogov–Langhans type are observed in the superficial layers of the dermis. Lymphocytic infiltrate with perifocal fibrosis and accumulation of black pigment is observed around the granulomas. Thus, the morphological picture corresponds to a fragment of skin with nonspecific granulomatous inflammation, probably as a manifestation of a reaction to a tattoo.

Clinical case 2. Patient M., was born in 2002 and turned to a surgeon because of resistant neoplasms on the skin of the outer surface of the right forearm, which appeared 3 months after the tattooing. The clinical situation is similar to the first case: a clear localization of the rash within the part of the tattoo image, but it is already red in color. Subjectively, the patient reported intermittent itching within the rash, but in general, the most alarming symptom for her was an increase in the size of this focus against the background of cancerophobic thoughts. Clinically, the rash is represented by a papule that rises above the level of the skin, on the surface of which there are hyperkeratosis phenomena, which are located along the “arrow” in the image of the tattoo (*Fig. 3*).

Such “deformation” of the tattoo hurt the psycho-emotional state of the patient. For treatment, she took antihistamines by herself in short courses with partially positive dynamics. The lack of the desired effect and the appearance of new elements of the rash prompted the woman to turn to specialists. Taking into account the concern about the disease with lymphoproliferative potential, and the possible occurrence of sarcoid-like reactions, and to establish the final diagnosis, a dermatoscopic examination (*Fig. 4*) was performed and a morphological study of the pathological foci was recommended.

Taking into account their size and the possible subsequent aesthetically unsatisfactory result from punch-removal with a small diameter, the consent, and desire of the patient regarding the removal method, complete excisional biopsy of the part of the tattoo with a red dye was recommended (*Fig. 5*).

Microscopic description of the removed skin area: Epidermis with orthohyperkeratosis, focal papillomatosis, expressed irregular acanthosis, moderate diffuse spongiosis, varying from mild to

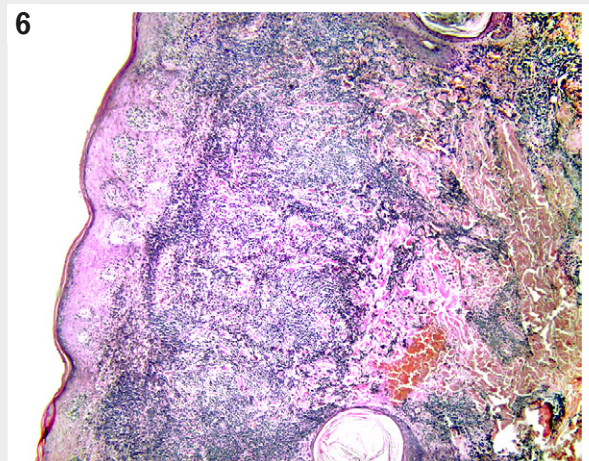
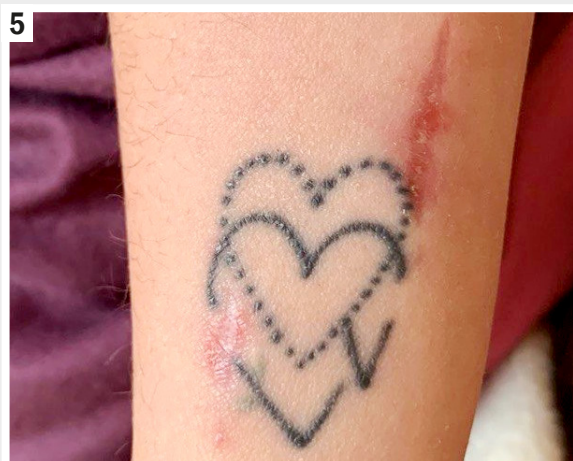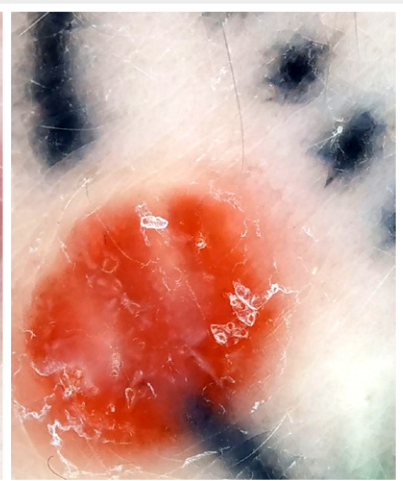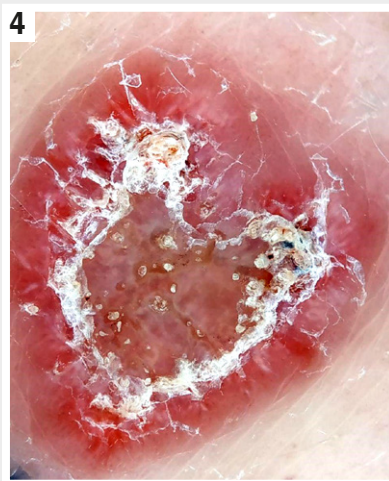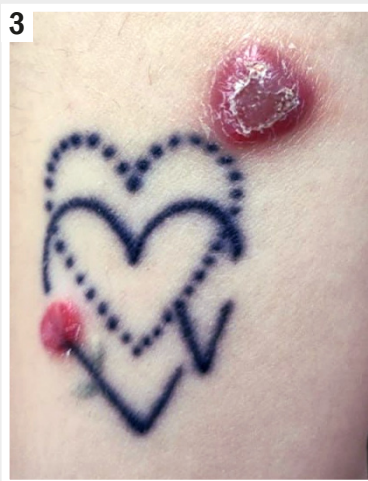
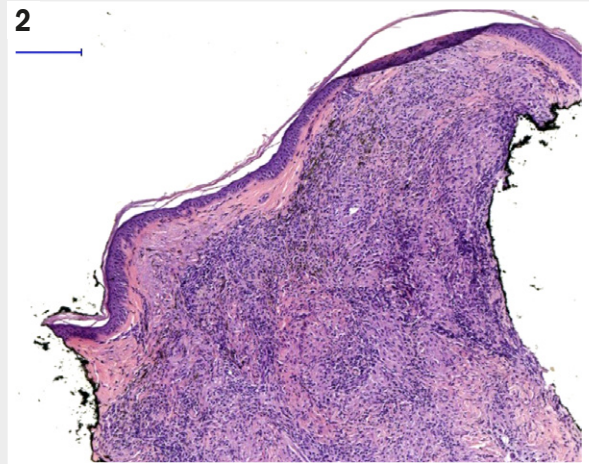


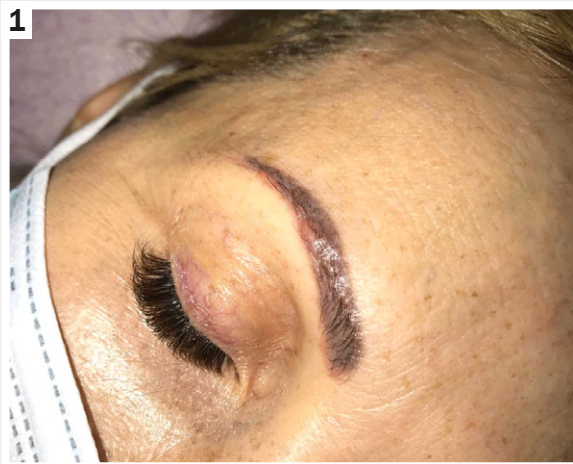Fig. 1. Elements of a rash within the eyebrows after tattooing.

Fig. 2. Morphological picture of the lesion affected by the tattoo of the clinical case 1.

Fig. 3. Clinical picture of the new lesion within the tattoo.

Fig. 4. Dermatoscopy of lesions in clinical case 2.

Fig. 5. The result of the excisional biopsy of a part of the tattoo with red pigment.

Fig. 6. Morphological picture of the lesion affected by the tattoo of clinical case 2.

moderate. At the border of the dermo-epidermal junction, signs of interface dermatitis are determined (vacuolar degeneration of basal keratinocytes, satellite necrosis, numerous "cytoid" bodies reach the granular layer, formation of a subepidermal cleft). A dense lichenoid lymphohistiocytic infiltrate with an admixture of melanophages, extravasated erythrocytes, and black and red pigment is determined at the border of the dermo-epidermal junction. The formation of individual non-caseating epithelioid cell granulomas is also determined (Fig. 6).

According to the results of an immunohistochemical study, the T-lymphocytes of the infiltrate cells are positive for CD2, CD3, CD5, CD7, some of the T-lymphocyte cells of the dermal infiltrate are positive for CD4, CD8 (the CD4:CD8 ratio was 2:1). Single cells of the dermal infiltrate are positive for CD56, CD30, B-lymphocytes of the dermal infiltrate are positive for CD20, histiocytes of the dermal infiltrate are positive for CD68, Langerhans cells are positive for CD1a. Up to 5 % of cells of the dermal infiltrate are positive for the proliferation marker Ki-67.

Thus, such a morphological picture makes it possible to attribute dermatitis to the group of mixed (lichenoid interface and granulomatous dermatitis) and, taking into account the clinical manifestations, as well as the results of an immunohistochemical study, it most closely corresponds to an allergic reaction to tattoo pigment.

Discussion

The variability of clinical manifestations after tattoos, which can be classified as complications of the procedure, can be quite wide. The main skin changes are usually divided into three groups: inflammatory, infectious, and neoplastic processes [10]. In addition, single cases of an unusual phenomenon associated with tattooing, which is characterized by the formation of a halo of intact skin around places with injected dye, have been described [11].

Furthermore, distinguishes local / systemic allergic and papulo-nodular reactions, neurosensitive conditions, scars and keloids, damage to lymph nodes, the result of mechanical errors of the tattoo artist, as well as psychosocial deviations. Thus, local allergic reactions can manifest in the form of plaque-like (eczematous and lichenoid subtypes), hyperkeratotic, and ulcerative-necrotic patterns [12,13]. At the same time, the elements of the rash are represented by monomorphic efflorescences. Most often, a reaction of this type is indicated by red tattoos. Our clinical case also corresponds to numerous international data in which complications of an allergic nature are correlated with the introduction of azo pigment.

Whereas sarcoid-like changes on the skin do not meet the criteria for dermatosis with an allergic background, but have the potential to mimic specific granulomatous inflammation, which in some places can occur in more than a quarter of tattooed individuals with a papulo-nodular patterns. Such agglomerates, usually of black pigment, are triggers, taking part in the "rush" phenomenon with the spread of similar changes in the places of various tattoos [14]. Usually, papulo-nodular complications do not manifest themselves quickly, but the suspicion of true sarcoidosis should prompt the doctor to respond to such a clinical situation as soon as possible with a general screening of organs and systems.

Given the color of the dye, and the late onset of the skin rash, the patient described by us from the first clinical case was also suspicious of sarcoidosis. It is worth noting that the absence of complaints about general well-being and changes in the organs of the chest after the radiographic examination additionally excluded a systemic, disseminated process. But, of course, the final verification was provided by the local pathohistological study and confirmed the main view of the first clinical case as a complication of artificial dye injection.

Bacterial and viral complications are usually associated with a violation of the procedure technique, general hygiene standards, and the use of poor-quality materials. Bacterial lesions from this category are represented not only by local skin changes in the form of abscesses and cellulitis but also by systemic lesions: endocarditis and septic shock [15]. And infection with viral agents – human papillomavirus, herpes, and molluscum contagiosum additionally confirm the thesis regarding the use of non-sterile tools and dyes, without excluding the theory of changes in the local immune response to exogenous influence [16].

A group of tattoo-associated dermatoses associated with the risk of neoplasias remains separate. But the question of the correlation between the introduction of dye and cases of skin cancer remains highly debatable. One of the most significant triggers is the use of pigments with high carcinogenic potential, containing both metals and dibutyl phthalate, hexachloro-1,3-butadiene, and methenamine, exhibiting geno- and cytotoxic activity [17]. Titanium dioxide admixtures on a reconstructed skin model also reduced cell viability with increased levels of interleukin-8 in fibroblasts [18]. Despite the description in the literature of clinical cases of melanoma, keratoacanthoma, squamous cell, and basal cell skin cancer, no direct strong connection between impurities in dyes and the appearance of neoplasias has been proven [19,20]. After all, the impact of the deposition of a dangerous pigment must be evaluated in a complex spectrum with an emphasis on exogenous factors, primarily ultraviolet radiation, which also induces phototoxic effects [21].

At the same time, the study of M. Sepehri et al. does not demonstrate the association of oncopathology, insolation, and tattooing [22]. Thus, the presence of a large number of triggers for the development of neoplastic processes usually leaves this problem in the field of "terra incognita". But, despite this, timely detection of skin cancer at the tattoo site remains a significant dilemma of modern dermatology. In this way, the presence of pigment around or in pigment neoplasms can both imitate a malignant transformation and generally "erase" the clinical and dermatoscopic picture.

Therefore, the variability of visual manifestations on skin with a tattoo and their mimicry with other dermatoses should alert doctors of practical medicine to more active monitoring of this cohort of patients.

Conclusions

1. Taking into account the variety of clinical manifestations of tattoo-associated dermatoses, a practicing doctor must take into account both the technical features of the procedure, the color of the dye, as well as the risks of developing possible complications,

and know the algorithm for further diagnostic and therapeutic management of such patients.

2. Despite the advantage of allergic complications after tattooing, the risk of developing systemic diseases is important, which increases the level of caution regarding the timely diagnosis of sarcoidosis or aggressive neoplasm. Clinical and morphological correlation of tattoo-associated dermatoses remains the "gold standard" for verification of the nosologies of this group.

Information about the authors:

Makurina H. I., MD, PhD, DSc, Professor, Head of the Department of Dermatovenerology and Cosmetology with the Course of Dermatovenerology and Aesthetic Medicine, Zaporizhzhia State Medical and Pharmaceutical University, Ukraine.

ORCID ID: 0000-0002-3293-2748

Cherneda L. O., PhD, Assistant of the Department of Dermatovenerology and Cosmetology with the Course of Dermatovenerology and Aesthetic Medicine, Zaporizhzhia State Medical and Pharmaceutical University, Ukraine.

ORCID ID: 0000-0002-3057-8685

Dolia O. S., PhD, Assistant of the Department of General Surgery and Postgraduate Surgical Education, Zaporizhzhia State Medical and Pharmaceutical University, Ukraine.

ORCID ID: 0000-0001-6916-5725

Відомості про авторів:

Макуріна Г. І., д-р мед. наук, професор,

зав. каф. дерматовенерології та косметології з курсом дерматовенерології та естетичної медицини, Запорізький державний медико-фармацевтичний університет, Україна.

Чернеда Л. О., д-р філософії, асистент каф. дерматовенерології та косметології з курсом дерматовенерології та естетичної медицини, Запорізький державний медико-фармацевтичний університет, Україна.

Доля О. С., канд. мед. наук, асистент каф. загальної хірургії та післядипломної хірургічної освіти, Запорізький державний медико-фармацевтичний університет, Україна.

References

- [1] Tattoo statistics - how many people have tattoos? [Internet]. History of Tattoos [cited 2023 Jun 25]. Available from: <http://www.historyoftattoos.net/tattoo-facts/tattoo-statistics>
- [2] Agarwal P, Jagati A, Mehta R, Vather P, Rathod S, Bodar P. Histopathological evaluation of cutaneous reactions to tattoos: Study at a tertiary care center. *J Cutan Pathol*. 2021;48(7):870-6. doi: 10.1111/cup.13973.
- [3] van der Bent S, Oyen E, Rustemeyer T, Jaspars L, Hoekzema R. Histopathology of Red Tattoo Reactions. *Am J Dermatopathol*. 2021;43(5):331-7. doi: 10.1097/DAD.0000000000001751.
- [4] Serup J, Hutton Carlsen K, Dommershausen N, Sepehri M, Hesse B, Seim C, et al. Identification of pigments related to allergic tattoo reactions in 104 human skin biopsies. *Contact Dermatitis*. 2020;82(2):73-82. doi: 10.1111/cod.13423.
- [5] Weiß KT, Schreiber I, Siewert K, Luch A, Haslböck B, Berneburg M, et al. Tattoos - more than just colored skin? Searching for tattoo allergens. *J Dtsch Dermatol Ges*. 2021;19(5):657-69. doi: 10.1111/ddg.14436.
- [6] Ogura Y, Morimoto H, Ohtsuka M, Tokura Y. Paraphenylenediamine ingredient possibly contributes to granuloma formation in inflammatory tattoo. *J Cutan Immunol Allergy*. 2022;5:72-3. doi: 10.1002/cia2.12214.
- [7] Karbowska B, Rebiś T, Zembrzaska J, Nadolska K. Thallium in color tattoo inks: risk associated with tattooing. *Med Pr*. 2020;71(4):405-11. doi: 10.13075/mp.5893.00934.
- [8] Tamaro A, Magri F, Chello C, Semicola A, Luzi F, De Marco G, et al. A peculiar adverse reaction to blue pigment tattoo. *J Cosmet Dermatol*. 2020;19(9):2401-2403. doi: 10.1111/jocd.13494.
- [9] van der Bent SAS, Berg T, Karst U, Sperling M, Rustemeyer T. Allergic reaction to a green tattoo with nickel as a possible allergen. *Contact Dermatitis*. 2019;81(1):64-6. doi: 10.1111/cod.13226.
- [10] Rahbarinejad Y, Guio-Aguilar P, Vu AN, Lo M, McTigue C, Nirenberg A, et al. Pathogenesis, Diagnosis and Management of Squamous Cell Carcinoma and Pseudoepithelial Hyperplasia Secondary to Red Ink Tattoo: A Case Series and Review. *J Clin Med*. 2023 Mar 21;12(6):2424. doi: 10.3390/jcm12062424.
- [11] Chen CA, Mikailov A, Faulkner-Jones B, Wu PA. Leukocytoclastic vasculitis sparing a tattoo with halo effect. *JAAD Case Rep*. 2015;1(5):269-71. doi: 10.1016/j.jdc.2015.06.002.
- [12] Serup J. How to Diagnose and Classify Tattoo Complications in the Clinic: A System of Distinctive Patterns. *Curr Probl Dermatol*. 2017;52:58-73. doi: 10.1159/000450780.
- [13] Silvestre JF, González Villanueva I. Diagnostic Approach for Suspected Allergic Cutaneous Reaction to a Permanent Tattoo. *J Investig Allergol Clin Immunol*. 2019;29(6):405-13. doi: 10.18176/jiaci.0383.
- [14] Sepehri M, Hutton Carlsen K, Serup J. Papulo-Nodular Reactions in Black Tattoos as Markers of Sarcoidosis: Study of 92 Tattoo Reactions from a Hospital Material. *Dermatology*. 2016;232(6):679-86. doi: 10.1159/000453315.
- [15] Rello J, Tejada S, Campogiani L, Adebajo AG, Tamaro A. Systemic infections associated with tattoos or permanent makeup: A systematic review. *Med Clin (Barc)*. 2022;158(4):159-66. English, Spanish. doi: 10.1016/j.medcli.2021.01.014.
- [16] Tampa M, Mitran MI, Mitran CI, Matei C, Amuzescu A, Buzatu AA, et al. Viral Infections Confined to Tattoos-A Narrative Review. *Medicina (Kaunas)*. 2022;58(3):342. doi: 10.3390/medicina58030342.
- [17] Lehner K, Santarelli F, Vasold R, König B, Landthaler M, Bäuml W. Black tattoo inks are a source of problematic substances such as dibutyl phthalate. *Contact Dermatitis*. 2011;65(4):231-8. doi: 10.1111/j.1600-0536.2011.01947.x.
- [18] Hering H, Zoschke C, Kühn M, Gadicherla AK, Weindl G, Luch A, et al. TatS: a novel in vitro tattooed human skin model for improved pigment toxicology research. *Arch Toxicol*. 2020;94(7):2423-34. doi: 10.1007/s00204-020-02825-z.
- [19] Leijts M, Schaefer H, Rübben A, Cacchi C, Rustemeyer T, van der Bent S. Cutaneous Malignancies in Tattoos, a Case Series of Six Patients. *Curr Oncol*. 2021;28(6):4721-37. doi: 10.3390/currenol28060398.
- [20] Ricci F, Paradisi A, Maier SA, Kovacs M, Podda M, Peris K, et al. Melanoma and tattoos: a case report and review of the literature. *Eur J Dermatol*. 2018;28(1):50-5. doi: 10.1684/ejd.2017.3184.
- [21] Lerche CM, Heerfordt IM, Serup J, Poulsen T, Wulf HC. Red tattoos, ultraviolet radiation and skin cancer in mice. *Exp Dermatol*. 2017;26(11):1091-6. doi: 10.1111/exd.13383.
- [22] Sepehri M, Lerche CM, Hutton Carlsen K, Serup J. Search for Internal Cancers in Mice Tattooed with Inks of High Contents of Potential Carcinogens: A One-Year Autopsy Study of Red and Black Tattoo Inks Banned in the Market. *Dermatology*. 2017;233(1):94-9. doi: 10.1159/000468150.