

## A case of severe COVID-19 and influenza co-infection

O. V. Riabokon<sup>1</sup>\*, A. E. F., O. O. Furyk<sup>1</sup> C, D, K. V. Kalashnyk<sup>1</sup> B, D

Zaporizhzhia State Medical and Pharmaceutical University, Ukraine

A – research concept and design; B – collection and/or assembly of data; C – data analysis and interpretation; D – writing the article; E – critical revision of the article; F – final approval of the article

**Aim.** To analyze a case of severe COVID-19 and influenza co-infection in a 48-year-old female patient.

**Materials and methods.** The clinical course, specifics of diagnosis and therapy of the 48-year-old patient S., who was treated for severe co-infection of COVID-19 and influenza at Municipal non-profit Enterprise “Regional Infectious Clinical Hospital” Zaporizhzhia Regional Council from 29.01.2023 to 17.02.2023, were analyzed. The diagnosis of COVID-19 was confirmed by the detection of SARS-CoV-2 Ag in nasopharyngeal swabs by the immunochromatographic method, and the diagnosis of influenza – by the influenza A viral RNA detection by the polymerase chain reaction method. Current regulatory documents were used when examining and treating the patient.

**Results.** It has been recognized that the unvaccinated 48-year-old female patient was at a risk group due to comorbid pathology (stage 2 hypertension, type 2 diabetes mellitus, grade 2 obesity) developed a severe course of COVID-19 and influenza type A co-infection. The course of co-infection was complicated by severe acute respiratory distress syndrome already on the 6<sup>th</sup> day of the disease. The diagnosis of COVID-19 was confirmed by a rapid SARS-CoV-2 antigen test. Treatment for COVID-19 was started immediately with the use of remdesivir, dexamethasone, and anticoagulants. However, despite the patient was given the treatment, his condition worsened due to the rapid progression of acute respiratory failure. The presence of clear clinical and laboratory signs of “cytokine storm” required the use of tocilizumab on the 7<sup>th</sup> day of the disease. Oseltamivir was commenced after receiving laboratory confirmation of influenza A by the PCR method on the 8<sup>th</sup> day of the disease. A complete etiologic interpretation of the diagnosis made it possible to prescribe a combination antiviral treatment which coupled with the timely additional initiation of tocilizumab, allowed obtaining certain positive dynamics after only five days of treatment with further improvement of the patient’s condition.

**Conclusions.** Our clinical observation has demonstrated the severe course of COVID-19 and influenza co-infection in the unvaccinated high-risk 48-year-old female patient due to the presence of comorbid pathology. The complete etiologic interpretation of the co-infection has made it possible to prescribe the combination antiviral treatment, which coupled with the additional correction of the immunotropic treatment has enabled to obtain the positive dynamics after only 5 days with further improvement of the patient’s condition

### Key words:

coronavirus disease COVID-19, influenza, viral infection, co-infection, clinic, complications, diagnosis, comorbidity, risk factors, treatment.

Zaporozhye medical journal, 2023. 25(5), 477-482

\*E-mail: ryabokonzsmu@ukr.net

## Випадок важкої ко-інфекції COVID-19 і грипу

О. В. Рябоконт, О. О. Фурик, К. В. Калашник

**Мета роботи** – проаналізувати випадок тяжкого перебігу ко-інфекції COVID-19 і грип у пацієнтки віком 48 років.

**Матеріали та методи.** Проаналізували клінічний перебіг, особливості діагностики та лікування хворої С. Віком 48 років, яка перебувала на стаціонарному лікуванні в КНП «Обласна інфекційна клінічна лікарня» ЗОР у період з 29.01.2023 р. до 17.02.2023 р. з приводу тяжкого перебігу ко-інфекції COVID-19 та грип. Діагноз COVID-19 підтверджено виділенням у носоглотковому слизу Ag SARS-CoV-2 імунохроматографічним методом, а діагноз грип – виділенням РНК вірусу грипу тип А методом полімеразної ланцюгової реакції. Під час обстеження та лікування пацієнтки дотримувалися чинних нормативних документів.

**Результати.** У невакцинованої пацієнтки віком 48 років, яка належить до групи ризику внаслідок наявності коморбідної патології (гіпертонічна хвороба 2 ст., цукровий діабет 2 типу, ожиріння 2 ст.), розвинувся тяжкий перебіг ко-інфекції COVID-19 та грип А, що ускладнилася тяжким гострим респіраторним дистрес-синдромом уже на 6 день хвороби. Діагноз COVID-19 підтверджено швидким тестом на виявлення Ag SARS-CoV-2, тому одразу почали лікування COVID-19, призначивши ремдесивір, дексаметазон, антикоагулянти. Втім, на тлі терапії стан хворої погіршився – спостерігали швидке прогресування гострої дихальної недостатності. Чіткі клініко-лабораторні ознаки «цитокінового шторму» зумовили необхідність призначити тоцилізумаб на 7 добу хвороби. Лабораторне підтвердження грипу А методом ПЛР на 8 добу хвороби спричинило призначення осельтамівіру. Повне етіологічне розшифрування діагнозу дало змогу призначити комбіноване протівірусне лікування, що в поєднанні з своєчасним додаванням до терапії тоцилізумабу сприяло позитивній динаміці вже через п’ять днів лікування з наступним поліпшенням стану пацієнтки.

**Висновки.** Наведене клінічне спостереження демонструє тяжкий перебіг ко-інфекції COVID-19 і грип у нещепленої пацієнтки віком 48 років, яка належить до групи ризику через наявність коморбідної патології. Завдяки точній діагностиці ко-інфекції призначили оптимальне комбіноване протівірусне лікування, що в поєднанні з корекцією імунотропного лікування сприяло позитивній динаміці вже через п’ять днів, надалі спостерігали покращення стану пацієнтки.

### Ключові слова:

коронавірусна хвороба COVID-19, грип, вірусна інфекція, ко-інфекція, клініка, ускладнення, діагностика, коморбідність, фактори ризику, лікування.

Запорізький медичний журнал, 2023. Т. 25, № 5(140). С. 477-482

The influenza virus and the causative agent of the novel coronavirus disease SARS-CoV-2 have a pandemic potential. Therefore, during the COVID-19 pandemic, a term “twin pandemic” appeared to denote the possibility of COVID-19 and influenza co-infection during seasonal flu [1]. Despite

a significant limitation of resources for testing patients for other respiratory viruses during the COVID-19 pandemic, in the first weeks of the pandemic, there were case reports on simultaneous detection of SARS-CoV-2 and influenza virus co-infection in patients [2,3].

Therefore, questions immediately arose as to the co-infection frequency, the severity of the course and the risk of the disease fatal outcome. Chinese researchers at the beginning of the first COVID-19 pandemic wave proved a high frequency of SARS-CoV-2 and influenza virus co-infection, namely 48.4 %, among patients with a severe and critical course of COVID-19 who were treated in intensive care units [2]. Throughout the first wave of the COVID-19 pandemic, 7.5 % of patients with etiologically specified acute respiratory diseases (influenza, adenovirus, metapneumovirus, parainfluenza, rhinovirus, respiratory syncytial virus) were diagnosed with COVID-19 co-infection.

To date, the accumulation of clinical observations of COVID-19 and influenza co-infection continues. The results of different researchers show certain variances in the results obtained. Some studies clearly demonstrate a higher mortality rate among patients co-infected with SARS-CoV-2 and the influenza virus than among patients with SARS-CoV-2 mono-infection [2,4,5]. However, other researchers have demonstrated co-infection outcomes similar to those of COVID-19 mono-infection [6,7]. Having regard to the similarity of clinical symptoms in respiratory infections, the presence of a pathogen other than SARS-CoV-2 can not provide assurance of the co-infection absence [8,9].

Therefore, understanding the clinical symptoms of co-infection with SARS-CoV-2 and the influenza virus would contribute to more targeted testing of patients and allow improving treatment results due to early etiologic confirmation of the diagnosis.

## Aim

To analyze a case of severe COVID-19 and influenza co-infection in a 48-year-old female patient.

## Materials and methods

An analysis of the clinical course, features of diagnosis and treatment of the 48-year-old patient S., who underwent inpatient treatment at the Municipal non-profit Enterprise "Regional Infectious Clinical Hospital" of Zaporizhzhia Regional Council (MNPE "RICH" ZRC) from 01.29.2023 to 02.17.2023, was conducted due to severe co-infection of COVID-19 and influenza. The diagnosis of COVID-19 was confirmed by the detection of SARS-CoV-2 antigen in a nasopharyngeal swab specimen by the immunochromatographic method. Influenza was diagnosed by the detection of influenza A viral RNA using polymerase chain reaction (PCR).

During the examination and treatment, the current regulatory documents of the Ministry of Health of Ukraine were used: Order of the Ministry of Health of Ukraine dated 28.03.2020 No. 722 "Organization of medical care for patients with coronavirus disease (COVID-19)" (as amended by Order of the Ministry of Health of Ukraine dated 22.02.2022 No. 358 on amendments to the protocol "Providing medical aid for the treatment of coronavirus disease (COVID-19)" and Order of the Ministry of Health of Ukraine dated 16.07.2014 No. 499 "Unified clinical protocol of primary, secondary (specialized) medical care for adults and children. Influenza".

## Results

**Clinical observation.** The 48-year-old patient S. was hospitalized to MNPE "RICH" ZRC on 29.01.2023 with complaints of fever up to 39.0 °C, weakness, dry cough, shortness of breath during physical exertion, and pasty stools up to 3 times a day.

According to her clinical history, she felt ill on 23.01.2023 with fever up to 38.0 °C, weakness, and an infrequent dry cough. She was treated with symptomatic drugs without any effect. On the 6<sup>th</sup> day of the illness, her condition worsened due to an increase in the level of fever to 39.0 °C, which was not amenable to correction with antipyretic agents, diarrhea and shortness of breath. The patient called an ambulance. On examination: respiratory rate – 28 per minute, oxygen saturation "in air" – 80 %. A rapid SARS-CoV-2 antigen test was performed, and the result was positive. The patient was admitted to the infectious disease hospital.

Based on a medical history, she was unvaccinated against COVID-19, and her influenza vaccination history was negative. At the same time, she had comorbid pathology that indicated a relation to the risk group, namely, stage 2 hypertension, type 2 diabetes mellitus (she did not take hypoglycemic agents regularly), grade 2 obesity (body mass index – 38.1 kg/m<sup>2</sup>).

When she was admitted to the infectious disease hospital on 29.01.2023 (the 6<sup>th</sup> day of the disease), her condition was determined as severe at an admission department: body temperature – 39.0 °C, tachycardia – 128 bpm, blood pressure – 150/90 mmHg, oxygen saturation without oxygen support – 72 %, bilateral bronchial and weak respiratory sounds in the lower parts of the lungs, crackling sound on pulmonary auscultation.

Considering the severity of the condition, the patient was immediately hospitalized to an intensive care unit. Humidified oxygen therapy with a rebreathing mask at a flow rate of 15 Liters per minute was urgently started, which helped to achieve an oxygen saturation of 97 %. Bilateral polysegmental pneumonia was confirmed radiologically on 29.01.2023. Lung ultrasound examination showed a complete disappearance of the pleural line and diffuse phenomena of interstitial edema, as indicated by large subpleural consolidations, which were more pronounced over the frontal and lateral surfaces (Fig. 1A, B).

According to laboratory tests upon admission to the intensive care unit on 29.01.2023 (the 6<sup>th</sup> day of the disease), the total number of leukocytes was  $4.3 \times 10^9/l$  with absolute lymphopenia up to  $0.4 \times 10^9/l$ ; a C-reactive protein (CRP) level was significantly elevated to 147.0 mg/L being associated with signs of hypercoagulation as evidenced by increased levels of fibrinogen to 4.5 g/L and D-dimer to 2.1 µg/L. Hyperglycemia was detected at a level of 15.5 mmol/l signifying decompensation of type 2 diabetes mellitus (Table 1). Complex medical treatment was started, including remdesivir, low molecular weight heparin (LMWH) in a therapeutic dose, dexamethasone, correction of hyperglycemia with insulin.

However, amid the treatment within a day, the patient's condition worsened due to the progression of acute respiratory failure since the oxygen saturation level was decreased to 88 % despite a high-flow mask at 15 L/minute oxygen. The patient therefore needed to undergo non-invasive ventilation (NIV). At the same time, on day 7 of the disease,

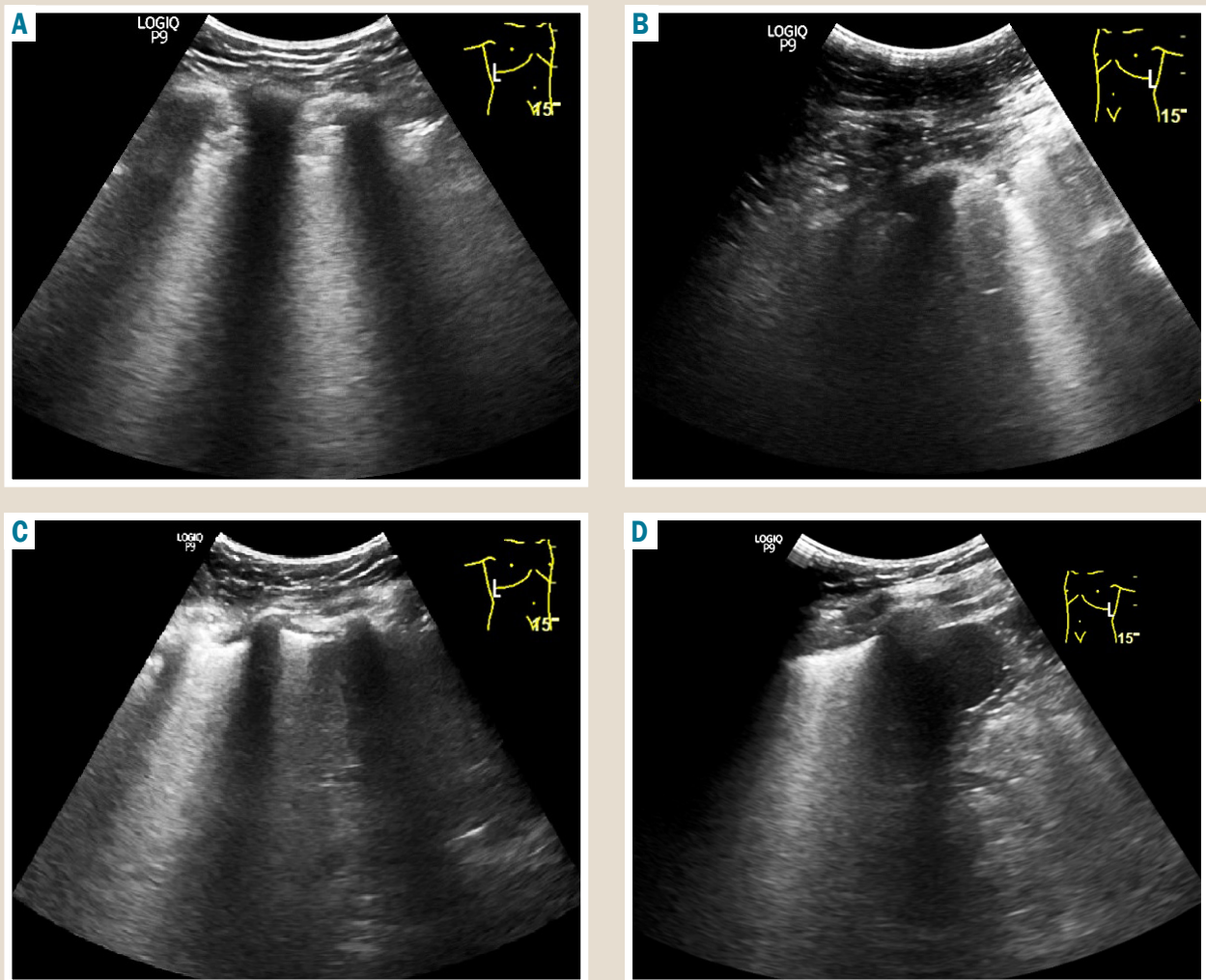


Fig. 1. Lung ultrasound examination of the 48-year-old patient S. **A, B:** upon hospital admission; **C, D:** in the treatment dynamics.

Table 1. Dynamic clinical and laboratory parameters of the 48-year-old patient S. given the treatment tactics

Parameter, units of measurement	Day 6 from symptom onset	Day 7 from symptom onset	Day 8 from symptom onset	Day 11 from symptom onset	Day 14 from symptom onset	Day 21 from symptom onset
Etiologic interpretation of the diagnosis	Positive Ag SARS-CoV-2		Positive Influenza A virus RNA			
Fever, °C	39.0	39.5	36.7	36.8	36.6	36.6
Oxygen requirement	80 % (without O <sub>2</sub> ) 96 % (O <sub>2</sub> 15 L/min)	88 % (O <sub>2</sub> 15 L/min) → NIV (P support 110 mm H <sub>2</sub> O, H <sub>2</sub> O, FIO <sub>2</sub> 96 %, PEEP 50 mm)	NIV (P support 110 mm H <sub>2</sub> O, FIO <sub>2</sub> 96 %, PEEP 50 mm)	NIV (P support 90 mm H <sub>2</sub> O, FIO <sub>2</sub> 75 %, PEEP 50 mm)	NIV (P support 90 mm H <sub>2</sub> O, FIO <sub>2</sub> 50 %, PEEP 50 mm)	97 % (O <sub>2</sub> 15 L/min)
Leukocytes, ×10 <sup>9</sup> /l	4.3	8.7	8.4	11.2	9.7	8.2
Lymphocytes, ×10 <sup>9</sup> /l	0.4	0.5	1.1	1.1	1.2	1.2
Glucose, mmol/l	15.5	23.5	10.5	13.5	11.8	10.5
CRP, mg/L	147.0		63.9	37.5	67.4	34.1
Prothrombin index, %	63.8	91.6	103.3	58	80	86
Fibrinogen, g/l	4.5	4.3	4.2	4.5	4.2	4.2
International normalized ratio	1.32	1.15	1.41	1.44	1.11	1.13
D-dimer, µg/l	2.1	13.4		8.3	6.1	2.3
Procalcitonin, mg/ml	0.33	0.12		0.33	0.36	0.1
Creatinine, µmol/l	77.9	78.0	171.0	188.0	168.0	125.0
GFR, ml/min	106	104	47	43	49	65
ALT, U/l	30.1	28.0	32.2	45.0	43.0	41.5
Treatment tactics	Remdesivir, LMWH, Glucocorticosteroids	Remdesivir, Tocilizumab, LMWH, Glucocorticosteroids	Remdesivir, Oseltamivir, LMWH, Glucocorticosteroids	Remdesivir, Oseltamivir, LMWH, Glucocorticosteroids	LMWH, Glucocorticosteroids	LMWH

there were clear clinical and laboratory signs of “cytokine storm”, namely, continuing hyperthermia at 39.5 °C, rapid progression of respiratory failure (immunotropic treatment with glucocorticosteroids notwithstanding), persistence of marked absolute lymphopenia  $0.5 \times 10^9/l$  and signs of hypercoagulability with increased D-dimer up to 13.4  $\mu g/l$ . This became the basis for the additional use of immunotropic treatment with tocilizumab in a dose of 800 mg once intravenously (*Table 1*).

On day 8 of the disease, normothermia was achieved, CRP decreased to 63.9 mg/l, and the absolute number of lymphocytes increased to  $1.1 \times 10^9/l$ . However, there were no signs of positive dynamics regarding regression of acute respiratory failure. In addition, an increase in the blood creatinine level to 171  $\mu mol/l$  and a decrease in the glomerular filtration rate (GFR) to 47 ml/min were noted. This pointed to an acute kidney injury. It was possible to correct the blood glucose level and stabilize it at a level of 10.5 mmol/l. On day 8 of the disease, the nasopharyngeal swab sample was positive for influenza A viral RNA detected by PCR. Considering the data obtained on the etiologic interpretation of the diagnosis, taking into account the severity of the disease course, oseltamivir was prescribed at a dose of 150 mg 2 times a day (*Table 1*).

Upon the therapy, on day 11 of the disease (after 5 days of treatment), a tendency towards positive dynamics of the patient's condition was apparent, namely, the oxygen concentration was reduced to 75 % during NIV, the CRP level decreased to 37.5 mg/l. However, laboratory signs of hypercoagulation and acute kidney injury persisted (*Table 1*). It was during this period of observation that positive changes in the lung ultrasound findings were seen: a decrease in the edema extent and the transformation of diffuse subpleural consolidations into well-defined interstitial edema of the lung parenchyma (*Fig. 1C, 1D*).

During follow-up, the indicated positive clinical dynamics were maintained, which helped to reduce the oxygen concentration to 75 % during NIV from the 14<sup>th</sup> day of the disease (the 8<sup>th</sup> day of treatment), and the patient was switched to oxygen support with high-flow oxygen mask at the rate of 15 L/minute from the 21<sup>st</sup> day of the disease (the 15<sup>th</sup> day of treatment). Laboratory changes during this observation period showed a stable normalization of the absolute number of blood lymphocytes, a continuous decrease in the level of CRP to 34.1 mg/l, a decrease in the level of D-dimer to 2.3  $\mu g/l$ , normalization of procalcitonin level, regression of acute kidney injury with a decrease in the blood creatinine level to 125.0  $\mu mol/l$  and restored GFR to 65 ml/min (*Table 1*). In view of the disease duration and the clear positive clinical and laboratory dynamics for further treatment, the patient was transferred to a Pulmonology Department of a Multidisciplinary Hospital at her place of residence.

## Discussion

The beginning of the new coronavirus disease COVID-19 pandemic coincided with the beginning of the flu season in the Northern Hemisphere. The first clinical study to clarify the features of COVID-19 and influenza co-infection was conducted in Wuhan, China, in January – February 2020 during the first wave of the pandemic, when the Wuhan SARS-CoV-2 strain began to circulate (original) [2]. At that

time, almost half of patients with a severe and critical course of COVID-19 were found to be co-infected with the influenza virus [2]. According to this study results, an association between the risk of fatal outcome and the presence of co-infection with SARS-CoV-2 and the influenza virus has not been proven. However, the results of this first Chinese study have found that co-infection with SARS-CoV-2 and the influenza virus can cause more earlier and severe “cytokine storm” in critically ill patients. This has been confirmed by a higher level of leukocytosis, blood creatinine, TNF- $\alpha$ , D-dimer, in particular, a higher frequency of D-dimer level detection  $>5 \mu g/ml$ , as well as a higher frequency of acute myocardial damage in co-infection than in mono-infection with COVID-19 [2]. Our own clinical observation has also demonstrated the early development of clinical and laboratory signs of “cytokine storm”. This was evidenced by the appearance and rapid progression of acute respiratory failure on the 6–7<sup>th</sup> days of the disease, the development of significant lymphopenia up to  $0.4 \times 10^9/l$  and the significant increase in the level of D-dimer up to 13.4  $\mu g/l$ .

The first wave of the COVID-19 pandemic in the European region also coincided with a seasonal increase in the number of influenza cases. According to the British study results, it has been proven that patients with a laboratory-confirmed diagnosis of influenza appeared as early as the 4<sup>th</sup> week of 2020, while the first cases of COVID-19 were recorded from the 6<sup>th</sup> week of 2020 [10]. The simultaneous circulation of SARS-CoV-2 and the influenza virus occurred for eight weeks. However, with increased circulation, SARS-CoV-2 rapidly caused influenza A(H3N2) activity to decline as the dominant strain. Even during this limited period of overlap between the circulation of the influenza virus and SARS-CoV-2, the analysis of detected co-infection cases made it possible to ascertain that the risk of fatal outcome due to co-infection was 5.92 times higher than under conditions of mono-infection with the influenza virus, and also higher than with SARS-CoV-2 mono-infection (43.1 % vs. 26.9 %) [10]. According to the results of other studies in 2020 [2,4,5], it has been also recognized that the mortality rate was higher in co-infection with COVID-19 and influenza than in mono-infection with SARS-CoV-2.

The following years 2020–2021 passed with almost no mention of influenza, which can be explained in part by a low activity of influenza due to non-pharmaceutical measures to control COVID-19 [11,12]. However, in the 2022–2023 season, a clear increase in the incidence of influenza was recorded and, accordingly, an issue arose about co-infection of COVID-19 and influenza [13,14]. It is known that during the period of the COVID-19 pandemic, there were changes in the circulation dominance of the different SARS-CoV-2 strains, which determined the clinical and epidemiological features of COVID-19.

Taking into account the above, there was a question about clarifying the features of COVID-19 and influenza co-infection during different pandemic waves. In an American study [14], it has been found that the circulation of the influenza virus occurred for a short period of time at the beginning of the COVID-19 pandemic during the circulation of the Wuhan strain of SARS-CoV-2 (original). While during the circulation of Alpha and Delta strains of SARS-CoV-2, there were almost no reports of co-infection [14]. The circulation of the influenza virus expressively increased with



the beginning of the Omicron SARS-CoV-2 strain circulation and, accordingly, the frequency of co-infection increased significantly [14].

In the period of time when the Omicron strain was spreading significantly, and the Delta strain of SARS-CoV-2 had not yet disappeared from the circulation, the frequency of COVID-19 and influenza co-infection cases, requiring hospitalization, was considerably increased. Thus, in that time period, according to data [15], among hospitalized patients, the prevalence of influenza co-infection among patients with COVID-19 was 33 %. However, when determining the frequency of co-infection with SARS-CoV-2 and the influenza virus among the total number of patients with signs of acute respiratory viral infection, this indicator was 1.35 % during the circulation of the Omicron strain [16].

Today, other researchers also demonstrate, on the one hand, a high intensity of the Omicron SARS-CoV-2 strain and the influenza virus circulation, and on the other hand, a low frequency of co-infection with these viruses, which is 0.061 % [13]. The study [13] has revealed no statistically significant differences in 30-day hospitalization, a risk of hospitalization in intensive care units, and a risk of death between cases of co-infection with COVID-19 and influenza and mono-infection with SARS-CoV-2. However, clinical symptomatology in case of co-infection was more pronounced due to much more symptoms and a higher frequency of nasal congestion, cough, fatigue, fever, headache, myalgia and arthralgia, pharyngitis, rhinitis. The researchers explain a lack of difference in the frequency of adverse consequences of co-infection with COVID-19 and influenza by the significantly younger age of the co-infected during the period of the Omicron strain circulation, the lower frequency of comorbid diseases and the higher rate of full vaccination status against COVID-19 [13].

The severe course of COVID-19 and influenza co-infection, which has been presented in our clinical observation during the Omicron SARS-CoV-2 strain circulation, in our opinion, was caused by simultaneous infection with the two mentioned viruses, as well as the fact that the 48-year-old patient was unvaccinated both against COVID-19 and influenza; the presence of comorbid pathology, namely hypertension, type 2 diabetes mellitus, obesity, which categorized the patient to the risk group for an adverse course of these infections.

During the COVID-19 pandemic, studies showed substantial difficulties in differential diagnosis between other causes of severe acute respiratory distress syndrome and COVID-19, especially during the flu season, because common clinical manifestations of COVID-19, namely fever, cough, and dyspnea, mimic flu symptoms [3,8,17,18]. It is known that patients with a severe course of COVID-19 have lymphopenia in blood samples, and chest computed tomography shows infiltration and consolidation with bilateral involvement [19,20]. However, it is also known that the influenza virus and some other respiratory viruses can cause similar changes [21]. Therefore, there are no clear clinical and laboratory characteristics that allow to differentiate co-infection of COVID-19 and influenza from mono-infection [22]. Due to similar clinical symptoms of most acute respiratory viral infections and the clinical manifestations of COVID-19, many researchers have emphasized recommendations for the development of a

comprehensive diagnostic panel for the detection of respiratory viruses [17,18].

According to the results of our clinical observation, testing for both infections during hospitalization of the patient with severe acute respiratory viral infection complicated by acute respiratory distress syndrome has enabled us to make an early etiologic interpretation of the diagnosis of co-infection. It was an opportunity to use simultaneously both remdesivir and oseltamivir. The use of combination antiviral therapy for co-infection of COVID-19 and influenza and timely correction of immunotropic treatment have helped to achieve positive clinical and laboratory dynamics in the unvaccinated high-risk patient due to comorbid pathology.

## Conclusions

1. Our clinical observation has demonstrated the severe course of co-infection with COVID-19 and influenza in the unvaccinated high-risk 48-year-old patient. The development of severe acute respiratory distress syndrome was observed on the 6th day of the disease.

2. The lack of effect from the started treatment for COVID-19 within a day with the use of remdesivir, corticosteroids and anticoagulants, the presence of clear clinical and laboratory signs of “cytokine storm” required additional immunotropic therapy on the 7th day of the disease. After obtaining laboratory confirmation of influenza, on the 8th day of the disease, oseltamivir was prescribed.

The complete etiologic interpretation of the diagnosis has made it possible to prescribe the combination antiviral treatment, which coupled with the timely additional administration of tocilizumab has enabled to obtain certain positive dynamics after only 5 days of treatment with further improvement of the patient's condition and recovery.

**Conflicts of interest:** authors have no conflict of interest to declare.  
**Конфлікт інтересів:** відсутній.

Надійшла до редакції / Received: 20.04.2023

Після доопрацювання / Revised: 08.05.2023

Схвалено до друку / Accepted: 06.06.2023

## Information about the authors:

Riabokon O. V., MD, PhD, DSc, Professor, Head of the Department of Infectious Diseases, Zaporizhzhia State Medical and Pharmaceutical University, Ukraine.

ORCID ID: 0000-0002-7394-4649

Furyk O. O., MD, PhD, Associate Professor of the Department of Infectious Diseases, Zaporizhzhia State Medical and Pharmaceutical University, Ukraine.

ORCID ID: 0000-0002-5196-7698

Kalashnyk K. V., MD, PhD, Assistant of the Department of Infectious Diseases, Zaporizhzhia State Medical and Pharmaceutical University, Ukraine.

ORCID ID: 0000-0002-4532-8953

## Відомості про авторів:

Рябоконт О. В., д-р мед. наук, професор, зав. каф. інфекційних хвороб, Запорізький державний медико-фармацевтичний університет, Україна.

Фурик О. О., канд. мед. наук, доцент каф. інфекційних хвороб, Запорізький державний медико-фармацевтичний університет, Україна.

Калашник К. В., PhD, асистент каф. інфекційних хвороб, Запорізький державний медико-фармацевтичний університет, Україна.

## References

- Rubin, R. (2020). What Happens When COVID-19 Collides With Flu Season? *JAMA*, 324(10), 923. <https://doi.org/10.1001/jama.2020.15260>
- Ma, S., Lai, X., Chen, Z., Tu, S., & Qin, K. (2020). Clinical characteristics of critically ill patients co-infected with SARS-CoV-2 and the influenza virus in Wuhan, China. *International Journal of Infectious Diseases*, 96, 683-687. <https://doi.org/10.1016/j.ijid.2020.05.068>
- Wu, X., Cai, Y., Huang, X., Yu, X., Zhao, L., Wang, F., Li, Q., Gu, S., Xu, T., Li, Y., Lu, B., & Zhan, Q. (2020). Co-infection with SARS-CoV-2 and Influenza A Virus in Patient with Pneumonia, China. *Emerging Infectious Diseases*, 26(6), 1324-1326. <https://doi.org/10.3201/eid2606.200299>
- Yue, H., Zhang, M., Xing, L., Wang, K., Rao, X., Liu, H., Tian, J., Zhou, P., Deng, Y., & Shang, J. (2020). The epidemiology and clinical characteristics of co-infection of SARS-CoV-2 and influenza viruses in patients during COVID-19 outbreak. *Journal of Medical Virology*, 92(11), 2870-2873. <https://doi.org/10.1002/jmv.26163>
- Hashemi, S. A., Safamanesh, S., Ghafouri, M., Taghavi, M. R., Mohajer Zadeh Heydari, M. S., Namdar Ahmadabad, H., Ghasemzadeh-Moghaddam, H., & Azimian, A. (2020). Co-infection with COVID-19 and influenza A virus in two died patients with acute respiratory syndrome, Bojnurd, Iran. *Journal of Medical Virology*, 92(11), 2319-2321. <https://doi.org/10.1002/jmv.26014>
- Kondo, Y., Miyazaki, S., Yamashita, R., & Ikeda, T. (2020). Coinfection with SARS-CoV-2 and influenza A virus. *BMJ Case Reports*, 13(7), e236812. <https://doi.org/10.1136/bcr-2020-236812>
- Konala, V. M., Adapa, S., Naramala, S., Chenna, A., Lamichhane, S., Garlapati, P. R., Balla, M., & Gayam, V. (2020). A Case Series of Patients Coinfected With Influenza and COVID-19. *Journal of Investigative Medicine High Impact Case Reports*, 8, 232470962093467. <https://doi.org/10.1177/2324709620934674>
- Kim, D., Quinn, J., Pinsky, B., Shah, N. H., & Brown, I. (2020). Rates of Co-infection Between SARS-CoV-2 and Other Respiratory Pathogens. *JAMA*, 323(20), 2085. <https://doi.org/10.1001/jama.2020.6266>
- Riabokon, O. V., Pak, K. A., Riabokon, Yu. Yu., Furyk, O. O., & Cherkaskyi, V. V. (2022). Extrapulmonary manifestations of coronavirus disease (COVID-19): current status (a literature review). *Zaporozhye medical journal*, 24(5), 607-612. <https://doi.org/10.14739/2310-1210.2022.5.259096>
- Stowe, J., Tessier, E., Zhao, H., Guy, R., Muller-Pebody, B., Zambon, M., Andrews, N., Ramsay, M., & Lopez Bernal, J. (2021). Interactions between SARS-CoV-2 and influenza, and the impact of coinfection on disease severity: a test-negative design. *International Journal of Epidemiology*, 50(4), 1124-1133. <https://doi.org/10.1093/ije/dyab081>
- Olsen, S. J., Winn, A. K., Budd, A. P., Prill, M. M., Steel, J., Midgley, C. M., Kniss, K., Burns, E., Rowe, T., Foust, A., Jasso, G., Merced-Morales, A., Davis, C. T., Jang, Y., Jones, J., Daly, P., Gubareva, L., Barnes, J., Kondor, R., ... Silk, B. J. (2021). Changes in Influenza and Other Respiratory Virus Activity During the COVID-19 Pandemic – United States, 2020–2021. *MMWR. Morbidity and Mortality Weekly Report*, 70(29), 1013-1019. <https://doi.org/10.15585/mmwr.mm7029a1>
- Sakamoto, H., Ishikane, M., & Ueda, P. (2020). Seasonal Influenza Activity During the SARS-CoV-2 Outbreak in Japan. *JAMA*, 323(19), 1969. <https://doi.org/10.1001/jama.2020.6173>
- Pawlowski, C., Silvert, E., O'Horo, J. C., Lenehan, P. J., Challenger, D., Gnass, E., Murugadoss, K., Ross, J., Speicher, L., Geyer, H., Venkatakrishnan, A. J., Badley, A. D., & Soundararajan, V. (2022). SARS-CoV-2 and influenza co-infection throughout the COVID-19 pandemic: An assessment of co-infection rates, cohort characteristics, and clinical outcomes. *PNAS Nexus*. <https://doi.org/10.1093/pnasnexus/pgac071>
- He, Z., & Tao, H. (2018). Epidemiology and ARIMA model of positive-rate of influenza viruses among children in Wuhan, China: A nine-year retrospective study. *International Journal of Infectious Diseases*, 74, 61-70. <https://doi.org/10.1016/j.ijid.2018.07.003>
- Tang, C. Y., Boftsi, M., Staudt, L., McElroy, J. A., Li, T., Duong, S., Ohler, A., Ritter, D., Hammer, R., Hang, J., & Wan, X.-F. (2022). SARS-CoV-2 and influenza co-infection: A cross-sectional study in central Missouri during the 2021-2022 influenza season. *Virology*. <https://doi.org/10.1016/j.virol.2022.09.009>
- Rezaee, D., Bakhtiari, S., Jalilian, F. A., Doosti-Irani, A., Asadi, F. T., & Ansari, N. (2023). Coinfection with severe acute respiratory syndrome coronavirus 2 (SARS-CoV-2) and influenza virus during the COVID-19 pandemic. *Archives of Virology*, 168(2). <https://doi.org/10.1007/s00705-022-05628-y>
- Lv, Z., Cheng, S., Le, J., Huang, J., Feng, L., Zhang, B., & Li, Y. (2020). Clinical characteristics and co-infections of 354 hospitalized patients with COVID-19 in Wuhan, China: a retrospective cohort study. *Microbes and Infection*, 22(4-5), 195-199. <https://doi.org/10.1016/j.micinf.2020.05.007>
- Aghbash, P. S., Eslami, N., Shirvaliloo, M., & Baghi, H. B. (2021). Viral coinfections in COVID-19. *Journal of Medical Virology*, 93(9), 5310-5322. <https://doi.org/10.1002/jmv.27102>
- Chen, N., Zhou, M., Dong, X., Qu, J., Gong, F., Han, Y., Qiu, Y., Wang, J., Liu, Y., Wei, Y., Xia, J., Yu, T., Zhang, X., & Zhang, L. (2020). Epidemiological and clinical characteristics of 99 cases of 2019 novel coronavirus pneumonia in Wuhan, China: a descriptive study. *The Lancet*, 395(10223), 507-513. [https://doi.org/10.1016/s0140-6736\(20\)30211-7](https://doi.org/10.1016/s0140-6736(20)30211-7)
- Huang, C., Wang, Y., Li, X., Ren, L., Zhao, J., Hu, Y., Zhang, L., Fan, G., Xu, J., Gu, X., Cheng, Z., Yu, T., Xia, J., Wei, Y., Wu, W., Xie, X., Yin, W., Li, H., Liu, M., ... Cao, B. (2020). Clinical features of patients infected with 2019 novel coronavirus in Wuhan, China. *The Lancet*, 395(10223), 497-506. [https://doi.org/10.1016/s0140-6736\(20\)30183-5](https://doi.org/10.1016/s0140-6736(20)30183-5)
- Sullivan, S. J., Jacobson, R. M., Dowdle, W. R., & Poland, G. A. (2010). 2009 H1N1 Influenza. *Mayo Clinic Proceedings*, 85(1), 64-76. <https://doi.org/10.4065/mcp.2009.0588>
- Antony, S. J., Almaghouth, N. K., & Heydemann, E. L. (2020). Are coinfections with COVID-19 and influenza low or underreported? An observational study examining current published literature including three new unpublished cases. *Journal of Medical Virology*, 92(11), 2489-2497. <https://doi.org/10.1002/jmv.26167>