



O.M. Raznatovska¹, V.I. Petrenko², O.S. Shalmin¹,
R.M. Yasinskyi¹, A.V. Fedorets¹, O.A. Svitlytska¹

¹ Zaporizhzhia State Medical and Pharmaceutical University,
Zaporizhzhia, Ukraine

² Bogomolets National Medical University, Kyiv, Ukraine

A clinical case of multidrug-resistant tuberculosis complicated by esophageal-pulmonary fistula in a palliative patient

We present our own observation of the multidrug-resistant tuberculosis course case, complicated by esophageal-pulmonary fistula, in a palliative patient who was treated in the Pulmonary Tuberculosis Department No. 2 of the Zaporizhzhia Regional Phthisio-pulmonology Clinical Treatment and Diagnostic Center. An esophago-pulmonary fistula in the patient with multidrug-resistant tuberculosis was detected in the area of the right upper lobectomy, which was performed 8.5 years ago. The patient was on palliative treatment for almost 6 years before hospital admission when a tubercular esophago-pulmonary fistula was diagnosed. The patient was admitted to the hospital in serious condition, which significantly worsened over the course of a month. A decision was made to perform a computed tomography of the chest cavity (Chest CT) as the patient's cough and chest pain were associated with liquid food intake. Esophageal-pulmonary fistula was detected on the Chest CT as a linear air defect of the esophageal wall up to 1.5 mm, which conjugates with the cavern in the upper lobe of the right lung. The small size of the esophageal-pulmonary fistula (1.5 mm) indicates the timeliness of its detection. In the presented case, the patient is on palliative treatment. Therefore, in order to prevent the progression of the esophageal-pulmonary fistula, feeding through a nasogastric tube and antibiotic therapy were prescribed. Thus, if a palliative patient with multidrug-resistant tuberculosis has a paroxysmal cough that occurs during or immediately after eating, the use of Chest CT is relevant for the timely diagnosis of esophageal-pulmonary fistula. If such a fistula is diagnosed, it is necessary to use parenteral feeding and antibiotic therapy.

Keywords

Multidrug-resistant tuberculosis, esophageal-pulmonary fistula, palliative care.

Esophageal fistulas can be: esophago-bronchial, esophago-pulmonary and esophago-pleural. Treatment of such fistulas can be both conservative and operative (depending on the patient's condition). Treatment of delayed esophago-bronchial, esophago-pulmonary and esophago-pleural fistulas after pneumonectomy is mainly surgical [6, 10].

Esophageal-pleural fistulas are rare and can occur as a result of pneumonectomy in tuberculosis or lung cancer, malignant neoplasm of the esophagus [2]. Such fistulas are a potential danger for patients. However, the literature describes a clinical case of an accidental diagnosis of an esophago-pleural fis-

tula in a 64-year-old patient 30 years after right-sided pneumonectomy due to tuberculosis (asymptomatic course) [11]. At the same time, the authors prefer such a diagnostic method of the esophago-pleural fistula visualization as a Chest CT with contrast.

N. Kokuho et al. [5] described their own clinical case of a mycobacterial lung abscess caused by *Mycobacterium avium* in a 55-year-old woman, which was complicated by an esophago-pulmonary fistula. The authors concluded that esophageal-pulmonary fistula is not only a complication of mycobacterial lung abscess but also as a factor of its aggravation.

An esophago-pulmonary fistula was detected on Chest CT and confirmed by esophagoscopy. The authors explained the mechanism of esophageal-pulmonary fistula development as follows. After the patient was diagnosed with a mycobacterial infection (which was successfully treated by antimycobacterial drugs (AMD)), a lung abscess developed 12 years later, leading to the development of an adhesion process between the tracheobronchial lymph nodes and the esophagus with the development of a traction diverticulum in future. In the presented clinical case, aspiration of fluid through a fistula caused a cough reflex, which caused further spread of the abscess along the tracheobronchial tree.

G. Behera et al. [1] observed an esophago-pleural fistula in a patient with tuberculosis. The authors noted that the use of pleural cavity drainage, antibiotics, antimycobacterial therapy (AMBT) and feeding through a nasogastric tube were enough to completely cure the patient.

K. Madan et al. [8] in their study also indicate that timely diagnosed tuberculous esophago-bronchial fistula does not require surgical intervention. Thus, the authors described a clinical case in a young woman with tuberculous mediastinal lymphadenopathy complicated by a left-sided esophago-bronchial fistula, which was detected at an early stage. As a result of timely prescribed conservative treatment (AMBT), the patient fully recovered.

Having analyzed the features of the course of the esophageal-bronchial fistula as a result of tuberculosis of the mediastinal lymph nodes in a 19-year-old patient, L.Y. Liao et al. [7] found that such a fistula heals due to AMBT, and it was possible to prevent fistula's contamination by a permanent gastric tube without the use of surgical intervention. The patient's main complaints were severe intoxication and cough associated with eating. At the same time, the authors emphasize the fact that it is important to use such methods as Chest CT, fibrobronchoscopy and clinical testing (methylene blue) for the timely diagnosis of such a complication as an esophago-bronchial fistula.

H.G. Mittal et al. [9] observed a 16-year-old girl with tuberculous mediastinal lymphadenopathy and bilateral hydrothorax, who had an esophago-bronchial fistula. The patient was admitted to the hospital with complaints of pronounced intoxication, severe cough after eating, weight loss during the last 3 months and shortness of breath during the last 10 days. *Mycobacterium tuberculosis* (MTB) susceptible to rifampicin (R) were detected by the molecular genetic method. The authors point out that the use of AMBT and gastric tube feeding in the patient healed the fistula already at the end of the intensive phase of treatment. Esophago-bronchial fistula in

the patient was diagnosed by 2 such methods, as Chest CT and fibrobronchoscopy. At the same time, the authors point out that if there is persistent cough after eating in patient with tuberculous mediastinal lymphadenopathy, then the patient must be examined for the presence of an esophago-bronchial fistula. V. Indiran [4] also points out the need for an urgent follow-up examination for the presence of an esophago-bronchial fistula when persistent uncontrolled cough in patients with tuberculosis.

K.B. Gupta et al. [3], in their clinical case, describe two fistulas (esophageal-pleural and esophageal-bronchial) in one patient as a complication of tuberculous mediastinal lymphadenopathy. Initially, the researchers suspected an esophago-pleural fistula clinically based on the color of the pleural fluid during hydrothorax puncture. The presence of these two fistulas was already confirmed during the examination with contrast, including the Chest CT.

M. Sasaki et al. [12] described a clinical case of 26-year-old man with complaints of a continuous cough with lymphadenitis and bacterial excretion who was found to have an esophago-mediastinal fistula on Chest CT. An esophago-bronchial fistula was also detected after a week of AMBT taking, he complained of increased cough after liquid food. The authors also indicate that Chest CT, fibrobronchoscopy and esophagoscopy are relevant for the timely diagnosis of esophago-bronchial fistula.

K.K. Sidhu et al. [13] described a clinical case in which tuberculosis was complicated by pneumopericarditis and esophago-pericardial fistula in a 35-year-old patient. In this case, to control the fistula and prevent infection from mediastinitis, the use of AMBT alone was not sufficient, so the patient underwent esophageal stenting.

As we can see from the review of literary sources, the cause of the development of such complications as esophago-bronchial and esophago-pleural fistulas is tuberculous mediastinal lymphadenopathy.

The formation of an esophago-pulmonary fistula in tuberculosis patients after surgery is a rather rare complication. Therefore, the alertness of physicians in terms of such fistulas detection is reduced, which is the reason for both late diagnosis and untimely specialized care, and often — death. However, in the available literary sources, we did not find described clinical cases of esophago-pulmonary fistulas that conjugate that conjugate with the cavern in patients with MDR-TB.

Therefore, the purpose of the study was to observe an MDR-TB case, complicated an esophageal-pulmonary fistula, in a palliative patient who was treated in the Pulmonary Tuberculosis Department No. 2 of the Zaporizhzhia Regional Phthisio-Pulmonology Clinical Treatment and Diagnostic Center.

Clinical case

Patient O., 57 years old. It is known from the anamnesis that he first had tuberculosis in 2014 (infiltrative tuberculosis of the upper lobe of the right lung, Destruction+, MTB+). After receiving a course of treatment for drug-susceptible tuberculosis, the destruction continued to persist in the upper lobe of the right lung, which became the reason for surgical intervention (right upper lobe lobectomy). In May 2016, there was a relapse of tuberculosis, which was accompanied by bacterial excretion and a destructive process (Fig. 1).

At this time, the patient was found to have multiple drug resistance of MTB to AMD. Therefore, the case was registered as MDR-TB infiltrative of the operated right lung. Destruction+, MTB+, culture (C)+, phenotypic drug-susceptibility test (phDST)+ (isoniazid (H), R, streptomycin (S)). State after surgery (2014) – right-sided upper lobe lobectomy.

Appropriate treatment according to DST was started. However, in December 2016, the patient voluntarily interrupted AMBT. As a result, in March 2017, he was transferred to palliative treatment. In June 2017, the X-ray picture remained consistent with the changes diagnosed at the beginning of MDR-TB treatment (Fig. 2). Additionally, the patient categorically refused to continue AMBT.

The patient was hospitalized to the Pulmonary Tuberculosis Department No. 2 of the Zaporizhzhia Regional Phthisio-pulmonology Clinical Treatment and Diagnostic Center in December 2022 in a serious condition. The patient presented with complaints of paroxysmal cough, that occurred during or immediately after eating, with purulent sputum, pronounced shortness of breath, pain in the chest on the right, an increase in body temperature to 39 °C, general weakness and a loss of body weight up to 15 kg in the last 4 months.

The patient was examined, including a digital fluorogram (D-X-ray) from 12.20.2022 and a chest X-ray from 12.23.2022. Negative dynamics were determined (Fig. 3 and 4): there is a state after resection of the upper lobe, with the postoperative suture being destroyed on the right; narrow horizontal fluid levels in the 3rd and 4th intercostal spaces; collapse of the lung in the upper right lung field by 1/8 of its volume; mixed fibrosis and polymorphic foci in the middle lung field; and an increase in the lung pattern in the lower lung field. Additionally, there are single compacted foci on the background of fibrosis in the upper lobe and S6 on the left; consolidated fractures of ribs 8–10; emphysematous basal parts of the lungs; deformed and fibrously changed roots, pulled up; and pulmonary heart.

The result of a rapid HIV test is negative.

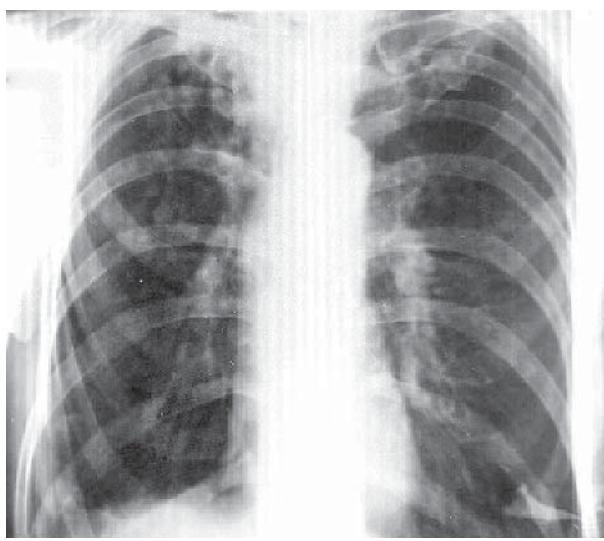

Fig. 1. Chest X-ray from 24.05.2016

In the upper lobe of the right lung, there is a post-operative condition after surgery with a metal chain, focal-infiltrative changes of a heterogeneous structure due to destruction up to 1.5 cm, fibrosis.

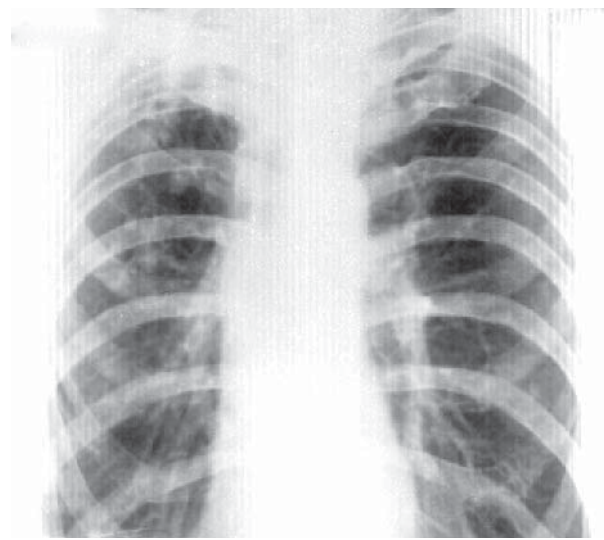


Fig. 2. Chest X-ray from 16.06.2017

In the upper lobe of the right lung, there is a post-operative condition with a metal chain, focal-infiltrative changes of a heterogeneous structure due to destruction up to 1.5 cm, fibrosis.

The result of a rapid test for viral hepatitis C (HCV) is positive.

The result of PCR blood analysis for HCV is positive (HCV 1/54 E05 IU/ml, log 5.52).

The result of the blood test for HBsAg is negative.

Biochemical analysis of blood: bilirubin – 9.42 mmol/l, thymol test (ThT) – 8.39 units, alanine aminotransferase (AlAt) – 0.21 mmol/l/h, aspartate aminotransferase (AsAt) – 0.26 mmol/l/h, total protein (TP) – 59.3 g/l, glucose – 5.1 mmol/l, creatinine – 77.0 μmol/l, urea – 4.57 mmol/l, residual urea nitrogen – 2.13 mmol/l.

Blood analysis: hemoglobin (Hb) – 119.3 g/l, erythrocytes (Er) – 3.82 · 10¹²/l, leukocytes

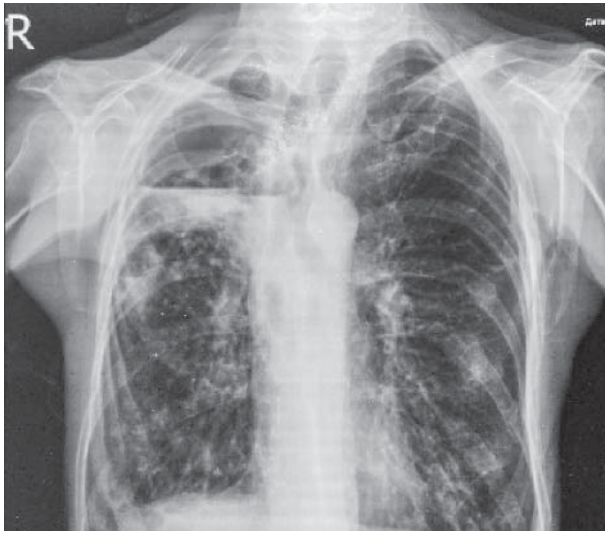

Fig. 3. D-X-ray from 20.12.2022

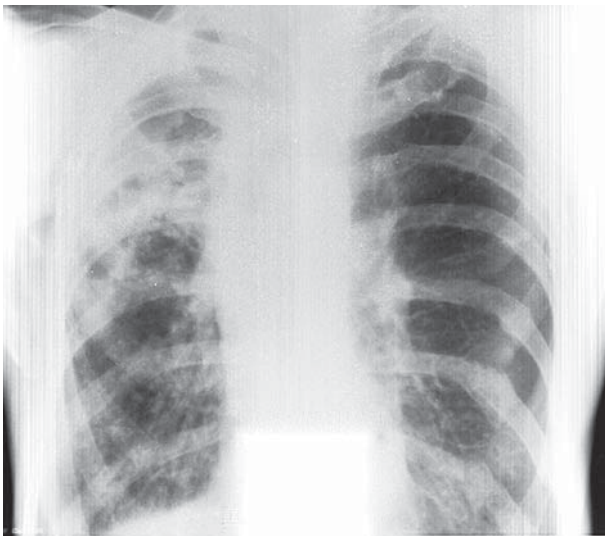


Fig. 4. Chest X-ray from 23.12.2022

(WBC) – $9.3 \cdot 10^9/l$, platelets (pl) – $209 \cdot 10^9/l$, eosinophils (Ef) – 0%, band neutrophils (b/n) – 12%, segmented neutrophils (s/n) – 66%, lymphocytes (Lf) – 17%, monocytes (m) – 5%, erythrocyte sedimentation rate (ESR) – 65 mm/h.

Urine analysis: specific gravity – 1014, pH – acidic, protein – 0.33 g/l, erythrocytes – 2–4 in the vision field (v/f), leukocytes – 5–8 in v/f, renal epithelium – 1–2 in v/f, granular cylinders – 1–2 in v/f.

Electrocardiogram (ECG) conclusion: Sinus rhythm, heart rate 75/min, single rare atrial extrasystoles. The voltage is sufficient, and the heart electrical axis (HEA) is not deviated. There are signs of left atrial and ventricular myocardial hypertrophy. Diffuse changes are in the myocardium of the ventricles, with QTcF = 396 msec.

The conclusion of an ultrasound examination of the organs of the abdominal cavity reveals echo signs of unexpressed hepatomegaly and unexpressed diffuse changes in the parenchyma of the pancreas.

Conclusion of an infectious disease specialist: Chronic hepatitis C.

Ophthalmologist's conclusion: Immature cataract of the right eye (OD), almost mature cataract of the left eye (OS). Medications such as ethambutol (E) and linezolid (Lzd) are contraindicated.

The therapist's conclusion: Chronic obstructive pulmonary disease (COPD), clinical group C, Stage III, exacerbation phase. Pulmonary insufficiency (PI) of Grade II. Cachexia.

The diagnosis detected is MDR-TB infiltrative of the operated right lung. Destruction+, MTB+, C+, pH DST (HRS). Resistance – (kanamycin (Km), capreomycin (Cm), ethionamide (Et), cycloserine (Cs), paraaminosalicylic acid (Pas)). Histology 0 (palliative treatment on March 6, 2017). There is a state after surgery (2014) with a right-sided upper lobe lobectomy. Chronic viral hepatitis C. COPD, clinical group C, Stage III, exacerbation phase. PI of Grade II. Cachexia.

Symptomatic treatment was prescribed for the patient, along with COPD therapy following the recommendations of the therapist. Treatment for chronic viral hepatitis C was also initiated based on the recommendations of the infectious disease specialist.

However, the patient's overall condition worsened, as evidenced by an increase in symptoms of intoxication, shortness of breath, cough with purulent sputum, and right-sided chest pain. It was noted that the cough and chest pain were associated with the intake of liquid food.

On January 31, 2023, the patient underwent a Chest CT (Fig. 5), which revealed the following diagnoses: fibrous-cavernous tuberculosis of the right lung in the contamination phase, esophageal-pulmonary fistula on the right (Fig. 6), cylindrical bronchiectasis, partial obliteration of the right costo-phrenic sinus and pleural-phrenic adhesions on both sides.

Considering the detected esophageal-pulmonary fistula that connects with the cavern, the patient was additionally prescribed feeding through a nasogastric tube and antibiotic therapy. Surgical intervention was recommended.

Analyzing the data of the presented clinical case, we observe that an esophageal-pulmonary fistula was detected in a patient with MDR-TB in the area where the right upper lobe lobectomy was performed 8.5 years ago. The patient had been receiving palliative treatment for nearly 6 years before being admitted to the hospital, where a tubercular esophago-

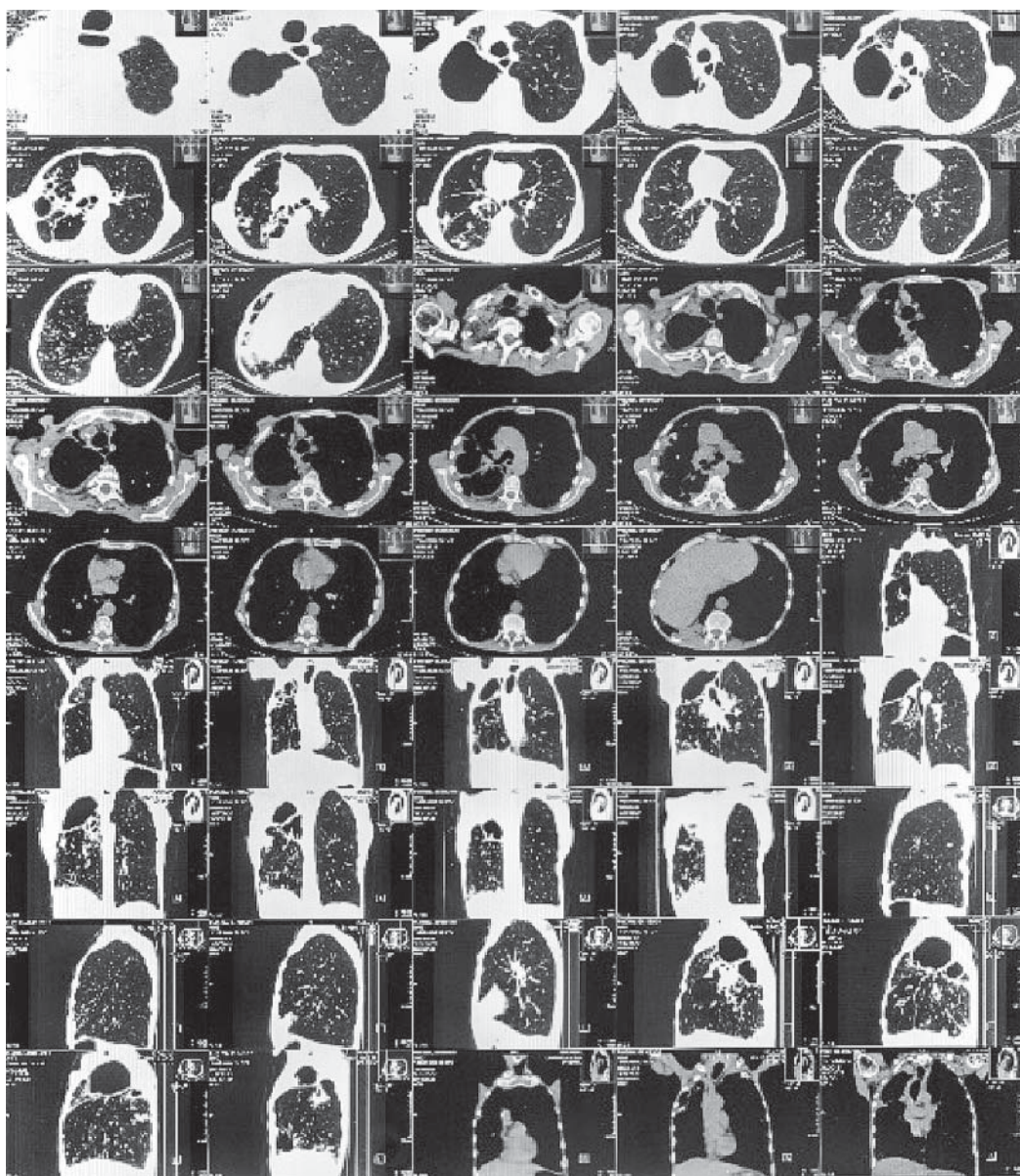


Fig. 5. Chest CT from 31.01.2023

A decrease of the right lung due to fibrosis is determined. The parenchyma of the upper lobe of the right lung is almost completely destroyed by the caverna magna, which has deformed bay-shaped walls with sizes $125 \times 77 \times 91$ mm, with a low horizontal level in it. There are another cavity of size 65×42 mm with a low horizontal level in S6 in right lung, next to it and subpleurally an infiltrate of size 36×25 mm with destruction measuring 14×8 mm, in S5 destruction measuring 15×12 mm, in the lower lobe infiltrates up to 20 mm, in S10, an infiltrate measuring 52×27 mm with air gaps in the structure. Throughout the lung fields of both lungs, more on the right, there are numerous calcifications of 1–6 mm and polymorphic, mostly dense foci up to 14 mm in size. The lung pattern is partially deformed. The trachea is partially shifted to the right. Bronchi of the I–V degree are cylindrically expanded, their walls are unevenly thickened, compacted, without visible intra-luminal pathology. The mediastinum is not expanded, moderately shifted to the right, no pathological formations in the mediastinum were found. No effusion was found in the pericardial cavity, the pericardial leaves were not thickened, and pulmo-pericardial adhesions were identified. A linear air defect up to 1.5 mm in the esophageal wall is diagnosed at the level of the Th3–Th4 discs, which is conjugates with the cavern in the upper lobe of the right lung. The esophagus is straightened throughout due to the air trunk. Few broncho-pulmonary lymph nodes on the right up to 9 mm are determined. Pleural-diaphragmatic adhesions on both sides are detected.

pulmonary fistula was diagnosed. Upon admission, the patient was in a serious condition, which progressively worsened over the course of a month. The worsening condition was characterized by increasing symptoms of intoxication, shortness of breath, cough with purulent sputum, and right-sided chest pain.

A decision was made to perform a Chest CT as the patient's cough and chest pain were associated

with the intake of liquid food. The Chest CT revealed an esophageal-pulmonary fistula as a linear air defect in the esophageal wall measuring up to 1.5 mm. This defect was found to be connected to the cavern in the upper lobe of the right lung. Numerous researchers emphasize that Chest CT is the primary and most important method for detecting such fistulas [3–5, 7, 9, 11, 12].

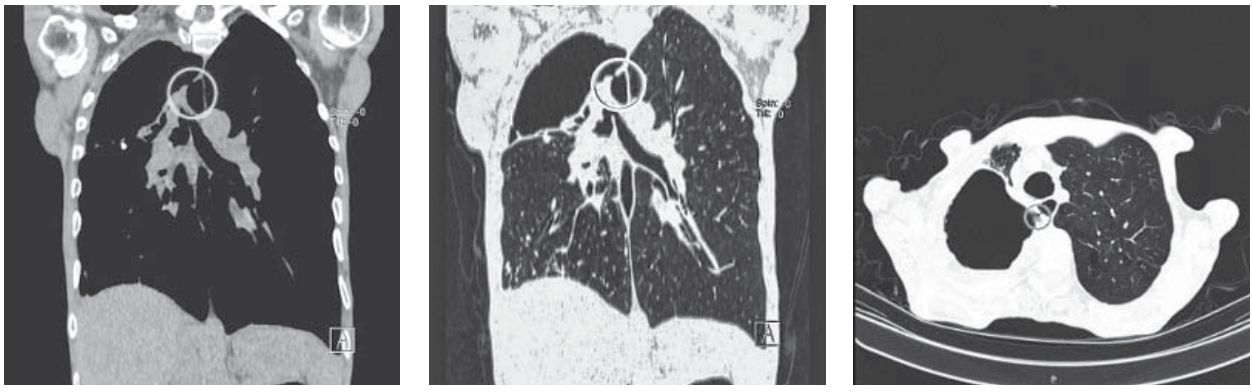

Fig. 6. Esophageal-pulmonary fistula on the right on the Chest CT

The small size of the esophageal-pulmonary fistula (1.5 mm) indicates the timely detection of the condition. According to the literature [1, 7, 8, 12], if esophago-pleural and esophago-bronchial fistulas are detected in a timely manner, the use of antibiotics, AMBT, and tube feeding (nasogastric tube) is often sufficient, eliminating the need for surgical intervention. In the presented case, since the patient is currently undergoing palliative treatment without AMBT, the prescription of feeding through a naso-

gastric tube and antibiotic therapy aims to prevent the progression of the esophageal-pulmonary fistula.

Therefore, in the case of a palliative patient with MDR-TB experiencing paroxysmal cough after eating, timely diagnosis of an esophageal-pulmonary fistula through the use of Chest CT is relevant. If such a fistula is diagnosed promptly, it is necessary to implement feeding through a nasogastric tube (parenteral feeding) and antibiotic therapy as a minimum course of action.

There is no conflict of interest.

Participation of authors: concept and design of the study – O.M. Raznatovska, V.I. Petrenko, O.S. Shalmin; collection of material – A.V. Fedorets and O.A. Svitlytska; processing of the material – O.M. Raznatovska, V.I. Petrenko, O.S. Shalmin, R.M. Yasynskyi; writing of the text and statistical data processing – O.M. Raznatovska, R.M. Yasynskyi; editing of the text – O.M. Raznatovska, V.I. Petrenko.

References

1. Behera G, Dutta P, Manjhi R, et al. Esophago-pleural fistula with pulmonary tuberculosis. *J Coll Physicians Surg Pak.* 2007 Apr;17(4):238-9. PMID: 17462189.
2. Dash M, Mohanty T, Patnaik J, et al. An unusual case of spontaneous esophagopleural fistula. *Lung India.* 2017 May-Jun;34(3):287-9. doi: 10.4103/0970-2113.205327.
3. Gupta KB, Manchanda M, Verma M. Tuberculous oesophago-pleural fistula. *J Indian Med Assoc.* 2011 Jul;109(7):504-5. PMID: 22315848.
4. Indiran V. Tuberculous bronchoesophageal fistula presenting as intractable cough. *Tuberk Toraks.* 2017 Mar;65(1):60-2. English. PMID: 28621250.
5. Kokuho N, Hayashi H, Matsuyama M, et al. [A case of pulmonary Mycobacterium abscessus disease complicated with esophago-pulmonary fistula causing repeated exacerbation]. *Nihon Kokyoku Gakkai Zasshi.* 2010 Sep;48(9):696-701. In Japanese. PMID: 20954373.
6. Laperuta P, Napolitano F, Vatrella A, et al. Post-pneumonectomy broncho-pleural fistula successfully closed by open-window thoracostomy associated with V.A.C. therapy. *Int J Surg.* 2014;12(Suppl 2):S17-S19. doi: 10.1016/j.ijsu.2014.08.390.
7. Liao LY, Wu H, Zhang NF, et al. [Bronchoesophageal fistula secondary to mediastinal lymph node tuberculosis: a case report and review of the literature]. *Zhonghua Jie He He Hu Xi Za Zhi.* 2013 Nov;36(11):829-932. Chinese. PMID: 24507394.
8. Madan K, Venkatnarayan K, Shalimar, et al. Successful medical management of tuberculous broncho-oesophageal fistula. *BMJ Case Rep.* 2014 Mar 11;2014:bcr2013202560. doi: 10.1136/bcr-2013-202560.
9. Mittal HG, Kaur P, Rangarajan S, et al. Tubercular Broncho-esophageal Fistula in an Adolescent Girl. *Indian J Pediatr.* 2022 Nov;89(11):1107-9. doi: 10.1007/s12098-022-04116-0.
10. Noh D, Park CK. The management of delayed post-pneumonectomy broncho-pleural fistula and esophago-pleural fistula. *Korean J Thorac Cardiovasc Surg.* 2016 Apr;49(2):138-40. doi: 10.5090/kjtc.2016.49.2.138.
11. Pache G, Thuerl C, Bley T, et al. Asymptomatic esophago-pleural fistula presenting 35 years after pneumonectomy for tuberculosis. *J Thorac Imaging.* 2005 Aug;20(3):223-5. doi: 10.1097/01.rti.0000155043.74533.79.
12. Sasaki M, Mochizuki H, Takahashi H. A bronchoesophageal fistula that developed shortly after the initiation of antituberculous chemotherapy. *Intern Med.* 2013;52(7):795-9. doi: 10.2169/internalmedicine.52.9191.
13. Sidhu KK, Seyfi D, Lau NS, et al. The rare case of oesophago-pericardial fistula secondary to pulmonary tuberculosis. *J Surg Case Rep.* 2022 Sep 24;2022(9):rjac422. doi: 10.1093/jscr/rjac422.

О.М. Разнатовська¹, В.І. Петренко², О.С. Шальмін¹, Р.М. Ясінський¹, А.В. Федорець¹, О.А. Світлицька¹

¹Запорізький державний медико-фармацевтичний університет

²Національний медичний університет імені О.О. Богомольця, Київ

Клінічний випадок туберкульозу з множинною лікарською стійкістю, ускладненого езофагопульмональною норицею, у паліативного пацієнта

Представлено власне спостереження перебігу туберкульозу з множинною лікарською стійкістю, ускладненого езофагопульмональною норицею, у паліативного пацієнта, який перебував на лікуванні у відділенні легеневого туберкульозу № 2 Запорізького регіонального фтизіопульмонологічного клінічного лікувально-діагностичного центру. Езофагопульмональну норицю виявлено в ділянці проведеної 8,5 року тому правобічної верхньочасткової лобектомії. На паліативному лікуванні пацієнт перебував майже 6 років до госпіталізації у стаціонар, коли була діагностована туберкульозна езофагопульмональна нориця. Пацієнта госпіталізовано у тяжкому стані, який значно погіршився протягом місяця. З огляду на те, що кашель та біль у грудній клітці були пов'язані з прийомом рідкої їжі, прийнято рішення провести комп'ютерну томографію органів грудної порожнини. Езофагопульмональна нориця мала вигляд лінійного повітряного дефекту стінки стравоходу розміром до 1,5 мм, який сполучався з каверною у верхній частці правої легені. Незначні розміри езофагопульмональної нориці вказують на вчасність її виявлення. Пацієнт перебуває на паліативному лікуванні, тому для запобігання прогресуванню езофагопульмональної нориці йому призначено годування крізь назогастральний зонд і антибіотикотерапію. За наявності у паліативного пацієнта з туберкульозом із множинною лікарською стійкістю нападаподібного кашлю, що виникає під час або відразу після їди, для вчасної діагностики езофагопульмональної нориці слід провести комп'ютерну томографію органів грудної порожнини. У разі виявлення такої нориці застосовують парентеральне годування і антибіотикотерапію.

Ключові слова: туберкульоз із множинною лікарською стійкістю, езофагопульмональна нориця, паліативна допомога.

Контактна інформація:

Разнатовська Олена Миколаївна, д. мед. н., проф., зав. кафедри фізіотерії і пульмонології

<https://orcid.org/0000-0003-2252-9063>

69035, м. Запоріжжя, просп. Маяковського, 26

E-mail: raznatovskaya@gmail.com

Стаття надійшла до редакції/Received 15.02.2023.

Стаття рекомендована до опублікування/Accepted 17.04.2023.

ДЛЯ ЦИТУВАННЯ

- Raznatovska OM, Petrenko VI, Shalmin OS, Yasinskyi RM, Fedorets AV, Svitlytska OA. A clinical case of multidrug-resistant tuberculosis complicated by esophageal-pulmonary fistula in a palliative patient. Туберкульоз, легеневі хвороби, ВІЛ-інфекція. 2023;2:56-62. doi: 10.30978/TB-2023-2-56.
- Raznatovska OM, Petrenko VI, Shalmin OS, Yasinskyi RM, Fedorets AV, Svitlytska OA. A clinical case of multidrug-resistant tuberculosis complicated by esophageal-pulmonary fistula in a palliative patient. Tuberculosis, Lung Diseases, HIV Infection (Ukraine). 2023;2:56-62. <http://doi.org/10.30978/TB-2023-2-56>.