



O.M. Raznatovska<sup>1</sup>, V.I. Petrenko<sup>2</sup>, O.S. Shalmin<sup>1</sup>,  
R.M. Yasinskyi<sup>1</sup>, A.V. Fedorets<sup>1</sup>, O.A. Svitlytska<sup>1</sup>

<sup>1</sup>Zaporizhzhia State Medical and Pharmaceutical University, Zaporizhzhia, Ukraine

<sup>2</sup>Bogomolets National Medical University, Kyiv, Ukraine

## Multifocal Tuberculosis with Pre-Extensive Drug Resistance (Clinical Case)

We present our own observation of the multifocal tuberculosis with pre-extensive drug resistance (pre-XDR-TB) development in a patient who was treated in the pulmonary tuberculosis department No. 2 of the Zaporizhzhia' regional phthisio-pulmonology clinical treatment and diagnostic center. Multifocal pre-XDR-TB developed in the patient 2.5 months after the initial diagnosis of destructive disseminated pulmonary tuberculosis. The patient was treated during 2 months with deforming arthrosis, which turned out to be tuberculosis of the left knee joint until the specified changes in the lungs were detected, which indicates its late diagnosis. The patient was not tested for HIV infection when tuberculosis was detected in the primary care, and after 2.5 months it was firstly found and accompanied by severe immunosuppression (CD4 lymphocytes count was 94 cells). This fact also indicates a late diagnosis of HIV infection. As a result of untimely diagnosis and treatment of disseminated pulmonary tuberculosis in the pre-XDR-TB patient with combined HIV infection, there was a rapid generalization of a specific process with the development of multifocal tuberculosis involving not only the bronchopulmonary system, but also the left eye (focal chorioretinitis), the heart (exudative pericarditis), brain (meningoencephalitis) and the left knee joint. The presented clinical case also shows the irresponsibility of the patient to his healthy and the poor work of the family doctor in explaining to the patient the importance of timely tuberculosis treatment. Thus, in the described clinical case, a late-diagnosed HIV infection with severe immunosuppression may have been the trigger for the development of multifocal tuberculosis with extensive drug resistance in the patient and untimely treatment of disseminated pulmonary tuberculosis led to rapid generalization of the specific process. More responsible work of family doctors with tuberculosis patients is also necessary. Therefore, timely diagnosis of multifocal tuberculosis and the earliest appointment of antimycobacterial therapy will allow not only to achieve positive results in treatment, but also to prevent the complications' development.

### Keywords

Multifocal tuberculosis, pre-extensive drug resistant tuberculosis.

Multifocal tuberculosis is tuberculosis, which is characterized by the presence of foci of specific inflammation in different organs at the same time (at least 2 extrapulmonary localizations, both with and without lung lesions) [1, 5, 6, 10]. Multifocal tuberculosis is rare, and the involvement of other organs and systems in the process adds symptoms that significantly veil the clinical manifestation, making diagnostics more difficult [2, 3, 11]. Therefore, the difficulties of diagnosis, considering other diseases, can lead to a delay in the timely diagnosis of multifocal tuberculosis [4, 6].

J.A. Al-Tawfiq described clinical cases of multifocal tuberculosis in 3 patients in his study [6]. Thus, in the first case, the patient had simultaneous tuberculosis lesion of the lungs, lumbar muscle, and vertebral bodies. In the second case, there was simultaneous lesion of the brain, mediastinal, and retroperitoneal lymph nodes by a specific process. In the third case, there were lesions, lymphadenopathy, and colon lesions that mimicked cancer metastases. Diagnosis of extrapulmonary forms of tuberculosis was made by histological examination of biopsy material of the affected organ. Timely appointment

of antimycobacterial therapy (AMBT) made it possible to obtain positive results of treatment.

A. Rezgui et al. in a retrospective analysis [10] described the features of the course of multifocal multifocal tuberculosis in 10 patients. The authors concluded that a timely diagnosis of such a specific process and a timely appointment of AMBT allow these patients to achieve positive results in treatment and prevent the development of complications.

C. Wang et al. [11] described a clinical case of their own observation of multifocal tuberculosis with simultaneous specific damage of the intestines, lymph nodes, bones, and soft tissues adjacent to the Th7–8 vertebrae. The authors indicated that the patient had no classical manifestations of tuberculosis, and the process mimicked a metastatic systemic malignant neoplasm. To make a diagnosis of tuberculosis, the authors used a diagnostic complex, including histological examination of biopsy material from the affected organs. The researchers also point out the relevance of timely diagnosis of multifocal tuberculosis and the earliest appointment of AMBT.

R. James et al. [8] described a clinical case of multifocal tuberculosis in a 50-year-old patient with simultaneous lesions of the lungs, genitourinary system, and lymph nodes. At the same time, this process initially simulated kidney failure. AMBT was added to the treatment, which gave a good response to treatment.

After analyzing of 20 clinical cases over 7 years, L. Ali Chaudhry and S. Al-Solaiman [5] established that multifocal tuberculosis was observed both in immunocompetent individuals and in immunocompromised individuals, including those infected with HIV. The authors found that AMBT alone was not always; there was surgical intervention necessity in some cases.

P. Kumar et al. [9] described a case of serpiginoid choroiditis in a patient with isolated tuberculosis of the spleen. The authors emphasize the connection of such extrapulmonary foci and the difficulty of diagnosis. Therefore, a thorough examination to rule out primary choroiditis was suggested in the routine examination protocol, and it was recommended to use complex treatment (AMBT + corticosteroids) for the treatment of tuberculous choroiditis in order to preserve the patient's vision [7, 9].

Thus, multifocal tuberculosis is a rare disease that is manifested by a completely different combination of simultaneous lesion of organs and systems by a specific process. In all the clinical cases described in the literature, drug-susceptible tuberculosis occurred, and the development of multifocal tuberculosis was observed both in immunocompetent and in immunocompromised individuals.

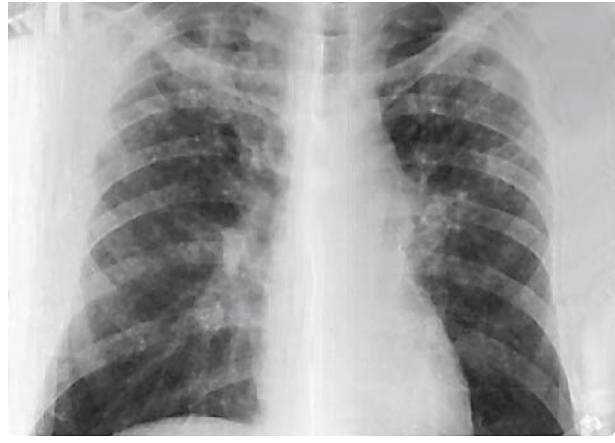


Fig. 1. Chest X-ray from 24.08.2022

Focal dissemination is determined in all lung fields, which merges in some areas. There is destruction up to 2.5 cm in diameter in the upper lobes of both lungs with infiltrated walls. The roots of the lungs are deformed, pulled up.

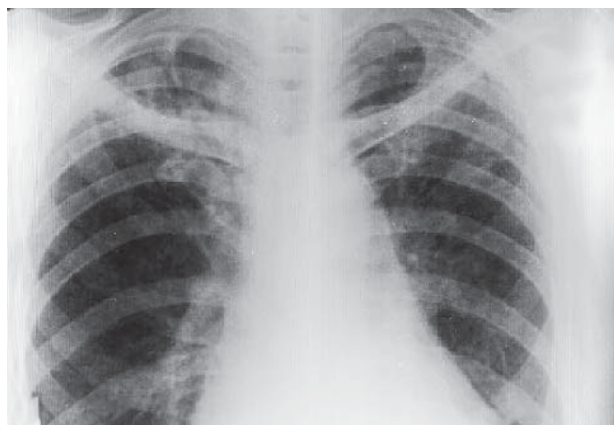
All researchers point to the relevance of early and timely diagnosis and treatment of multifocal tuberculosis, which is the key to effective treatment. We did not find in the available literary sources described clinical cases of multifocal tuberculosis in patients with pre-XDR-TB, which highlights the relevance of this research.

**Objective** — our own observation of the multifocal tuberculosis with pre-XDR-TB development in a patient who was treated in the Pulmonary Tuberculosis Department No. 2 of the Zaporizhzhia Regional Phthisio-pulmonology Clinical Treatment and Diagnostic Center.

#### Clinical Case

*Patient B.*, 46 years old, did not suffer from tuberculosis before. He noted a worsening of his condition since June 2022 when pain, swelling, and dysfunction of the left knee joint appeared. He received treatment of deforming arthrosis without effect. Since August 2022, he has experienced general weakness, loss of body weight, and an increase in body temperature up to 40 °C. During the examination with his family doctor, the patient was diagnosed with disseminated pulmonary tuberculosis with destruction visible on the chest X-ray. (Fig. 1). He was then referred for consultation with a phthisiologist. However, the patient did not believe the diagnosis and did not consult at a phthisiologist.

In November 2022, the general condition of the patient significantly worsened. Complaints of severe headache, nausea with periodic vomiting, heart pain, blurred vision and sensitivity to light in the left eye were added to the existing complaints from August. Therefore he came to a phthisiologist.



**Fig. 2. Chest X-ray from 10.11.2022**

The lungs are spread out, unevenly pneumatized due to focal dissemination, that merged in the upper lobes. Focal shadows are defined, and some of them have a heterogeneous structure due to destruction up to 2.5 cm in diameter, there is fibrosis. The roots are structural. The shadow of the heart is expanded, triangular in shape.

Thus, after 2.5 months, negative X-ray dynamics (Fig. 2) due to the expansion of the heart's shadow was determined on the Chest X-ray.

The patient underwent a bronchological examination, ulcerative tuberculosis of the larynx and infiltrative tuberculosis of B2 on the right side were diagnosed. The molecular genetic test (MG) for mycobacterium tuberculosis (MBT) was positive, resistance to rifampicin (Rif)<sup>+</sup> was detected, the genotypic drug sensitivity test (gDST) revealed resistance to isoniazid (H), levofloxacin (Lfx) and moxifloxacin (Mfx) in the bronchoalveolar lavage (BAL). MBT<sup>+</sup> were detected in the sputum also by Zhiehl–Neelsen test (acid fast bacilli (AFB) were detected).

In December, a culture (C) of MBT was obtained, resistance of MBT to drugs of the 1<sup>st</sup> line (H, rifampicin (R), ethambutol (E)) and 2<sup>nd</sup> line (LfxMfx) in phenotypic DST (phDST) was found. Drug sensitivity (resistance–) of MBT has been detected to such antimycobacterial drugs as amikacin (Am),

bedaquiline (Bdq), linezolid (Lzd), clofazimine (Cfz) and delamanid (Dlm).

The result of a rapid test for viral hepatitis C (HCV) is negative.

The result of a blood test for HBsAg is negative.

The result of a rapid HIV test is negative.

The result of blood analysis for CD4 lymphocytes – 94 cells (15.8 %).

Conclusion of an infectious disease specialist: HIV infection (B 20.0), IV clinical stage.

The blood glucose level is 4.93 mmol/l.

The results of blood tests in dynamic are presented in Tables 1 and 2.

Spirography: ventilatory insufficiency of the III degree.

Electrocardiogram (ECG) conclusion: The voltage is sufficient (reduced in standard leads). The rhythm is atrial fibrillation, heart rate 162/min. Heart electrical axis (HEA) is not deviated, signs of left ventricular myocardial hypertrophy. Diffuse changes in the myocardium, QTcF = 467 msec.

Ultrasound examination (UE): There are ultrasound signs of hydropericardium (echonegative pericardial space at the apex of 23 mm during diastole), diffuse changes in the liver and pancreas.

The therapist's conclusion: Metabolic cardiopathy with heart rhythm disturbances (atrial flutter). Exudative pericarditis. Pulmonary insufficiency (PI) of the III degree. Heart failure (HF) of I stage.

Considering the patient's complaints of severe headache, nausea with periodic vomiting, decreased vision in the left eye, a decision was made to perform magnetic resonance imaging (MRI) of the brain with intravenous contrast enhancement (Fig. 3).

The result the cerebrospinal fluid analysis: protein – 0.33 g/l, Nonn-Appelt reaction (+), Pandy's reaction (+++), cytosis – 10 cells: lymphocytes – 70 %, neutrophils – 30 %. Atypical cells, MTB, cryptococci, toxoplasma were not detected. Glucose – 3.57 mmol/l, chlorides – 107.5 mmol/l.

**Table 1. Blood analysis in dynamics in the clinical case**

| Date       | Blood analysis indicators |   |   |  |                     |                      |                        |                       |                     |                          |  |
|------------|---------------------------|---|---|--|---------------------|----------------------|------------------------|-----------------------|---------------------|--------------------------|--|
|            | Hb, g/l<br>(RV = 110–160) | Er, × 10 <sup>12</sup> /l<br>(RV = 3.9–5.3) | WBC, × 10 <sup>9</sup> /l<br>(RV = 4–9) | pl, × 10 <sup>9</sup> /l<br>(RV = 150–390) | Ef, %<br>(RV = 2–4) | b/n, %<br>(RV = 1–4) | s/n, %<br>(RV = 52–72) | Lf, %<br>(RV = 19–37) | m, %<br>(RV = 3–10) | ESR, mm/h<br>(RV = 1–10) |  |
| 11.11.2022 | 117                       | 3.77  | 6.9                                     | 278  | 0                   | 24                   | 62                     | 4                     | 10                  | 45                       |  |
| 20.11.2022 | 128                       | 4.01  | 11                                      | 362  | 0                   | 7                    | 75                     | 12                    | 6                   | 12                       |  |
| 09.12.2022 | 128                       | 4.04  | 12.8                                    | 269  | 0                   | 19                   | 67                     | 9                     | 5                   | 18                       |  |

Note. RV — Reference values; Hb — hemoglobin; Er — erythrocytes; WBC — leukocytes; pl — platelets; Ef — eosinophils; b/n — band neutrophils; s/n — segmented neutrophils; Lf — lymphocytes; m — monocytes; ESR — erythrocyte sedimentation rate.

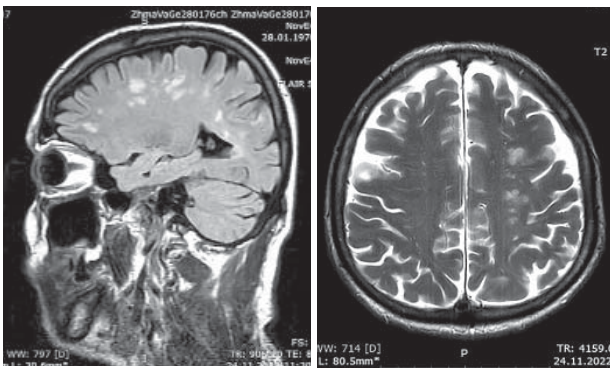


Fig. 3. MRI of the brain with intravenous contrast enhancement

MRI picture of multiple cortical, subcortical and periventricular foci in the left hemisphere of the brain, of round and ovoid in shape from 23 mm to 6—7 mm, some of them with slight perifocal edema, most of them with diffusion limitation, with small areas of pathological signal in the adjacent soft shell. Considering the anamnesis, neurotuberculosis was likely to be manifested.

The result of MG test of cerebrospinal fluid for MBT was negative.

Neuropathologist's conclusion: tuberculous meningo-encephalitis.

Considering complaints of blurred vision and sensitivity to light from the left eye, the patient was examined by an ophthalmologist. Ophthalmologist's conclusion: tuberculosis of the left eye (focal chorioretinitis).

Considering the patient's complaints such as pain, swelling, and dysfunction of the left knee joint, an ultrasound and X-ray of the left knee joint were performed in 2 projections (Fig. 4).

The conclusion of the UE of the left knee joint: there is a pathological component of medium granularity, increased echogenicity, mushroom-shaped, which has a connection with the joint cavity in the lower-medial turn of the knee joint in the soft tissues.

Conclusion of the orthopedist: ET of the left knee joint (synovitis).

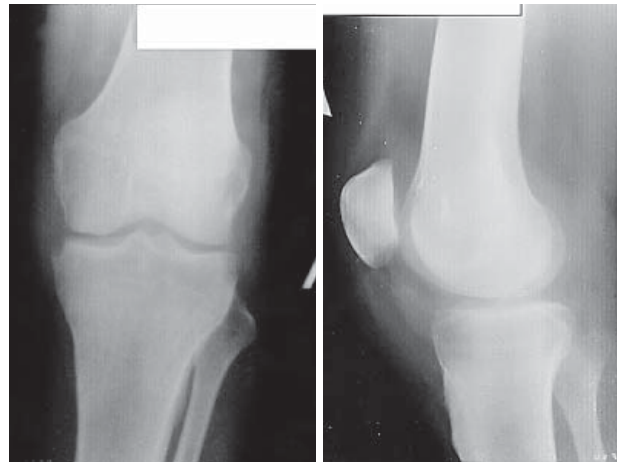


Fig. 4. X-ray of the left knee joint in 2 projections

The joint surfaces are deformed, the joint space is unevenly narrowed, there are subchondral sclerosis, marginal bone growths.

Thus, during the follow-up examination in November 2022, multifocal tuberculosis with multiple drug resistance was already diagnosed and HIV infection was detected for the first time.

Considering these results, next diagnosis was made: Pre-XDR-TB (11.2022) disseminated of lung. Destruction+, MBT+, MG+, Rif+, gDST (H, Lfx, Mfx), AFB+, C+, phDST-I (H, R, E), phDST-II (Lfx, Mfx). Resistance– (Am, Bdq, Lzd, Cfz, Dlm). Extrapulmonary tuberculosis (ET) ulcerative tuberculosis of larynx, infiltrative tuberculosis of B2 on the right; focal chorioretinitis of the left eye; exudative pericarditis; meningoencephalitis; tuberculosis of left knee joint. Histology 0 (new case of TB). PI of the III degree. HF of I stage. B 20.0, IV clinical stage.

Complex treatment was prescribed in the hospital:

- a course of AMBT according to the scheme of an individual treatment regimen (2 months: Bdq, Lzd, Cfz, cycloserine (Cs), meropenem (Mpn), later: Bdq Lzd Cfz Cs Dlm), a port system was implanted into the right lung (Fig. 5);

Table 2. Biochemical analysis of blood in dynamics in the clinical case

| Date       | Biochemical analysis of blood indicators |                              |                                    |                                    |                         |                                     |                                |                               |                               |                                 |                              |                               |                                |                                 |
|------------|--|------------------------------|------------------------------------|------------------------------------|-------------------------|-------------------------------------|--------------------------------|-------------------------------|-------------------------------|---------------------------------|------------------------------|-------------------------------|--------------------------------|---------------------------------|
|            | Bitirubin, mmol/l<br>(RV = up to 21)     | ThT, units<br>(RV = up to 4) | AlAt, mmol/l/h<br>(RV = 0.16–0.44) | AsAt, mmol/l/h<br>(RV = 0.91–1.75) | TP, g/l<br>(RV = 64–85) | Creatinine, μmol/l<br>(RV = 62–115) | Urea, mmol/l<br>(RV = 2.5–8.3) | RUN, mmol/l<br>(RV = 12.5–25) | α-amylase, g/lh<br>(RV = 2–4) | Potassium, mmol/l<br>(RV = 2–4) | Sodium, mmol/l<br>(RV = 2–4) | Calcium, mmol/l<br>(RV = 2–4) | Chlorine, mmol/l<br>(RV = 2–4) | Magnesium, mmol/l<br>(RV = 2–4) |
| 11.11.2022 | 11.5                                     | 21.53                        | 0.31                               | 0.24                               | 83.3                    | 137.5                               | 6.86                           | 3.2                           | 10.6                          | 4.08                            | 144.6                        | 1.48                          | 107.4                          | 0.82                            |
| 28.11.2022 | 11.9                                     | 16.8                         | 1.45                               | 0.75                               | 62                      | 159.7                               | 8.47                           | 3.95                          | 14.2                          | 4.28                            | 136.3                        | 1.56                          | 109.9                          | 0.95                            |
| 05.12.2022 | 9.6                                      | 6.2                          | 0.66                               | 0.48                               | 58.6                    | 118.5                               | 10.93                          | 5.09                          | 13.8                          | 4.93                            | 139.5                        | 1.36                          | 108.7                          | 0.75                            |

Note. RV — Reference values; ThT — thymol test; AlAt — alanine aminotransferase; AsAt — aspartate aminotransferase; TP — total protein; RUN — residual urea nitrogen.

- treatment of arrhythmia recommended by the therapist;
- antiretroviral therapy, prevention and treatment of opportunistic infections.

Thereby, multifocal pre-XDR-TB developed in the patient 2.5 months after the initial diagnosis of destructive disseminated pulmonary tuberculosis. The clinical case represents the difficulty of timely diagnosis of extrapulmonary forms of tuberculosis, which confirms data from literary sources [5, 6, 9–11]. It should be noted the patient was treated for 2 months with deforming arthrosis, which turned out to be tuberculosis of the left knee joint, indicating its late diagnosis. The patient was not tested for HIV infection in August, and in November, it was firstly found and accompanied by severe immunosuppression (CD4 lymphocytes count was 94 cells), which may have become the trigger for the development of multifocal tuberculosis. This fact also indicates a late diagnosis of HIV infection. As a result of untimely diagnosis and treatment of disseminated pulmonary tuberculosis in the pre-XDR-TB patient with combined HIV infection, there was a rapid generalization of a specific process with the development of multifocal tuberculosis involving not only the bronchopulmonary system, but also the left eye (focal chorioretinitis), the heart (exudative pericarditis), brain (meningoencephalitis) and the left knee joint. Therefore, timely diagnosis and treatment of disseminated pulmonary tuberculosis and HIV infection would prevent the development of generalization of the specific process [4, 5]. The presented clinical case also shows the irresponsibility of the patient towards his healthy and the poor work of the family doctor in

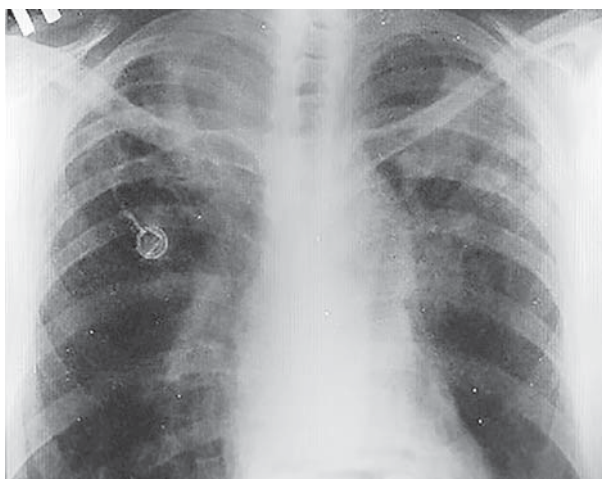


Fig. 5. Chest X-ray (a port system was implanted into the right lung)

explaining to the patient the importance of timely tuberculosis treatment.

### Conclusions

Thus, in the described clinical case, a late-diagnosed HIV infection with severe immunosuppression may have been the trigger for the development of multifocal tuberculosis with extensive drug resistance in the patient and untimely treatment of disseminated pulmonary tuberculosis led to rapid generalization of the specific process. More responsible work of family doctors with tuberculosis patients is also necessary. Therefore, timely diagnosis of multifocal tuberculosis and the earliest appointment of antimycobacterial therapy will allow not only to achieve positive results in treatment, but also to prevent the complications' development.

#### There is no conflict of interest.

**Participation of the authors:** research concept and design – O.M. Raznatovska, V.I. Petrenko, O.S. Shalmin; collection of material – A.V. Fedorets, O.A. Svitlytska; data analysis – O.M. Raznatovska, V.I. Petrenko, O.S. Shalmin; writing the text and statistical data processing – O.M. Raznatovska, R.M. Yasynskiy; editing of the text – O.M. Raznatovska, V.I. Petrenko.

### References

1. Петренко ВІ, Долинська МГ, Разнатовська ОМ. Позалегеновий і міліарний туберкульоз у хворих на коінфекцію туберкульоз/ВІЛ. Частина 1. Туберкульоз, легеневі хвороби, ВІЛ-інфекція. 2018;1(32):90-100.
2. Петренко ВІ, Долинська МГ, Разнатовська ОМ. Позалегеновий і міліарний туберкульоз у хворих на коінфекцію туберкульоз/ВІЛ. Частина 2. Туберкульоз, легеневі хвороби, ВІЛ-інфекція. 2018;2(33):61-73.
3. Петренко ВІ, Долинська МГ, Разнатовська ОМ. Позалегеновий і міліарний туберкульоз у хворих на коінфекцію туберкульоз/ВІЛ. Частина 3. Туберкульоз, легеневі хвороби, ВІЛ-інфекція. 2018;3(34):87-97.
4. Петренко ВІ, Долинська МГ, Разнатовська ОМ. Позалегеновий і міліарний туберкульоз у хворих на коінфекцію туберкульоз/ВІЛ. Частина 5. Туберкульоз, легеневі хвороби, ВІЛ-інфекція. 2019;1(36):86-99.
5. Ali Chaudhry L, Al-Solaiman S. Multifocal tuberculosis: Many faces of an old menace. *Int J Mycobacteriol.* 2013 Mar;2(1):58-69. <https://www.sciencedirect.com/science/article/pii/S2212553113000046>.
6. Al-Tawfiq JA. Multifocal systemic tuberculosis: the many faces of an old nemesis. *Med Sci Monit.* 2007 Apr;13(4):CS56-60. PMID: 17392657.
7. Belmonte Grau M, Acebes García M, Jacobo González Guijarro J. Multifocal choroiditis and choroidal tuberculoma: Signs of presumed ocular tuberculosis. *Eur J Ophthalmol.* 2023 Jan;33(1):NP15-NP18. doi: 10.1177/11206721211039938.
8. James R, Avudaiappan S, et al. Multifocal tuberculosis. *J Assoc Physicians India.* 2016 Sep;64(9):83-4. PMID: 27762524.

9. Kumar P, Kakkar P, Ravani R, et al. Splenic tuberculosis and multifocal serpiginoid choroiditis. *Int Ophthalmol*. 2018 Oct;38(5):2191-4. doi: 10.1007/s10792-017-0689-x.
10. Rezgui A, Fredj FB, Mzabi A, et al. Tuberculose multifocale chez les immunocompétents [Multifocal tuberculosis in immunocompetent patients]. *Pan Afr Med J*. 2016 May 4;24:13. French. doi: 10.11604/pamj.2016.24.13.6030.
11. Wang C, Luan Y, Liu S, et al. Multifocal tuberculosis simulating a cancer-a case report. *BMC Infect Dis*. 2020 Jul 10;20(1):495. doi: 10.1186/s12879-020-05209-x.

О.М. Разнатовська<sup>1</sup>, В.І. Петренко<sup>2</sup>, О.С. Шальмін<sup>1</sup>, Р.М. Ясінський<sup>1</sup>,  
А.В. Федорець<sup>1</sup>, О.А. Світлицька<sup>1</sup>

<sup>1</sup>Запорізький державний медико-фармацевтичний університет, Запоріжжя

<sup>2</sup>Національний медичний університет імені О.О. Богомольця, Київ

## Мультифокальний туберкульоз з пре-широкою лікарською стійкістю (клінічний випадок)

Представлено власне спостереження розвитку мультифокального туберкульозу з пре-широкою лікарською стійкістю (пре-ШЛС-ТБ) у пацієнта віком 46 років, який перебував на лікуванні у відділенні легеневого туберкульозу № 2 Запорізького регіонального фтизіопульмонологічного клінічного лікувально-діагностичного центру. У пацієнта за 2,5 міс від початкової діагностики деструктивного дисемінованого туберкульозу легень розвинувся мультифокальний пре-ШЛС-ТБ. До виявлення зазначених змін у легенях пацієнт 2 міс лікував артроз, що деформує, який виявився туберкульозом лівого колінного суглоба, що вказує на пізню його діагностику. Під час виявлення туберкульозу на первинній ланці пацієнту не проводили тесту на ВІЛ-інфекцію. Через 2,5 міс виявлено її наявність. ВІЛ-інфекція супроводжувалася тяжкою імуносупресією (CD4-лімфоцити – 94 клітини). Це також свідчить про пізню діагностику ВІЛ-інфекції. Через несвоєчасну діагностику та лікування дисемінованого туберкульозу легень у пацієнта з пре-ШЛС-ТБ на тлі ВІЛ-інфекції розвинувся мультифокальний туберкульоз із залученням у процес не лише бронхолегеневої системи, а і лівого ока (вогнищевий хоріоретиніт), серця (ексудативний перикардит), головного мозку (менінгоенцефаліт), лівого колінного суглоба. Представлений клінічний випадок також свідчить про безвідповідальне ставлення пацієнта до здоров'я та погану роботу сімейного лікаря щодо пояснення пацієнту актуальності вчасного виявлення та лікування туберкульозу. В описаному клінічному випадку пусковим механізмом розвитку мультифокального туберкульозу з пре-ШЛС-ТБ у пацієнта, можливо, стала недиагностована вчасно ВІЛ-інфекція з тяжкою імуносупресією. Є потреба у відповідальнішій роботі сімейних лікарів із хворими на туберкульоз. Вчасна діагностика мультифокального туберкульозу з якомога ранішим призначенням антимікобактеріальної терапії дасть змогу не лише досягти позитивних результатів лікування, а і запобігти розвитку ускладнень.

**Ключові слова:** мультифокальний туберкульоз, туберкульоз із множинною лікарською стійкістю.

### Контактна інформація:

Разнатовська Олена Миколаївна, д. мед. н., проф., зав. кафедри фтизіатрії і пульмонології  
<https://orcid.org/0000-0003-2252-9063>  
 69035, м. Запоріжжя, просп. Маяковського, 26  
 E-mail: [raznatovskaya@gmail.com](mailto:raznatovskaya@gmail.com)

Стаття надійшла до редакції/Received 20.02.2023.

Стаття рекомендована до опублікування/Accepted 14.04.2023.

### ДЛЯ ЦИТУВАННЯ

- Raznatovska OM, Petrenko VI, Shalmin OS, Yasinskyi RM, Fedorets AV, Svitlytska OA. Multifocal Tuberculosis with Pre-Extensive Drug Resistance (Clinical Case). *Туберкульоз, легеневі хвороби, ВІЛ-інфекція*. 2023;3:54-59. doi: 10.30978/TB-2023-3-54.
- Raznatovska OM, Petrenko VI, Shalmin OS, Yasinskyi RM, Fedorets AV, Svitlytska OA. Multifocal Tuberculosis with Pre-Extensive Drug Resistance (Clinical Case). *Tuberculosis, Lung Diseases, HIV Infection (Ukraine)*. 2023;3:54-59. <http://doi.org/10.30978/TB-2023-3-54>.