

ISSN 2226-2008

ОДЕСЬКИЙ НАЦІОНАЛЬНИЙ МЕДИЧНИЙ УНІВЕРСИТЕТ

# ОДЕСЬКИЙ МЕДИЧНИЙ ЖУРНАЛ

№ 1 (192)



Видавничий дім  
«Гельветика»  
2025

## **ПИТАННЯ ГІГІЄНИ ТА ЕКОЛОГІЇ**

- O. S. Bilous, N. D. Kozak, V. V. Babienko, S. V. Bilous, N. V. Merezhkina  
ASSESSING THE POTENTIAL HEALTH RISKS OF PESTICIDES USED FOR BERRY  
AND MELON CROPS IN CONTAMINATION OF GROUND AND SURFACE WATERS.....75

## **ФАРМАКОЛОГІЯ І ФАРМАЦІЯ**

- A. A. Safonov, A. S. Gotsulya, R. O. Shcherbina, O. I. Panasenko  
ANALYSIS OF THE EFFECT OF SODIUM 2-((4-AMINO-5-(THIOPHEN-2-YLMETHYL)-4H-1,2,4-  
TRIAZOL-3-YL)THIO)ACETATE HIGH DOSES ON BRAIN TISSUE.....80
- I. В. Литвинчук, О. В. Нікітін, Г. В. Поперечний, В. О. Гельмбольдт  
ПОХІДНІ 2-, 3-, 4-ПІРИДИНОЦТОВИХ КИСЛОТ ЯК ПОТЕНЦІЙНІ КОМПОНЕНТИ  
ФТОРВМІСНИХ АНТИКАРІЄСНИХ АГЕНТІВ.....84

UDC 615.31:547.792].015.34:612.83.014.2

DOI <https://doi.org/10.32782/2226-2008-2025-1-15>

A. A. Safonov <https://orcid.org/0000-0003-2861-1826>  
A. S. Gotsulya <https://orcid.org/0000-0001-9696-221X>  
R. O. Shcherbyna <https://orcid.org/0000-0002-9742-0284>  
O. I. Panasenko <https://orcid.org/0000-0002-6102-3455>

## ANALYSIS OF THE EFFECT OF SODIUM 2-((4-AMINO-5-(THIOPHEN-2-YLMETHYL)-4H-1,2,4-TRIAZOL-3-YL)THIO) ACETATE HIGH DOSES ON BRAIN TISSUE

Zaporizhzhia State Medical and Pharmaceutical University, Zaporizhzhia, Ukraine

UDC 615.31:547.792].015.34:612.83.014.2

A. A. Safonov, A. S. Gotsulya, R. O. Shcherbyna, O. I. Panasenko

ANALYSIS OF THE EFFECT OF SODIUM 2-((4-AMINO-5-(THIOPHEN-2-YLMETHYL)-4H-1,2,4-TRIAZOL-3-YL)THIO)  
ACETATE HIGH DOSES ON BRAIN TISSUE

*Zaporizhzhia State Medical and Pharmaceutical University, Zaporizhzhia, Ukraine*

The aim of the study is to analyze the effect of high doses of sodium 2-((4-amino-5-(thiophen-2-ylmethyl)-4H-1,2,4-triazol-3-yl)thio)acetate (ASP) on brain tissue.

**Material and methods.** The effect of ASP high doses (1000 mg/kg and 5000 mg/kg) was studied on white outbred rats. The substance was administered intragastrically dissolved in purified water using a special metal probe. The brain tissue was fixed in a 10% formaldehyde solution for subsequent histological examination, dehydrated in alcohols of increasing concentrations, and embedded in paraffin.

**Results.** Analyzing the effect of different doses of ASP on brain tissue, it can be concluded that at 1000 mg/kg, vacuolar cytoplasmic degeneration is detected in many neurons and cells without nuclei are observed. This is indicated by histological evidence of selective neuronal death. At the same time, the capillary system is preserved. Partial chromatolysis of Purkinje cells is observed in the cerebellum, the layering is preserved. Against the background of moderate interstitial edema of the brain selective neuronal death with the formation of collapsed (eosinophilic) neurons is observed at 5000 mg/kg.

A dose 10 times higher than effective dose (1000 mg/kg) leads to changes in the histological structure of organ tissues. The maximum argued dose of the fourth toxicity class of 5000 mg/kg also causes more serious changes in the structure of organ tissues.

**Keywords:** 1,2,4-triazole, brain tissue, toxic effect.

УДК 615.31:547.792].015.34:612.83.014.2

А. А. Сафонов, А. С. Гоцуля, Р. О. Щербина, О. І. Панасенко

АНАЛІЗ ВПЛИВУ ВИСОКИХ ДОЗ 2-((4-АМІНО-5-(ТІОФЕН-2-ІЛМЕТИЛ)-4H-1,2,4-ТРИАЗОЛ-3-ІЛ)ТІО)  
АЦЕТАТУ НА ТКАНИНУ МОЗКУ

*Запорізький державний медико-фармацевтичний університет, Запоріжжя, Україна*

Стаття присвячена дослідженню тканин мозку у разі введення високих доз (1000 мг/кг і 5000 мг/кг) 2-((4-аміно-5-(тіофен-2-ілметил)-4H-1,2,4-триазол-3-іл)тіо)ацетату перорально за допомогою зонду. Доза в 10 разів більша за ефективну дозу (100 мг/кг – шури) – 1000 мг/кг уже призводить до змін гістологічної структури тканин органів. Максимальна аргументована доза четвертого класу токсичності 5000 мг/кг також викликає серйозніші зміни у структурі тканин органів.

Таким чином, наше дослідження дало докази зміненої гістологічної архітектури тканини мозку.

**Ключові слова:** 1,2,4-триазол, мозкова тканина, токсична дія.


**Introduction.** The study of the toxic effect of compounds on the tissues of internal organs is one of the main tasks in determining the toxicity of already known or newly synthesized compounds. It enables scientists to identify the target organs that have the greatest impact of the compounds being studied. One of the large lists of organs for research is the brain. Analyzing brain tissue after taking high doses of drugs can show and detect structural changes in the organ and subsequently prevent them.

In recent years, 1,2,4-triazole compounds have gained wide and promising development [1–4]. Scientists have already found substances with antimicrobial, antifungal, hepatoprotective, antiradical, antipyretic activities [5–8]. Sodium 2-((4-amino-5-(thiophen-2-ylmethyl)-4H-1,2,4-triazol-3-yl)thio)acetate (ASP) is a new generation compound that can be used as an actoprotective tool [9], and synthesized by Ukrainian scientists.

Thus, the aim of the study is to analyze the effect of toxic doses of sodium 2-((4-amino-5-(thiophen-2-ylmethyl)-4H-1,2,4-triazol-3-yl)thio)acetate (ASP) on brain tissue. Brain tissue was selected as one of the objects in a comprehensive study of the toxic effects of the ASP substance. There is a large number of publications aimed at

© A. A. Safonov, A. S. Gotsulya, R. O. Shcherbyna et al., 2025

Стаття поширюється на умовах ліцензії



studying the effects of substances specifically on the brain [10; 11]. In the overall comprehensive study of high doses of the ASP substance, tissues of the heart, pulmonary system, spleen, gastrointestinal tract, liver, thymus, kidneys, and adrenal glands were also analyzed. Part of the research has already been published [12–14] due to the wide range of research.

**Material and methods.** Sodium 2-((4-amino-5-(thiophen-2-ylmethyl)-4H-1,2,4-triazol-3-yl)thio)acetate [9] was used as the research object at doses of 1000 mg/kg (the dose that caused a change in clinical indicators, namely respiratory rate, and 10 times greater than the dose used to study pharmacological activity) and 5000 mg/kg (maximum dose of the fourth class of toxicity). These doses do not cause the death of animals – they were chosen according to the recommendations for preclinical studies of the toxicity of medicinal products [15]. The substance was administered intragastrically dissolved in purified water using a special metal probe.

Analysis of the effect of ASP toxic doses was studied on white outbred rats aged 12 months. Care, maintenance and feeding of animals was carried out in standard conditions of a stable microclimate of the vivarium at the ZSMPhU (Ukraine) under conditions of 12-hour daylight. Feeding of laboratory animals was carried out on the basis of standardized balanced feed with free access to food and water, in conditions excluding the influence of stress factors. Rats were kept in standard conventional polycarbonate cages of size 610x435x215 mm, by 4 animals in each one. Every group included 4 animals to study 1 dose of the compound. A total of 9 animals were used. Male rats were used that were available and suitable for the experiment in terms of age and weight. [16]. All stages of the research were carried out in compliance with the Directive of the European Parliament and of the Council 2010/63/EU of 22 September 2010 “On the protection of animals used for scientific purposes” and based on the OECD guidelines (Approval of the ethics committee of ZSMPhU No. 5 of 05.09.2023) [17].

The brain tissue was fixed in a 10% formaldehyde solution for subsequent histological examination, dehydrated in alcohols of increasing concentrations, and embedded in paraffin colored by hematoxylin and eosin.

The analysis of micropreparations was conducted using a Granum light microscope, and microscopic images were captured with a Granum DSM 310 digital video camera.

**Result and Discussion.** The study began with a visual inspection and weighing of the analyzed organ of both control animals and experimental animals. The weight of the organ in the experimental group ranged from 1.28 to 1.46 g (Table 1).

Table 1

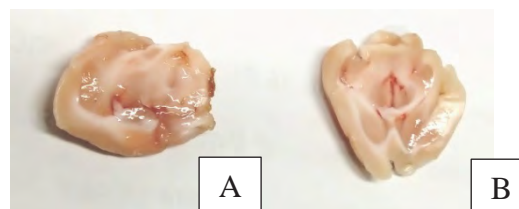
Weight measurements of rats

Rat brain weight (dose 1000 mg/kg)	Rat brain weight (dose 5000 mg/kg)
1.36±0.045	1.375±0.05

Macroscopically, the hemispheres are light gray, swollen, furrows and gyrations are not clearly visualized, the soft meninges are gray-white, with clearly contoured full-blooded vessels. Gray and white matters are clearly differen-

tiated in the section. In the white matter of the hemispheres and in the projection of the lateral ventricles, there are small hemorrhages throughout its area (Fig. 1) and full blood vessels, the brain tissue is soft, sticking to the knife blade.

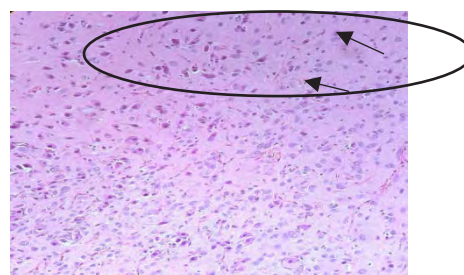
The brain of the control group of animals weighed 1.30 g. Macroscopically, the hemispheres were light gray in color, of dense elastic consistency, with clear visualization of furrows and gyrus, the soft meninges was gray-white, 0.1 mm thick, without the presence of blood vessels. The gray and white matter of homogeneous structure was clearly visualized in the section (Fig. 1).



**Fig. 1. The right cerebral hemisphere with hemorrhage loci in the lateral ventricle projection (A). Brain in sagittal section in the projection of the lateral ventricles (B)**

Analysis of the cerebellum and brainstem in the experimental animals and the control group revealed no macroscopic changes.

Histological analysis of the brain tissue of experimental animals (dose 1000 mg/kg) revealed the following changes: single neurons with basophilic cytoplasm and chromatolysis of nuclei, the branched system of appendages is preserved. Many neurons showed vacuolar cytoplasmic degeneration, separate groups of cells without nuclei (“shadow neurons”) pyknotically altered, basophilic (histological signs of selective neuronal death). Microglia has perineuronal and perivascular satellite formation. The capillary system is preserved, erythrocytes are detected in the capillary lumen (Fig. 2). Scientists [18] also studied the effect of high doses of organic compounds on brain tissue and noted the presence of similar pathologies.

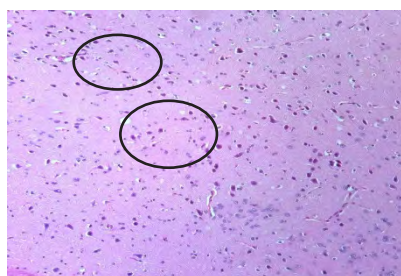


**Fig. 2. Chromatolysis of neurons with the formation of “shadow cells” (the upper part of the photo) (dose 1000 mg/kg). x400**

Microscopic analysis of experimental animals (dose 5000 mg/kg) revealed single neurons with eosinophilic cytoplasm and chromatolysis of nuclei. The branched system of appendages was partially preserved. In many neurons, vacuolar cytoplasmic dystrophy (more than 50%), separate groups of cells without nuclei, pyknotic, baso-

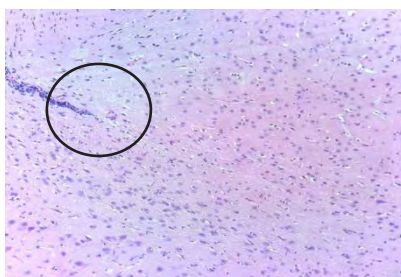


philic (histological signs of selective neuronal death) are detected. Loci of gliofibrosis, perineuronal and perivascular satellitosis are determined in microglia. The capillary system is preserved. Red blood cells are detected in the capillary lumen (Fig. 3).



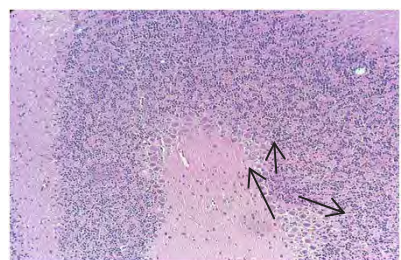
**Fig. 3. Selective neuronal death with the formation of collapsed (eosinophilic) neurons, against the background of moderate interstitial brain edema (dose 5000 mg/kg). x400**

Among the control group, the histoarchitectonics of the cortex has a typical structure. The histological layering of cortical structures is clearly defined. Neurons with a branched system of processes and nuclei (in single cells) vacuolar dystrophy is determined. Microglia is sufficient in its cellular structure, diffuse minimal lymphocytic infiltration of the tissue is determined. The capillary network is unchanged, erythrocytes are detected in the lumen (Fig. 4).



**Fig. 4. Typical structure of rat brain microglia (control group). x200**

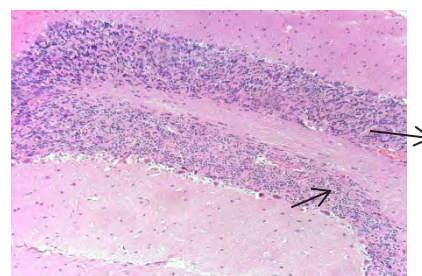
Analysis of the cerebellum among rats (dose 1000 mg/kg): the histological structure and layering of the cerebellum is preserved, the granular layer is clearly defined, pear-shaped neurons (Purkinje cells) are typical histological structure (Fig. 5).



**Fig. 5. Partial chromatolysis of Purkinje cells, layers preserved (dose 1000 mg/kg). x400**

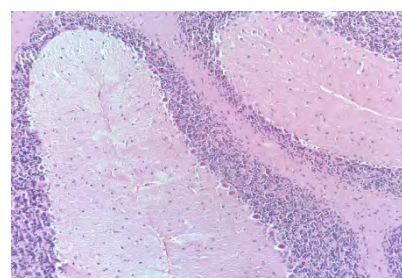
Analysis of the cerebellum among rats (dose 5000 mg/kg): the capillary system is preserved, and red blood cells are

detected in the capillary lumen. The histological structure and layering of the cerebellum are preserved, the granule layer is clearly defined, and Purkinje cells are of typical histological structure (Fig. 6). These changes can also be observed in brain lesions [19].



**Fig. 6. Purkinje cell precipitation and chromatolysis (5000 mg/kg dose). x400**

Microscopic analysis of the control group revealed that the histoarchitecture of the cerebellum has a typical structure, with a clear differentiation into gray and white matter (with a ratio 1:3). Neurons with a branched system of processes had typical structure (Fig. 7). The brainstem has a typical histological structure with sufficient distribution of microglial elements and visualization of conducting pathways with an ordered structure.



**Fig. 7. Typical stratification of the rat cerebellum (control group). x400**

Based on the obtained data of the histological examination and comparing with the studies of other scientists [20], it should be noted that the substance under study at a dose of 1000 mg/kg has a toxic effect on brain cells, but this effect is not as significant as at a higher dose of 5000 mg/kg. However, these doses do not lead to the death of animals.

**Conclusions.** Analyzing the effect of different doses of ASP on brain tissue, it can be concluded that at 1000 mg/kg, vacuolar cytoplasmic degeneration is detected in many neurons and cells without nuclei are observed. This is indicated by histological evidence of selective neuronal death. At the same time, the capillary system is preserved. Partial chromatolysis of Purkinje cells is observed in the cerebellum, the layering is preserved.

Against the background of moderate interstitial edema of the brain selective neuronal death with the formation of collapsed (eosinophilic) neurons is observed at 5000 mg/kg. There is a partial loss and chromatolysis of Purkinje cells in the cerebellum tissue.

The authors sum up that that high doses of an ASP drug have a negative effect on brain tissues and cause changes in cells. Also, based on previously conducted studies of the effect

of high doses of ASP on tissues of the heart, pulmonary system, spleen, gastrointestinal tract, liver, thymus, kidneys, and adrenal glands, as well as biochemical studies of blood serum [21], it can be concluded that high doses of ASP 1000 mg/kg and 5000 mg/kg are toxic for rats. The dose used to study the pharmacological activity (actoprotective and stress-protective activity) is 100 mg/kg. A dose 10 times higher – 1000 mg/kg already leads to changes in the histological structure of organ tissues. The maximum argued dose of the fourth toxicity class

of 5000 mg/kg also causes more serious changes in the structure of organ tissues. It should be noted that these high doses do not lead to the death of animals.

As a result, the present study provided evidence of altered histological architecture of the brain tissue. In this regard, it is not necessary to exaggerate the effective dose of the ASP substance.

**Conflict of interest:** The authors declare that there is no real, potential, or perceived conflict of interest for this article.

## BIBLIOGRAPHY

- Sameliuk Y, Kaplaushenko T, Al Zedan F. 1,2,4-triazole derivatives in medicine and pharmacy and application prospects. *Journal of Faculty of Pharmacy of Ankara University*. 2021; 45(3):598–614. <https://doi.org/10.33483/jfpau.885888>.
- Shcherbyna R. Microwave-assisted synthesis of some new derivatives of 4-substituted-3-(morpholinomethyl)-4h-1,2,4-triazole-5-thioles. *Journal of Faculty of Pharmacy of Ankara University*. 2019; 43(3):220–229. <https://doi.org/10.33483/jfpau.533166>.
- Dovbnia D, Frolova Y, Kaplaushenko A. A Study of hypoglycemic activity of acids and salts containing 1, 2, 4-triazole. *Ceska a Slovenska Farmacie: Casopis Ceske Farmaceuticke Spolecnosti a Slovenske Farmaceuticke Spolecnosti*. 2023; 72(3):113–124. PMID: 37648427.
- Shcherbyna R. An investigation of the pharmacokinetics and potential metabolites of potassium 2-((4-amino-5-(morpholinomethyl)-4H-1,2,4-triazol-3-yl)thio) acetate on rats. *Journal of Faculty of Pharmacy of Ankara University*. 2020; 44(2):233–241. <https://doi.org/10.33483/jfpau.681611>.
- Shcherbyna R, Vashchuk Y. The research of 1,2,4-triazole derivatives hepatoprotective activity under tetracycline and infectious hepatitis. *Journal of Faculty of Pharmacy of Ankara University*. 2019; 43(2):135–146. <https://doi.org/10.33483/jfpau.487173>.
- Gotsulya A. Synthesis and antiradical activity of alkyl derivatives of 5-(5-methyl-1H-pyrazol-3-yl)-4-phenyl-4H-1,2,4-triazole-3-thiol. *Journal of Faculty of Pharmacy of Ankara University*. 2020; 44(2):211–219. <https://doi.org/10.33483/jfpau.616116>.
- Gotsulya A, Zaika Y, Brytanova T. Synthesis, properties and biological potential some condensed derivatives 1,2,4-triazole. *Journal of Faculty of Pharmacy of Ankara University*. 2022; 46(2):308–321. <https://doi.org/10.33483/jfpau.971602>.
- Safonov A, Panasenko O. Synthesis, antimicrobial and antifungal activity of 3-(2-bromophenyl)-5-(alkylthio)-4-phenyl-4H-1,2,4-triazoles. *Current issues of pharmaceutical and medical science and practice*. 2022; 15(3):235–240. <https://doi.org/10.14739/2409-2932.2022.3.264691>.
- Knysh Y, Panasenko O, Safonov A. Sodium 2-((4-amino-5-(thiophen-2-ylmethyl)-4H-1,2,4-triazol-3-yl)thio)acetate, which shows actoprotective activity: patent 112619 Ukraine, 2016. [CrossRef]
- Ghanem CI, Pérez MJ, Manautou JE, Mottino AD. Acetaminophen from liver to brain: New insights into drug pharmacological action and toxicity. *Pharmacological research*. 2016; 109:119–131. <https://doi.org/10.1016/j.phrs.2016.02.020>.
- Jain S, Ahmed RS, Arora VK, Banerjee BD. Biochemical and histopathological studies to assess chronic toxicity of triazophos in blood, liver and brain tissue of rats. *Pesticide biochemistry and physiology*. 2011; 100(2):182–186. <https://doi.org/10.1016/j.pestbp.2011.03.00>.
- Safonov AA, Panasenko OI, Al Khalaf NA. Study of the effect of sodium 2-((4-amino-5-(thiophen-2-ylmethyl)-4H-1,2,4-triazole-3-yl) thio) acetate toxic doses on rats' heart tissue. *Current issues in pharmacy and medicine: science and practice*. 2024; 17(2):150–153. <https://doi.org/10.14739/2409-2932.2024.2.300859>.
- Safonov A, Demianenko D, Vashchuk Y, Larianovska Y, et al. Histological study of a corrective influence of sodium 2-((4-amino-5-(thiophen-2-ylmethyl)-4H-1,2,4-triazol-3-yl)thio) acetate on the state of rats liver under conditions of acute immobilization stress. *Journal of Faculty of Pharmacy of Ankara University*. 2022; 46(2):330–341. <https://doi.org/10.33483/jfpau.1012893>.
- Safonov A, Demianenko D, Vashchuk Y, Lytkin D, Polonets O, Kosareva A, Morozova L. Study of the Stress-Protective Effect of Sodium 2-((4-amino-5-(thiophen-2-ylmethyl)-4H-1,2,4-triazol-3-yl)thio)acetate. *HUJPHARM*. 2024; 44(2):143–52. <https://doi.org/10.52794/hujpharm.1374871>.
- Ministry of Health of Ukraine. Guideline. Medicinal Products. Preclinical Safety Studies for Clinical Trials Involving Humans and the Registration of Medicinal Products (ST-N MOZU 42-6.0:2014). Kyiv: Ministry of Health of Ukraine. 2014. Available from: <https://zakon.rada.gov.ua/rada/show/v0661282-14#Text>.
- Guide for the Care and Use of Laboratory Animals. Washington, D.C.: National Academies Press, 2011. <https://doi.org/10.17226/12910>.
- Directive 2010/63/EU of the European Parliament and of the Council of 22 September 2010 on the protection of animals used for scientific purposes. *Official Journal of the European Union*. 2010; 276:33–79 [CrossRef].
- Xu L, Shao A, Zhao Y, Wang Z, Zhang C, Sun Y, Chou LL. Neurotoxicity of silver nanoparticles in rat brain after intragastric exposure. *Journal of nanoscience and nanotechnology*. 2015; 15(6):4215–4223. <https://doi.org/10.1166/jnn.2015.9612>.
- Olayode OA, Daniyan MO, Olayiwola G. Biochemical, hematological and histopathological evaluation of the toxicity potential of the leaf extract of *Stachytarpheta cayennensis* in rats. *Journal of traditional and complementary medicine*. 2020; 10(6):544–554. doi: 10.1016/j.jtcme.2019.05.001.
- Durak MA, Parlakpınar H, Polat A, Vardi N, Ekici K, Ucar M, Pasahan R. Protective and therapeutic effects of molsidomine on radiation induced neural injury in rats. *Biotechnic & Histochemistry*. 2017; 92(1):68–77. <https://doi.org/10.1080/10520295.2016.1271454>.
- Safonov AA. Synthesis, transformation, physicochemical and biological properties of 1, 2, 4-triazole derivatives containing a thiophen-2-ylmethyl substituent (Doctoral dissertation, Zaporizhzhia State Medical University), 2023 [CrossRef].

Надійшла до редакції 17.11.2024 р.

Прийнята до друку 27.03.2025 р.

Електронна адреса для листування [8safonov@gmail.com](mailto:8safonov@gmail.com)