

ZAPORIZHZHYA STATE MEDICAL UNIVERSITY

THE DEPARTMENT OF INTERNAL DISEASES № 3

Casebook in RHEUMATOLOGY

**(tutorial for practical exercises for 6-year students of
medical faculty)**

2015

«RATIFIED»

by Central methodical advice of
Zaporizhzhya state medical university

Protocol № ____ from _____ 2015

Authors:

1. Dotsenko S.Y. - Head of department of internal diseases №3, Zaporizhzhya state medical university, associate professor, doctor of medical sciences
2. Sychov R.A. - associate professor of department of internal diseases №3, Zaporizhzhya state medical university, candidate of medical sciences
3. Samura B. B. - associate professor of department of internal diseases №3, Zaporizhzhya state medical university, candidate of medical sciences
4. Chornaya I. V. - associate professor of department of internal diseases №3, Zaporizhzhya state medical university, candidate of medical sciences
5. Medvedchuck G. Y. - associate professor of department of internal diseases №3, Zaporizhzhya state medical university, candidate of medical sciences

Практикум “Сборник клинических задач по внутренней медицине (часть IV: ревматология)” (на английском языке) предназначен для самостоятельной подготовки к практическим занятиям по дисциплине внутренние болезни англоговорящим студентам 6-го курса лечебного факультета. В практикум включены клинические задачи, вопросы и ответы к ним, дискуссии по синдромной диагностике в ревматологической практике.

Reviewers:

- head of the department of Clinical Pharmacology, Pharmacy and Pharmacotherapy with the Course of Cosmetology of Zaporizhzhya state medical university, doctor of medical sciences, professor Kraydashenko O.V.

- professor of the Family Medicine and Therapy Department of FPE of Zaporizhzhya state medical university, doctor of medical sciences Deynega V.G.

Contents:

Part I: Pain in limbs and back	
Part II: Arthralgia/myalgia	
Part III: Articular syndrome	
Part IV: Osteoarthritis	
Part V: Hemorrhagic syndrome	
Answers and discussion to cases.....	

Part I: PAIN IN LIMBS AND BACK

CASE 1:

An obese 35-year-old housekeeper presents with low back pain and requests an X-ray. She has had this pain off and on for several years; however, for the past 2 days it is worse than it has ever been. It started after she vigorously vacuumed a rug, is primarily on the right lower side, radiates down her posterior right thigh to her knee, but is not associated with any numbness or tingling. It is relieved by laying flat on her back with her legs slightly elevated and lessened somewhat when she takes ibuprofen 400 mg. Except for moderate obesity and difficulty maneuvering onto the examination table because of pain, her examination is fairly normal. The only abnormalities you note are a positive straight leg raise test, with raising the right leg eliciting more pain than the left. Her strength, sensation, and deep tendon reflexes in all extremities are normal.

- > What is your diagnosis?
- > What is your next step?

CASE 2:

A 28-year-old man presents with a 2-year history of progressively worsening back pain, fatigue, and morning stiffness. He also reports pain in his left hip and right heel. The symptoms improve with activity. Past medical history is negative. Physical exam is significant for reduced spinal range of motion. ESR is elevated. RF and ANA are negative.

- > What is the most likely diagnosis?
- > What would be the next step in management if plain films are nondiagnostic?
- > How is ankylosing spondylitis treated?

CASE 3:

A 36-year-old man presents with a 7-day history of lower back pain. The symptoms began after a day of lifting heavy boxes. The pain radiates to the buttocks but not to the thighs or legs. He does not have any other medical conditions. He does not smoke or use illegal drugs. On physical exam, there is mild tenderness in his lower back. Lumbosacral neurological exam and vital signs are normal.

- > What is the most likely diagnosis?
- > What is the next step in management?
- > How are such patients treated?

CASE 4:

A 48-year-old man presents with a 3-week history of back pain radiating to the back of his left thigh and calf. There is no history of trauma. He does not take any medications. On physical exam, straight leg raise (SLR) is positive. He has difficulty walking on his heels. Knee and ankle reflexes are normal. Vital signs are normal.

- > What is the differential diagnosis?
- > What is the next step in management?
- > What is the diagnosis?
- > What condition would you diagnose if Figure 4-2 were the patient's MRI?
- > What condition should you suspect if a patient with sciatica has no abnormal findings on MRI, the pain is worse in a sitting position, and the patient reports increased sciatic notch and buttock pain on hip

flexion, adduction, and internal rotation?

CASE 5:

A 50-year-old man who was diagnosed with prostate cancer 6 months ago presents with a 2-week history of increasingly severe low back pain. Over the last 2 days the pain has begun to radiate to the back of the thighs and calves. Plantar flexion and ankle jerk reflex are diminished bilaterally. Physical exam is also significant for decreased anal sphincter tone.

- > What is the differential diagnosis?
- > MRI detects a metastatic lesion. What is the next step in management?

CASE 6:

A 57-year-old woman presents with a 2-week history of fever and low back pain. She had a urinary tract infection 3 weeks ago. On physical exam, there is localized low back tenderness and reduced back mobility. Temperature is 38.2°C.

- > What is the next step in management?
- > How is vertebral osteomyelitis treated?
- > What additional test would have been indicated if the patient were an IV drug user or had a murmur on physical exam?
- > What would have been the next step if x-ray were normal?
- > What would have been the next step if CT-guided needle biopsy was negative?
- > What would have been the initial diagnostic test if the patient presented with fever, back pain, altered mental status, and decreased knee jerk reflex?

CASE 7:

A 34-year-old white man complains of neck pain. At the age of 22, the patient first noted low back, buttock, and spine pain. He had been involved in a motor vehicle accident to which he attributed some of his back pain. At that time, he saw a number of physicians who diagnosed mechanical LBP and recommended bed rest. However, he found this only seemed to make his back and buttock pain worse. Typically, he was very stiff in the morning for more than 2 hours but in the afternoon he felt better with movement and exercise. He also noted increasing fatigue and some mild weight loss. Ten years ago, his right hip started hurting. Eight years ago, pain suddenly developed in his right eye. He saw an ophthalmologist who diagnosed acute iritis and placed him on steroid eye drops. Two years ago, his knees started to swell intermittently. His lumbar and thoracic spine regions became fused and to stand up and look straight ahead he had to bend his knees. He finally had to quit his job as a truck driver because it required prolonged sitting that made his back pain and stiffness worse.

Musculoskeletal examination reveals no obvious swelling in any joint. No movement in the lumbar or thoracic spine is noted while the patient is bending over. His right hip is found to be painful on flexion with internal rotation.

Radiographic studies of the lumbosacral spine are obtained and interpreted to show almost complete obliteration of both sacroiliac joint spaces. The posterior elements in the distal lumbar area are also found to be obliterated, together with bridging or bambooing of the spine. A chest radiographic study shows squaring of the thoracic vertebrae with significant syndesmophyte formation.

- > Where is the primary site of disease in AS?
- > What organs can be involved in AS, and what are the clinical manifestations?
- > What are three characteristic clinical findings in patients with AS that help distinguish it from RA?
- > What is the characteristic family history, gender incidence, and human lymphocyte antigen (HLA) pattern found in the context of AS?
- > What types of treatment are helpful in AS?

PART II: ARTHRALGIA/MYALGIA

CASE 8:

A 59-year-old woman comes to your office because she is concerned that she might have a brain tumor. She has had a fairly severe headache for the last 3 weeks (she rates it as an 8 on a scale of 1-10).

She describes the pain as constant, occasionally throbbing but mostly a dull ache, and localized to the right side of her head. She thinks the pain is worse at night, especially when she lies with that side of her head on the pillow. She has had no nausea, vomiting, photophobia, or other visual disturbances. She has had headaches before, but they were mostly occipital and frontal, which she attributed to "stress," and they were relieved with acetaminophen. Her medical history is significant for hypertension, which is controlled with hydrochlorothiazide, and "arthritis" of her neck, shoulders, and hips for which she takes ibuprofen when she feels stiff and achy. On physical examination, her temperature is 100.4°F, heart rate 88 bpm, blood pressure 126/75 mm Hg, and respiratory rate 12 breaths per minute. Her visual acuity is normal, visual fields are intact, and her fundoscopic examination is significant for arteriolar narrowing but no papilledema or hemorrhage. She has moderate tenderness over the right side of her head but no obvious scalp lesions. Her chest is clear, her heart rhythm is regular, with normal S₁ and S₂ but an S₄ gallop. Abdominal examination is benign. She has no focal deficits on neurologic examination. She has no joint swelling or deformity but is tender to palpation over her shoulders, hips, and thighs.

- > What is the most likely diagnosis?
- > What is the best next step to confirm diagnosis?

CASE 9:

A 35-year-old woman presents with a 9-month history of episodic joint pain (arthralgia). The symptoms began with mild pain in the left metacarpophalangeal (MCP) joint, but now she has pain in both MCPs, both proximal interphalangeal joints (PIPs), and both knees. Her joints feel "stiff" for about an hour every morning. The stiffness improves with activity. The MCP and PIP joints are tender, swollen, and boggy. Vital signs are normal.

- > What is the most likely diagnosis?
- > What factors increase the risk of developing RA?
- > What imaging and laboratory studies are indicated initially?
- > What stage disease does she have?
- > How is RA treated?
- > What are some examples of DMARDs?
- > What are some examples of biological agents?

CASE 10:

A 60-year-old woman presents with a 2-month history of symmetric joint pain in her neck, shoulders, and hips. She also reports 30 to 40 minutes of stiffness every morning. Hand joints are not affected. There are no rheumatoid nodules. Plain radiographs are normal. RF, CCP, and LFTs are normal. ESR is 60 mm/hour (↑) and CBC shows anemia of chronic disease.

- > What is the most likely diagnosis?
- > How is PMR treated?
- > What complication should you suspect?
- > What is the next step in management?

CASE 11:

A 26-year-old woman reports 6 months of fatigue, asymmetric migratory polyarthralgias, and morning stiffness for >30 minutes that improves with activity. She also mentions getting sunburned very easily. She does not take any medications. On physical exam, her joints are tender, boggy, and swollen. RF is negative.

- > What diagnosis should you suspect?
- > What is the next step in evaluating the possibility of SLE?
- > What is the next step in management?
- > What other diagnostic test would have been indicated if the patient had a 10-year history of hydralazine use?
- > What initial treatment is indicated?
- > When are corticosteroids and other immunosuppressive therapies indicated?
- > What should you recommend?

CASE 12:

A 32-year-old woman presents with a 2-month history of fatigue and asymmetric polyarthralgia. She also mentions that over the last 5 months she has had episodes where her fingers become cold, numb, and white/blue when exposed to cold temperature. The episodes typically improve 15 to 20 minutes after placing her fingers in warm water (Raynaud's phenomenon). On physical exam, the joints are tender and swollen. There are patches of tight, thick skin on the trunk and arms (sclerosis).

- > What is the most likely diagnosis?
- > What causes scleroderma?
- > What systemic manifestations commonly occur in systemic scleroderma?
- > What antibodies are often positive in patients with systemic scleroderma?
- > How is scleroderma (Ssc) treated?
- > How is this condition managed?

CASE 13:

A 38-year-old Turkish woman presents with a 7-month history of fatigue and polyarthralgias. She also reports painful mouth sores over the last 3 months. Three days ago she developed burning vulvar pain. There is no history of antecedent infection. On physical exam, there are four large aphthous ulcers in the mouth. There are two painful vulvar ulcers. There is joint tenderness but no swelling in the elbows, knees, and shoulders.

- > What diagnosis should you suspect?
- > What other organs does Behçet's commonly affect?
- > What tests can aid in the diagnosis of Behçet's disease?
- > How is Behçet's disease treated?

CASE 14:

A 24-year-old woman presents with an 8-day history of joint pain. The symptoms started with pain and tenderness at the back of her hand with finger movement at the start of her menstrual period. She then had bilateral knee pain followed by left elbow pain and right wrist pain. She has had three sexual partners in the last 2 months. On physical exam, there are seven painless pustules on her trunk and arms. The joints are not swollen, warm, or erythematous. Vital signs are normal.

- > What is the most likely diagnosis?
- > What laboratory testing is indicated in patients with known or suspected DGI?
- > What is the next step in management?
- > What is the next step in management?

CASE 15:

A 32-year-old woman presents to her physician in New Jersey with a 3-day history of arthralgias. She reports pain in the knees followed by the left elbow and the right wrist. About a week before her symptoms began, she experienced a flu-like illness and an erythematous rash on her right arm. Vital signs are normal.

- > What diagnosis should you suspect?
- > What is the next step in management?
- > How would management differ if the patient did not have erythema multiforme?
- > What other illnesses are associated with Ixodes tick bites?

CASE 16:

A 28-year-old man presents to his physician in North Carolina in the month of May with migratory polyarthralgias. The arthralgias began after a 7-day period of fever, fatigue, headache, and nausea. On physical exam, there are petechiae on his palms and soles. CBC shows mild thrombocytopenia and serum chemistries show mild hyponatremia.

- > What is the most likely diagnosis?
- > What is the next step in management?
- > How would the choice of antibiotics differ if the patient were pregnant?

CASE 17:

A 61-year-old man presents with a 10-day history of anterior hip pain (groin pain). Past medical history is significant for chronic obstructive pulmonary disease requiring systemic steroids. He quit smoking 10 months ago but continues to drink a six-pack of beer every day. He has difficulty bearing weight and walking. Vital signs are normal.

- > What is the next step in management?
- > What is the diagnosis?

CASE 18:

A 37-year-old woman presents with a 2-year history of fatigue, stiffness, and body aches in multiple areas. Immunological tests for autoimmune arthritis have all been negative. Physical exam is significant for 13 areas of soft tissue tenderness. Vital signs are normal.

- > What tests are indicated in the initial evaluation of patients who present with chronic polymyalgia and multiple tender areas on physical exam?
- > What is the most likely diagnosis?
- > What is the next step in management?

CASE 19:

A 38-year-old woman is referred for evaluation because of diffuse pain and fatigue. She complains of 6 months of fatigue, generalized pain, difficulty sleeping, morning stiffness, and intermittent swelling of her fingers. The stiffness is worse in the morning, but she cannot put a definite time limit on it. She has a history of migraine headaches and irritable bowel syndrome.

She was first seen by her family physician complaining of pain all over. She was initially treated with indomethacin without relief. Subsequently, she has tried several different NSAIDs without relief of her symptoms.

She is a divorced mother of three children, who works full time as a licensed practical nurse. She has no history of a rash, oral ulcers, seizures, blood disorder, or known kidney disease.

Physical examination reveals normal vital signs, as well as normal head, ear, eyes, nose, throat, neck, skin, chest, and abdominal findings. Her fingers and joints are normal without any swelling or synovitis. Her muscular and neurologic examinations are nonfocal. Several tender points are identified.

- > What are two characteristics of the sleep disorder that commonly accompanies FMS?
- > What are the characteristic physical findings in FMS?
- > Are there any laboratory test abnormalities characteristic of FMS?
- > What is the therapy for FMS?
- > Which psychological disorders are often associated with FMS?

CASE 20:

A 56-year-old male construction worker complains of chronic pain in his knees and intermittent pain at the base of his thumb. When gripping something forcefully, the pain at the base of the thumb (first CMC) is sometimes so sharp that he is forced momentarily to stop what he is doing. His knees ache diffusely after excessive use. These complaints keep him from working as often as he would like. He reports no significant morning stiffness. His family history is unremarkable. Past medical history is significant for mild essential hypertension for which he has been taking hydrochlorothiazide for 8 years.

Physical examination reveals slight quadriceps atrophy on the right with slight genu varum and a pes anserinus bursitis, flattened arches, and moderate obesity. There is mild crepitus in both knees without ligamentous instability or effusions. There is moderate tenderness of the first CMC joints bilaterally. There are no Heberden's or Bouchard's nodes.

- > What are some of the characteristic changes that affect the articular cartilage in patients with OA?
- > What are four characteristic radiographic findings encountered in patients with OA?
- > Discuss the nonpharmacologic management of OA?
- > Discuss the pharmacologic options for the treatment of OA?

CASE 21:

A 47-year-old woman is seen by her primary care physician with a chief complaint of a 3-month history of muscle weakness along with vague complaints of decreased energy and diffuse aches and pains. Routine physical examination findings are unremarkable. The results of a baseline biochemical screen including thyroid function studies are within normal limits. Electrocardiography, a chest radiographic study, and pulmonary function test results are also unrevealing. She is given an empiric trial of naproxen.

Two months later, she begins to experience actual muscle tenderness and difficulty climbing the two flights of stairs to her apartment. On questioning, she also complains of pain, difficulty in chewing meats, and an 8-lb (3.6-kg) weight loss. She denies fevers, chest pain, shortness of breath, a change in bowel habits, or skin rashes.

Physical examination reveals grade 4/5 strength in the proximal muscle groups of both the upper and lower extremities without atrophy. There is also grade 4/5 weakness of the neck flexors. Her distal strength is normal. Her reflexes are symmetric. Her skin is clear. Breast and pelvic examination findings are unremarkable.

The following laboratory results are reported: hematocrit 34%; ESR 63 mm per hour; ANA 1:256 fine speckled pattern; rheumatoid factor (RF) negative; CPK 1,850 U/L (normal <150 U/L).

She is scheduled to undergo right-sided EMG and muscle biopsy of the left triceps.

- > What other organs beside muscle may be involved in patients with polymyositis or dermatomyositis?
- > What four different skin lesions are seen in patients with dermatomyositis?
- > What diagnostic evaluation is indicated to search for a possible malignancy in patients with polymyositis or dermatomyositis, and what may happen to the muscle disease when the malignancy is treated?
- > What is the approach to treatment of polymyositis/dermatomyositis?

CASE 22:

A 45-year-old woman seeks medical attention because of progressive symmetric skin tightening that has involved the digits, hands, and forearms during the last 6 months. These skin changes are painless and are associated with mild pruritus. During the last 12 months, she has also noted the onset of cold sensitivity of the hands, especially when handling objects in the refrigerator, with multiple fingers becoming cold, pale, and numb. She also reports generalized fatigue, dyspnea on exertion, and a decrease in exercise tolerance. She denies chest pain, palpitations, or paroxysmal nocturnal dyspnea, but has noticed symmetric swelling in both lower extremities. She has noted a 10-lb (4.5-kg) weight loss in the last 6 months, which she has attributed to decreased food intake because of her heartburn and dysphagia.

On physical examination, the woman appears younger than her stated age as she lacks the normal forehead wrinkling and has a pursed-lips appearance. A few scattered facial telangiectases are noted. Her skin is very tight and cannot be easily lifted from over the dorsum of the hands, fingers, and lower forearms. There are very small punctate healed ulcerations on several fingertips. Nail findings are unremarkable. Her muscle strength is normal and there is no evidence of synovitis. Chest examination reveals clear lung fields. On cardiac examination, no gallops, murmurs, or rubs are heard but the pulmonic second sound (P₂) is loud. Her jugular venous pressure is slightly elevated, and there is 1 + pitting edema over both lower extremities.

- > What three different rheumatic diseases are suggested by a predominance of skin findings?
- > Raynaud's phenomenon may occur in association with what four rheumatic diseases?
- > Dysphagia or heartburn may predominate in what two rheumatic diseases?
- > What features characterize CREST syndrome?
- > What is the difference between limited and diffuse scleroderma (systemic sclerosis)?

CASE 23:

A 52-year-old woman is seen in the emergency room because of an acutely painful and swollen right knee. The patient has a 10-year history of RA that has not responded well to multiple medications. For the last 6 months, she has been taking ibuprofen, azathioprine 100 mg daily, and prednisone 10 mg daily. Despite this regimen, she continues to experience 2 hours of morning stiffness with swelling, erythema,

and pain in multiple small joints of her hands, wrists, knees, and ankles. She is now unable to bear weight on the right leg. A low-grade fever also developed.

On physical examination, the patient's temperature is found to be 38.5B°C (101.3B°F) and her blood pressure is 150/100 mm Hg. She appears both acutely and chronically ill with mild swelling of multiple MCP and PIP joints as well as both wrists and ankles. Her right knee is held in 10 degrees of flexion and it cannot be moved because of severe pain. The knee exhibits a large effusion and is diffusely tender with erythema around the entire joint. Joint aspiration is performed and 20 mL of opaque, yellow fluid is removed that has low viscosity. The WBC count in the synovial fluid aspirate is 75,000/BµL with 98% polymorphonuclear leukocytes. Synovial fluid crystal analysis is negative. There are gram-positive cocci on Gram's stain of the synovial fluid. The fluid is cultured for organisms.

- > When should arthrocentesis be performed?
- > What diagnostic tests should be performed on all synovial fluid aspirates regardless of the suspected diagnosis?
- > What are the characteristics of normal, noninflammatory, inflammatory, and septic synovial effusions?
- > What are the causes of bloody or hemorrhagic synovial fluid?

CASE 24:

A 28-year-old woman presents with a 2-month history of painful joints and fatigue. She states that the joint pain affects her hands, wrists, feet, ankles, and knees and is associated with some joint swelling and 2 to 3 hours of morning stiffness. Over the last 3 to 4 months, the patient has noted gradually increasing fatigue and has had three or four episodes of rash over her face and neck. During the last summer, she states that she had a similar rash that was precipitated by exposure to the sun. She has also noted that prolonged sun exposure results in increasing fatigue and a flu-like syndrome. Two weeks ago, she noted her ankles tend to swell at the end of the day. Past medical history reveals that 8 months ago she had an episode of pleuritic chest pain that lasted 8 to 10 days and was treated by her family doctor with indomethacin followed by gradual resolution.

Physical examination reveals a tired-looking woman who is in no acute distress. Her temperature is 38.2B°C (100.8B°F), blood pressure is 140/100 mm Hg, and pulse is 96 beats per minute and regular. On examination of the skin, an erythematous rash is noted over her nose and cheeks that spares the nasolabial folds. Several shallow painless ulcers are found in her mouth. Joint examination reveals minimal swelling of the wrists and MCP joints. Pulmonary and cardiac findings are normal except for 2+ pitting edema in the pretibial area, bilaterally.

- > What clinical features suggest a diagnosis of SLE?
- > What abnormal laboratory results suggest a diagnosis of SLE?
- > Besides SLE, ANAs are commonly found in what other diseases?

CASE 25:

A 23-year-old African-Caribbean woman is admitted to the emergency department having had two tonic-clonic generalized seizures which were witnessed by her mother. Her mother says that her daughter has been behaving increasingly strangely, and has been hearing voices talking about her. Recently, she has complained of severe headaches. She has lost weight and has noticed that her hair has been falling out. She has also complained of night sweats and flitting joint pains affecting mainly the small joints of her hands and feet. She works as a bank clerk. She smokes 5-10 cigarettes per day and consumes about 10 units of alcohol per week. She is taking no regular medication. She has no significant medical or psychiatric history.

She is drowsy but responsive to pain. There is no neck stiffness. Her scalp hair is thin and patchy. Her temperature is 38.5°C. She has numerous small palpable lymph nodes. Her pulse rate is 104/min regular, blood pressure 164/102 mmHg. Examination of her cardiovascular, respiratory and abdominal systems is otherwise normal. Neurological examination reveals no focal abnormality and no papilloedema.

		Normal
Haemoglobin	7.2 g/dL	11.7-15.7 g/dL
Mean corpuscular volume (MCV)	85 fL	80-99 fL
White cell count	2.2 X 10 ⁹ /L	3.5-11.0 X 10 ⁹ /L

Platelets	72 X 10 ⁹ /L	150-440 X 10 ⁹ /L
Erythrocyte sedimentation rate (ESR)	90 mm/h	<10 mm/h
Sodium	136 mmol/L	135-145 mmol/L
Potassium	4.2 mmol/L	3.5-5.0 mmol/L
Urea	16.4 mmol/L	2.5-6.7 mmol/L
Creatinine	176 µmol/L	70-120 µmol/L
Glucose	4.8 mmol/L	4.0-6.0 mmol/L
Lumbar puncture		
Leucocytes	150/mL	< 5/mL
Cerebrospinal fluid (CSF) protein	1.2 g/L	<0.4 g/L
CSF glucose plasma glucose value	4.1 mmol/L	>70 per cent

Urinalysis: + + + protein; + + + blood. Urine microscopy: ++ red cell; red cell casts present. Chest X-ray: normal. Electrocardiogram (ECG): sinus tachycardia Computed tomography (CT) of the brain: normal CSF Gram stain: negative

- > What is the likely diagnosis?
- > How would you investigate and manage this patient?

PART III: ARTICULAR SYNDROME

CASE 26:

A 48-year-old man comes to your office complaining of severe right knee pain for 8 hours. He states that the pain, which started abruptly at 2 AM and woke him from sleep, was quite severe, so painful that even the weight of the bed sheets on his knee was unbearable. By the morning, the knee had become warm, swollen, and tender. He explains that he prefers to keep his knee bent, and extending his leg to straighten the knee causes the pain to worsen. He has never had pain, surgery, or injury to his knees. A year ago, he did have some pain and swelling at the base of his great toe on the left foot, which was not as severe as this episode, and resolved in 2 or 3 days after taking ibuprofen. His only medical history is hypertension, which is controlled with hydrochlorothiazide. He works as a financial analyst; he is married and does not smoke, but he does consume one or two drinks after work one to two times per week.

On examination, his temperature is 100.6°F, heart rate 104 bpm, and blood pressure 136/78 mm Hg. His head and neck examinations are unremarkable, his chest is clear, and his heart is tachycardic but regular, with no gallops or murmurs. His right knee is swollen, with a moderate effusion, and appears erythematous, warm, and very tender to palpation. He is unable to fully extend the knee because of pain. He has no other joint swelling, pain, or deformity, and no skin rashes.

- > What is the most likely diagnosis?
- > What is your next step?
- > What is the best initial treatment?

CASE 27:

A 32-year-old nurse presents to your office with a complaint of intermittent episodes of pain, stiffness, and swelling in both hands and wrists for approximately 1 year. The episodes last for several weeks and then resolve. More recently, she noticed similar symptoms in her knees and ankles. Joint pain and stiffness are making it harder for her to get out of bed in the morning and are interfering with her ability to perform her duties at work. The joint stiffness usually lasts for several hours before improving. She also reports malaise and easy fatigability for the past few months, but she denies having fever, chills, skin rashes, and weight loss. Physical examination reveals a well-developed woman, with blood pressure 120/70 mm Hg, heart rate 82 bpm, and respiratory rate 14 breaths per minute. Her skin does not reveal any rashes. Head, neck, cardiovascular, chest, and abdominal examinations are normal. There is no hepatosplenomegaly. The joint examination reveals the presence of bilateral swelling, redness and tenderness of most proximal interphalangeal (PIP) joints, metacarpophalangeal (MCP) joints, the wrists, and the knees. Laboratory studies show a mild anemia with hemoglobin 11.2 g/dL, hematocrit 32.5%,

mean corpuscular volume (MCV) 85.7 fL, white blood cell (WBC) count 7.9/mm³ with a normal differential, and platelet count 300,000/mm³. The urinalysis is clear with no protein and no red blood cells (RBCs). The erythrocyte sedimentation rate (ESR) is 75 mm/h, and the kidney and liver function tests are normal.

- > What is your most likely diagnosis?
- > What is your next diagnostic step?

CASE 28:

A 48-year-old woman with a 10-year history of RA presents with a 2-month history of difficulty climbing stairs and combing her hair. Her current medications include MTX, infliximab, and prednisone. Physical exam is significant for proximal muscle weakness. There is no sensory loss. There is mild ulnar deviation but no tenderness or boggiess. ESR and CRP are normal. Creatinine kinase is normal.

- > What is the most likely cause of her symptoms?
- > What are other important causes of weakness in patients with RA?

CASE 29:

A 51-year-old woman with a 25-year history of RA presents with a 2-day history of numbness and tingling in her left foot. She also reports increased fatigue and unintentional weight loss over the last 6 weeks. On physical exam, there is ulnar deviation, swan-neck deformity, and rheumatoid nodules. There are petechiae on her fingertips. There is an ulcer with a violaceous border on her right foot. Vital signs are normal. ESR and CRP are elevated. RF and anti-CCP are positive.

- > What is the most likely diagnosis?
- > How can you confirm the diagnosis?
- > How is rheumatoid vasculitis treated?

CASE 30:

A 57-year-old woman with long-standing severe RA presents for a routine evaluation. She takes Anakinra (inhibits the action of the molecule interleukin-1). Physical exam is significant for rheumatoid nodules, boutonniere deformity, and splenomegaly. RF is positive (1:640 titer). Leukocyte count is 2000 U/L (↓) and absolute neutrophil count is 700 U/L (↓).

- > What is the most likely diagnosis?
- > How is Felty's syndrome treated?

CASE 31:

A 69-year-old man with long-standing RA presents with a 6-month history of dry mouth and eye irritation. He describes the ocular symptoms as a “feeling of grit.” The parotid gland is firm and enlarged but not tender.

- > What diagnosis should you suspect?
- > How can you confirm the diagnosis?

CASE 32:

A 38-year-old man presents with a 7-month history of asymmetric oligoarthritis, morning stiffness >30 minutes, and symptom improvement with activity. The symptoms occur in the back, right hip, left knee, and right heel. Physical exam is significant for diffuse swelling of the digits (dactylitis), nail pitting, and erythematous plaques on his elbows and behind his ears. The plaques are covered by a silvery scale. RF and ANA are negative.

- > What is the most likely diagnosis?
- > What are spondyloarthropathies?
- > How is psoriatic arthritis treated?

CASE 33:

A 66-year-old man presents with an 8-month history of polyarthralgias. He reports bilateral knee, hip, and finger pain. Physical activity makes the pain worse. He also has morning stiffness that resolves in

10 to 15 minutes. On physical exam, there is joint tenderness and effusions. Vitals signs are normal.

- > What is the most likely diagnosis?
 - > What causes osteoarthritis (OA)?
 - > What are the characteristic x-ray findings of OA?
 - > What initial management is recommended?
 - > When should you suspect a secondary cause is responsible for OA?
-

CASE 34:

A 36-year-old IV drug user presents with a 2-day history of fever and knee pain. HIV test 3 weeks ago was negative. On physical exam, the right knee is swollen, tender, warm and erythematous. Temperature is 38.9°C.

- > What is the differential diagnosis of fever and joint pain?
 - > What is the next step in management?
 - > What is the diagnosis?
 - > How should you treat this patient?
 - > What treatment would you initiate if gram stain had showed Gram-negative bacilli?
 - > How would management have differed if the Gram stain were negative?
-

CASE 35:

A 48-year-old man presents with a 6-hour history of excruciating pain in his left big toe (first metatarsophalangeal joint). He does not have any other medical conditions. He does not take any medications. He drinks 5 to 6 cans of beer every day. On physical exam, the joint is warm, tender, swollen, and erythematous. Vital signs are temperature 38.1°C, pulse 110 bpm, respirations 20/min, and blood pressure 160/90. BMI is 32.

- > What is the most likely diagnosis?
 - > What causes gout?
 - > What is the next diagnostic step?
 - > How are acute attacks of gout treated?
 - > What measures are recommended to prevent recurrent attacks?
 - > What is the next step to prevent recurrences?
 - > What uric acid-lowering therapy would you have recommended if 24-hour urine uric acid was >800 mg/day?
 - > What is this stage of disease called?
-

CASE 36:

A 45-year-old man presents with a 6-hour history of excruciating pain in the left knee. He does not have any other medical conditions. He does not drink alcohol or take any medications. On physical exam, the joint is swollen, tender, warm, and erythematous. Temperature is 38.3°C. Translucent fluid is aspirated from the joint. Synovial fluid analysis demonstrates 4000 WBCs/mm³, 60% neutrophils, and glucose 60 mg/dL. Figure 36 - 1 is the specimen's appearance on polarized light microscopy. Gram stain is negative. Culture is pending.

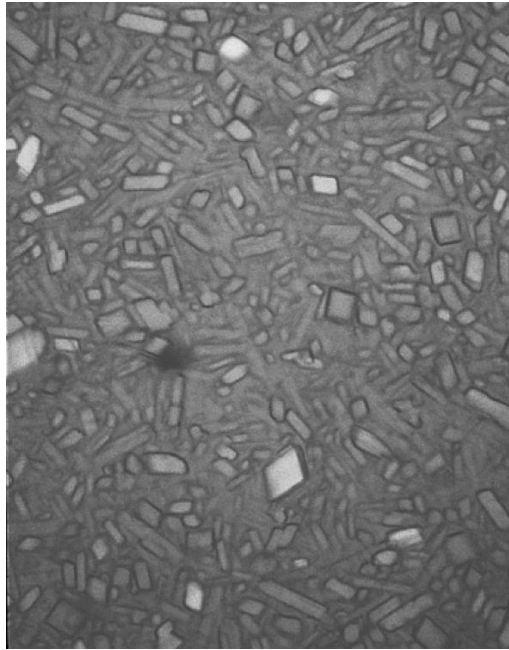


Figure 36–1. Pseudogout: Positive birefringent rhomboid crystals.

- > What is the diagnosis?
- > What tests are routinely recommended in patients with CPPD deposition?
- > How is acute pseudogout due to CPPD crystal deposition treated?

CASE 37:

A 27-year-old man presents with a 5-day history of dysuria and urethral discharge. Urethral swab demonstrates *Chlamydia trachomatis*, so he receives azithromycin and ceftriaxone. Three weeks later, he presents with joint pain. He reports pain in his back, left knee, right ankle, and left heel. The joints are swollen, tender, and erythematous. Arthrocentesis with synovial fluid analysis shows 8000 WBCs/mm³ with 60% neutrophils and glucose of 50 mg/dL. There are shallow, painless ulcers on his penis. ESR and CRP are mildly elevated.

- > What is the diagnosis?
- > What causes reactive arthritis?
- > How is reactive arthritis treated?

CASE 38:

A 52-year-old man comes to the emergency room complaining of pain in his big toe. He was well until 5:00 this morning, when he was awakened by an aching pain in his right great toe. Within a few hours, the joint was dusky red and hot, and was exquisitely tender to the point that even the weight of the bedding hurt his toe. By 8:00 a.m., the patient could bear only partial weight on the foot. The patient reports a few self-limited, trivial episodes of twinges of pain in this toe over the past year. The patient describes feeling feverish without rigors or chills. There is no history of trauma to the foot, nor is there a family history of arthritis or similar attacks. He is taking hydrochlorothiazide for control of hypertension.

On physical examination, the patient is found to be a stocky, overweight, and red-faced man. His blood pressure is 170/100 mm Hg, his pulse is 90 beats per minute and regular, and his temperature is 38B°C (100.4B°F). Skin examination discloses no lesions or nodules. On examination of his joints, all show a normal range of motion without synovitis or deformity, except for the right first MTP joint, which shows synovitis, 2+/4; warmth, 4+/4; tenderness, 4+/4; and erythema at the base of the toe extending onto the dorsal aspect of the forefoot with slight edema.

The following laboratory values are reported: white blood cell (WBC) count 12,500 cells/mm³ with 92% polymorphonuclear leukocytes and 2% band forms; uric acid 9.0 mg/dL; creatinine 1.0 mg/dL. Urinalysis reveals no red blood cells or protein. A radiographic study of the right foot discloses soft tissue swelling around the right first MTP joint, but no erosions.

- How is the diagnosis of gout established?
- Why are humans predisposed to developing gout?
- What are the four reversible secondary causes of hyperuricemia?

- What are the four clinical stages of gout?
 - What are the appropriate therapies for an acute attack of gout and chronic symptomatic hyperuricemia?
-

CASE 39:

A 32-year-old man is seen because of increasing right knee pain and swelling over the last 3 days. On further questioning, it is discovered that 2 weeks ago, the patient had an episode of mild dysuria associated with a mucous discharge. This illness resolved spontaneously after 4 days. Six days ago, painless, shallow ulcerations of the glans penis developed. During this period, he also noted the onset of bilateral redness and pruritus of the eyes along with a clear discharge. Three days ago, acute swelling of the right knee associated with pain arose spontaneously and has steadily worsened.

Physical examination reveals mild injection of the conjunctival vessels bilaterally. His visual acuity and retina are normal. Slit-lamp examination by ophthalmology demonstrates no evidence of anterior uveitis. Examination of the skin reveals discrete hyperkeratotic nodules over the soles of his feet bilaterally and there are three shallow ulcers on the glans penis. His right knee is warm and tender, and there is a significant amount of palpable synovial fluid. The remainder of the examination findings are unremarkable.

- > What other forms of rheumatic disease need to be considered when reactive arthritis is suspected, and what diagnostic tests or procedures should be performed to exclude them?
 - > What are some of the clinical or laboratory characteristics of reactive arthritis that help differentiate it from RA?
 - > What are the three types of skin lesions seen in patients with reactive arthritis?
 - > The back disease in patients with reactive arthritis is characterized by what radiographic findings?
 - > What is the therapy for reactive arthritis?
-

CASE 40:

A 38-year-old woman is seen because of pain and swelling in the joints of her hands, as well as in her wrists, elbows, and knees. Her symptoms have been intermittent over the last 8 months but have worsened recently and become more prolonged. The pain and swelling have been accompanied by hand stiffness in the morning, frequently lasting for 2 hours or more, and she has noted return of the stiffness later in the day after periods of inactivity. She also complains of progressively worsening fatigue and lack of energy. She denies rash, photosensitivity, alopecia, oral ulcers, or symptoms of Raynaud's phenomenon. She experiences left wrist pain that radiates to her elbow and into her fingers, which is worse in the morning and occasionally awakens her at night.

On physical examination, swelling, warmth, and tenderness are noted in several MCP and PIP joints bilaterally. Her wrists are slightly swollen and tender to palpation especially in the region of the ulnar styloid processes. Her elbows exhibit slight tenderness to palpation and mild flexion contractures bilaterally. Small effusions are present in both knees. Tenderness is elicited over several MTP joints in both feet. Tinel's sign (tapping over the volar carpal ligament with the wrist in extension) is elicited over the left wrist and Phalen's test (positioning the wrist at full volar flexion for 60 seconds) reproduces the patient's left wrist and forearm pain. Examination of the skin reveals the presence of several subcutaneous nodules over the proximal extensor aspects of both forearms.

- > What four characteristics of RA help distinguish it from OA?
 - > What constitutional symptoms may be seen in RA?
 - > What are three characteristic physical findings in RA?
 - > What five diseases may mimic RA?
 - > Which serologic tests may be useful in the diagnosis of RA?
-

CASE 41:

A 37-year-old man presents to his general practitioner (GP) with a 5-day story of urinary frequency, dysuria and urethral discharge. In the previous 24 h he had become unwell, feeling feverish and with a painful right knee. He works in an international bank and frequently travels to Asia and Australia, from where he had last returned 2 weeks ago. There is no relevant past or family history and he takes no medication.

He looks unwell, and has a temperature of 38.1°C. His heart rate is 90/min, blood pressure 124/82 mmHg. Otherwise examination of the cardiovascular, respiratory, abdominal and nervous systems is normal. His right knee is swollen, slightly tender, and there is a small effusion with slight limitation of flexion. There is no skin rash and no oral mucosal abnormality. He has a cream-coloured urethral discharge.

		Normal
Haemoglobin	17.1 g/dL	13.3-17.7 g/dL
White cell count	16.9 X 10 ⁹ /L	3.9-10.6 X 10 ⁹ /L
Platelets	222 X 10 ⁹ /L	150-440 X 10 ⁹ /L

Blood film: neutrophil leukocytosis X-ray of right knee is shown in Fig. 41.1.

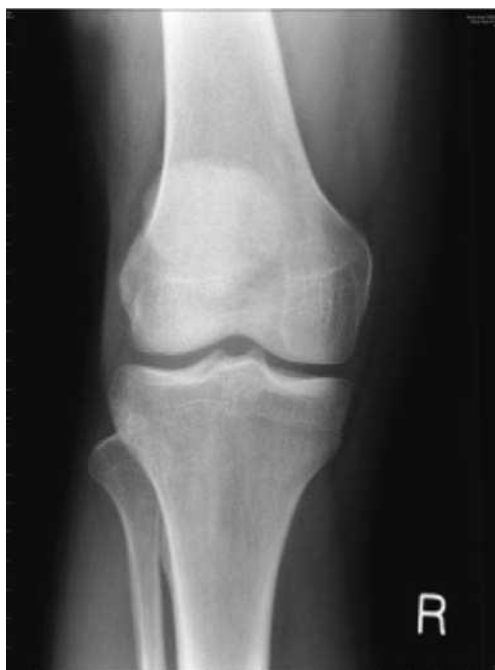

Figure 41.1 X-ray of the right knee.

- > How would you investigate and manage this patient?
- > What is the likely diagnosis?

PART IV: OSTEOARTHRITIS

CASE 42:

A 75-year-old white woman presents to the emergency room with right wrist pain after a fall at home. She tripped and fell while preparing dinner, and she says that she tried to stop her fall with her outstretched right hand. She heard a "snap" and felt immediate pain. Her medical history is remarkable only for three normal pregnancies, menopause at age 50 years, and hypertension that is well controlled with diuretics. She has a 50-pack per year history of smoking. Her weight is 100 lb and her height is 5 ft 6 in. Her examination is remarkable for normal vital signs; a swollen, deformed right distal forearm and wrist, with limited mobility because of pain; and good radial pulses and capillary refill in the right fingernail beds. An X-ray confirms a fracture of the right radial head, and the radiologist notes osteopenia.

- > What risk factor for fracture is this woman likely to have?
- > What are the causes of this condition?
- > What are the best preventive measures?

CASE 43:

A 56-year-old woman presents to her doctor's office complaining of gradually progressive, nonpainful enlargement of the terminal joint on her left hand over a 9-month period. She has some stiffness with typing but not first thing in the morning. She also reports pain in her right knee, which occasionally "locks up." The right knee also hurts after long walks. On examination, her blood pressure is 130/85 mm

Hg, heart rate 80 bpm, and weight 285 lb. Examination reveals only a nontender enlargement of her left distal interphalangeal (DIP) joint, and the right knee is noted to have crepitus and slightly decreased range of motion. There is no redness or swelling.

- > What is your next step?
- > What is the most likely diagnosis?
- > What is the best initial treatment?

PART V: HEMORRHAGIC SYNDROME

CASE 44:

A 45-year-old white man seeks medical care because of hemoptysis of 1-week duration. He has not felt well for approximately 4 months and has lost 10 lb (4.5 kg) during this time. He has been receiving various antibiotics for the treatment of chest radiographic abnormalities thought to represent pneumonia. Although these changes have varied in presentation, they have not disappeared. A few weeks earlier, he noted some bloody nasal discharge. He started coughing up blood 1 week ago but attributed it to his bloody nose. The patient also complains that his left knee has been hurting and that red spots have appeared on his arms and legs. He denies fever, purulent sputum, allergies or asthma, known tuberculosis, or chest pain.

On physical examination, there is a curious depression in his upper nose (saddle-nose deformity), bloody discharge in his nasal cavity, a painless ulcer on his soft palate, and a slightly warm and swollen left knee. Chest findings are normal. There are many small, purpuric, raised lesions on the skin of his lower extremities that are painless.

- > What are four possible diagnoses in this patient?
- > What diagnostic studies or procedures might be of value in this patient?
- > Which disorders are associated with p-ANCA?
- > What constitutes appropriate therapy for this patient with Wegener's granulomatosis?

ANSWERS TO CASE 1:

An obese 35-year-old woman with acute worsening of chronic low back pain complains of shooting pain down her right leg. Her physical examination is normal.

- > Most likely diagnosis: Musculoskeletal low back pain, possible sciatica without neurologic deficits.
- > Next step: Encourage continuation of usual activity, avoiding twisting motions or heavy lifting. Use nonsteroidal anti-inflammatory drugs (NSAIDs) on a scheduled basis; you can also recommend muscle relaxants, although these drugs may cause sleepiness. Massage might be helpful. Follow-up in 4 weeks. Long-term advice includes weight loss and back-strengthening exercises.

ANALYSIS

Considerations

This young patient with chronic back pain has an acute exacerbation with pain radiating down her leg, which may indicate possible sciatic nerve compression. She has no other neurologic abnormalities, such as sensory deficits, motor weakness, or “red flag” symptoms of more serious etiologies of back pain, which if present would demand a more urgent evaluation. Thus, this individual has a good prognosis for recovery with conservative therapy, perhaps time being the most important factor. If she does not improve after 6 weeks, then imaging studies can be considered.

Approach to low back pain

Definitions

CAUDA EQUINA SYNDROME: Lower back pain, saddle anesthesia, and bowel or bladder dysfunction with possible lower extremity weakness and loss of reflexes caused by compression of multiple sacral nerve roots. Cauda equine syndrome is a surgical emergency. **SCIATICA:** Pain in the distribution of the lumbar or sacral nerve roots, with or without motor or sensory deficits.

SPONDYLOLISTHESIS: Anterior displacement of an upper vertebral body on the lower body, which can cause symptoms and signs of spinal stenosis. This condition can result from spondylolysis or from degenerative disk disease in the elderly.

SPONDYLOLYSIS: Defect in the pars interarticularis, either congenital or secondary to a stress fracture.

Clinical approach

Low back pain is experienced by two-thirds of all adults at some point in their lives. Approximately 2% of adults miss work each year because of low back pain. This complaint is most common in adults in their working years, usually affecting patients between 30 and 60 years of age. Although it is common in workers required to perform lifting and twisting, it is also a common complaint in those who sit or stand for prolonged periods. Low back pain is a recurrent disease that tends to be mild in younger patients, often resolving by 1 weeks, but can be more severe and prolonged as the patient ages. It is one of the most common reasons for young adults to seek medical care, second only to upper respiratory infections, and millions of health-care dollars are expended on this problem each year. In evaluating patients with low back pain, the clinician needs to exclude potentially serious conditions, such as malignancy, infection, and dangerous neurologic processes, such as spinal cord compression or cauda equina syndrome. Individuals without these conditions are initially managed with conservative therapy. Nearly all patients recover spontaneously within 4 to 6 weeks; only 3% to 5% remain disabled for more than 3 months. If patients do not improve within 4 weeks with conservative management, they should undergo further evaluation to rule out systemic or rheumatic disease and to clarify the anatomic cause, especially patients with localized pain, nocturnal pain, or sciatica.

The potential causes of back pain are numerous (Table 1-1). Pain can emanate from the bones, ligaments, muscles, or nerves. Rarely, it can be a result of referred pain from a visceral organ or other structure. Back pain with radiation down the back of the leg suggests sciatic nerve root compression, generally caused by a herniated intervertebral disk at the L4-L5 or L5-S1 level. Patients typically report aching pain in the buttock and paresthesias radiating into the posterior thigh and calf or lateral foreleg. When pain radiates below the knee, it is more likely to indicate a true radiculopathy than radiation only to the posterior thigh. A history of persistent leg numbness or weakness further increases the likelihood of neurologic involvement.

Table 1-1. Etiologies of low back pain

Causes of low back pain	Incidence
-------------------------	-----------

Musculoskeletal low back or leg pain	97%
• Lumbar sprain or strain	70%
• Degenerative disk disease	10%
• Herniated disk	4%
• Spinal stenosis	3%
• Trauma	1%
• Congenital disease, eg, kyphoscoliosis	<1%
Referred or visceral pain	2%
• Pelvic disease	
• Renal disease	
• Aortic aneurysm	
• Gastrointestinal disease	
Nonmechanical low back pain	1%
• Neoplasia	
• Infection	
• Inflammatory arthritis	
• Paget disease	

Most cases are idiopathic, and this group, in general, is referred to as musculoskeletal low back pain. Imaging studies and other diagnostic tests are generally not helpful in managing these cases. Studies show that the history and physical examination can help separate the majority of patients with simple and self-limited musculoskeletal back pain from the minority with more serious underlying causes. Finding “red-flag” symptoms can help the physician use diagnostic tests in a more judicious manner (Table 1-2). Malignancy should be considered in patients with systemic symptoms and who have pain at night or pain that is not relieved by lying in a supine position. Primary cancers which commonly metastasize to the spine include lung, breast, prostate, lymphoma, and gastrointestinal (GI) tumors and melanoma. Multiple myeloma is a plasma cell neoplasm which can present with bone pain, renal failure, and anemia. When the patient has worrisome symptoms or signs, in most cases, the most effective initial evaluation is plain anteroposterior and lateral radiographs of the involved area of the spine, a sedimentation rate, and a complete blood count. More expensive tests, such as magnetic resonance imaging (MRI), should be reserved for those patients for whom surgery is being considered, because it is not required to make most diagnoses.

Table 1-2. "Red flag" signs and symptoms of low back pain

-
- New onset of pain in a patient older than 50 y or younger than 20 y
 - Fever
 - Unintentional weight loss
 - Severe nighttime pain or pain that is worse in the supine position
 - Bowel or bladder incontinence
 - History of cancer
 - Immunosuppression (chemotherapy or HIV)
 - Saddle anesthesia
 - Major motor weakness
-

It is rare that the patient can recall a precipitating event. Patients often have a history of recurrent episodes of low back pain. Psychological causes have not been consistently related to low back pain; however, there does seem to be an association with job satisfaction. During the physical examination, palpable point tenderness over the spinous processes may indicate a destructive lesion of the spine itself; however, those with musculoskeletal back pain most often have tenderness in the muscular paraspinal area. Strength, sensation, and reflexes should be assessed, especially in those with complaints of radicular or radiating pain. Straight leg raise testing, in which the examiner holds the patient's ankle and passively elevates the patient's leg to 45°, is helpful if it elicits pain in the lower back. However, it is not a very sensitive or specific test. The Patrick maneuver, in which the patient externally rotates the hip, flexes the knee, and crosses the knee of the other leg with the ankle (like a number 4) while the examiner simultaneously presses down on the flexed knee and the opposite side of the pelvis, can help distinguish

pain emanating from the sacroiliac joint.

In treating idiopathic low back pain, various modalities have been shown to be equally effective in the long run. Randomized, controlled trials have shown that encouraging the patient to continue his or her usual activity is superior to recommendations for bed rest. Patients without disability and without evidence of nerve root compression probably can be instructed to position himself or herself so as to minimize pain; this usually consists of lying supine with the upper body slightly elevated and a pillow under the knees. Nonsteroidal anti-inflammatory medications (on a scheduled rather than on an as-needed basis), nonaspirin analgesics, and muscle relaxants may help in the acute phase. Because most cases of disk herniation with radiculopathy resolve spontaneously within 4 to 6 weeks without surgery, this is the initial regimen recommended for these patients as well. Narcotic analgesics are also an option in cases of severe pain; however, because idiopathic low back pain is often a chronic problem, their prolonged use beyond the initial phase is discouraged. Chiropractic, physical therapy, massage therapy, and acupuncture have been studied (in trials of varying quality), with results comparable to traditional approaches. Referral to a surgeon may be considered for those patients with radicular pain with or without neuropathy that does not resolve with 4 to 6 weeks of conservative management.

Comprehension Questions

1. A 35-year-old obese hotel housekeeper presents with 1 week of lower back pain. Her history and examination are without “red flag” symptoms and completely normal, except for her weight. Which of the following is the best next step?

- A. Regular doses of a nonnarcotic analgesic
 - B. Six weeks of bedrest
 - C. MRI of the lumbar spine
 - D. Plain film X-ray of lumbosacral spine
-

2. A 32-year-old woman from Nigeria presents with a 12-week history of persistent lower lumbar back pain, associated with a low-grade fever and night sweats. She denies any extremity weakness or HIV (human immunodeficiency virus) risk factors. Her examination is normal except for point tenderness over the spinous processes of L4-5. Which of the following is the most likely diagnosis?

- A. *Staphylococcus aureus* osteomyelitis
 - B. Tuberculous osteomyelitis
 - C. Given her age, idiopathic low back pain
 - D. Metastatic breast cancer
 - E. Multiple myeloma
-

3. A 70-year-old woman presents with a 4-week history of low back pain, generalized weakness, and a 15-lb weight loss over the last 2 months. Her medical history is unremarkable, and her examination is normal except that she is generally weak. Initial laboratory tests reveal an elevated sedimentation rate, mild anemia, creatinine level 1.8 mg/dL, and calcium level 11.2 mg/dL. Which of the following is the most likely diagnosis?

- A. Osteoporosis with compression fractures
 - B. Renal failure with osteodystrophy
 - C. Multiple myeloma
 - D. Lumbar strain
 - E. Osteomyelitis
-

4. A 45-year-old man complains of decreased sensation in his buttocks and inability to achieve an erection. On examination he has decreased anal sphincter tone and decreased ankle reflexes bilaterally. Which of the following is the best next step in management?

- A. Bedrest and follow-up in 4 to 6 weeks
- B. Plain film X-ray of lumbosacral spine
- C. Sedimentation rate and complete blood count
- D. Immediate referral for surgical decompression

Answers

1.A. Bedrest has not been shown to improve outcome in idiopathic low back pain compared to encouraging usual activities that do not exacerbate the pain. Imaging is not necessary with uncomplicated back pain.

2.B. The patient's country of origin, the chronic and slowly progressive nature of the pain in

association with fever, and night sweats are highly suggestive of tuberculous osteomyelitis of the spine, or Pott disease. Bacterial osteomyelitis presents more acutely, often with high, spiking fevers. Metastatic breast cancer and multiple myeloma are extremely rare in this age group. The fevers, night sweats, and persistent and progressive nature of her back pain make a musculoskeletal cause unlikely.

3.C. This patient has many "red flag" symptoms in her presentation: her age, new onset pain, and history of weight loss. The elevated calcium level and mild renal failure are classic for multiple myeloma. Plain radiographs of the spine and, more likely, of the skull may illustrate the punched out lytic bone lesions often seen in this disease. Bence Jones proteins in the urine is also a finding in multiple myeloma.

4.D. This individual has cauda equine syndrome, and requires immediate surgical decompression to avoid long-term nerve denervation and incontinence/lower extremity weakness. The decreased anal sphincter tone and decreased ankle reflexes indicate a peripheral neuropathy. Bedrest with follow-up is indicated when no "red flag" symptoms and signs are present. The plain film X-ray is often normal in patients with cauda equine syndrome.

Clinical pearls

> In 90% of patients, acute low back pain, even with sciatic nerve involvement, resolves within 4 to 6 weeks.

> Analgesics, such as nonsteroidal anti-inflammatory drugs or narcotics, muscle relaxants, and attempts at maintaining some level of activity are helpful in managing acute low back pain; bed rest does not help.

> Pain that interferes with sleep, significant unintentional weight loss, or fever suggests an infectious or neoplastic cause of back pain.

> Imaging studies, such as magnetic resonance imaging, are useful only if surgery is being considered (persistent pain and neurologic symptoms after 4 to 6 weeks of conservative care in patients with herniated disks) or if a neoplastic or inflammatory cause of back pain is being considered.

ANSWERS TO CASE 2:

What is the most likely diagnosis?

This patient has many features of seronegative spondyloarthropathy. Ankylosing spondylitis is the most likely diagnosis in this patient with no history of IBD, genital symptoms, or psoriasis. This condition occurs most frequently in men between the ages of 20 and 30 years. The next step is to obtain plain radiographs of the spine. The characteristic findings on plain radiographs are fusion of lumbar vertebrae ("bamboo spine") and bilateral sacroiliitis (Fig. 2-1).

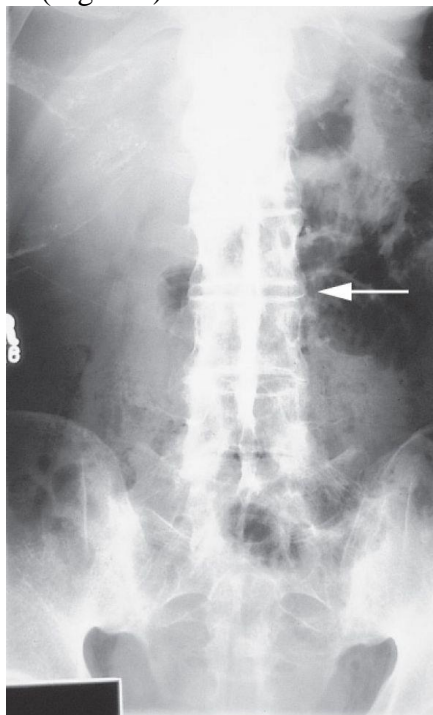


Figure 2-1. X-ray vertebrae: Bamboo spine of ankylosing spondylitis.

Ulcerative colitis is a risk factor for ankylosing spondyloarthropathy. IBD-associated arthritis may be part of the spectrum of ankylosing spondyloarthropathy.

Schober test: Have the patient stand erect. Mark L5 and the spot 10-cm above L5 with a pen. Ask the patient to bend. The patient has decreased range of motion if the distance between the two marks is <14 cm.

What would be the next step in management if plain films are nondiagnostic?

Obtain MRI and HLA-B27 if plain films are nondiagnostic but clinical suspicion is high.

How is ankylosing spondylitis treated?

First-line therapy is NSAIDs, physical therapy, and smoking cessation (ankylosing spondyloarthropathy can cause decreased chest expansion). If the patient continues to have intolerable symptoms, consider SSZ for peripheral joint-predominant symptoms and anti-tumor necrosis factor drugs for axial-predominant symptoms. Consider surgical referral in patients with severe joint deformities.

ANSWERS TO CASE 3:

What is the most likely diagnosis?

This young patient does not have any alarm findings for fracture, infection, malignancy, or progressive neurological compromise (Table 3–1). Nonspecific soft-tissue strain (lumbago) is the most common cause in such patients. Back pain in lumbago may radiate to the buttocks but not to the thighs or legs.

Table 3–1. Alarm findings in low back pain

Alarm findings for infection
1. Systemic signs like fever, chills, or weight loss
2. Symptoms of urinary tract infection
3. IV drug use
4. Immunosuppression
Alarm findings for cancer (primary or metastasis)
1. Systemic signs like fever, chills, or weight loss
2. History of cancer
3. Age >50 years or <20 years
4. ↑ Pain at night or in the supine position
Alarm findings for cauda equina syndrome
1. Progressive or bilateral neurologic/motor deficits
2. Saddle anesthesia (numbness in groin and upper inner thighs)
3. Decreased anal sphincter tone
4. Bowel or bladder retention and/or incontinence
Alarm findings for vertebral fracture
1. Major trauma (e.g., motor vehicle accident, fall from height)
2. Minor trauma in a patient with risk factors for osteoporosis
3. Chronic corticosteroid use

What is the next step in management?

The next step is conservative therapy:

- Analgesics: Take on a regular schedule rather than on demand. Options include NSAIDs, acetaminophen, or muscle relaxants such as cyclobenzaprine.
- Activity: Continue regular activity as tolerated. Consider low-stress aerobic exercise (e.g., walking or swimming). Avoid lifting heavy objects and avoid prolonged bed rest.

Back pain is the fifth most common cause of physician visits. Most cases are benign and self-limiting (90% resolve in 4 weeks with conservative therapy).

Spinal manipulation: Chiropractic manipulation is as effective as conservative therapy.

The patient returns 4 weeks later. His symptoms have not resolved despite conservative therapy. Physical exam and vital signs are normal.

If symptoms persist despite 4 weeks of conservative therapy, obtain ESR and x-rays of the spine (see Fig. 9-12).

ESR and plain radiographs are normal. The patient continues to have intermittent pain over the next 3 months.

How are such patients treated?

Consider the following measures to treat chronic back pain (duration >12 weeks):

- Analgesics: first-line analgesics are NSAIDs or acetaminophen. Avoid opiates if possible because of the risk of side effects and dependence.
- Activity: Adopt back protection strategies and begin an aerobic exercise program. Consider physical therapy if symptoms persist despite these measures.
- Monitor: Monitor the patient for worsening pain, neurological compromise, or the development of other alarm findings.

Back protection strategies: Examples of the numerous strategies include (a) strengthen abdominal muscles, (b) avoid prolonged sitting or standing, (c) avoid bending when lifting a heavy object, (d) use a medium to firm mattress and sleep on one side.

ANSWERS TO CASE 4:

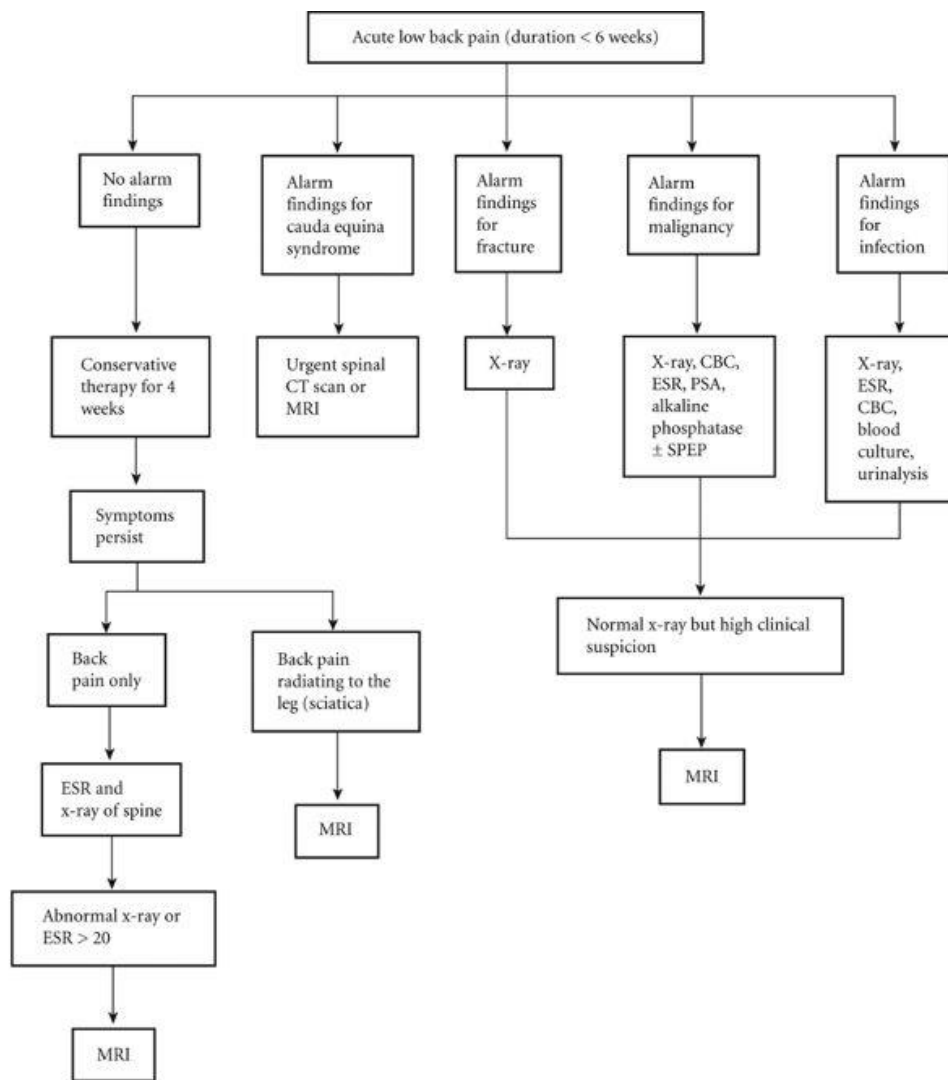
What is the differential diagnosis?

Back pain that radiates to the back of the thigh and/or calf is called sciatica (lumbar radiculopathy). Pain may increase with sneezing, cough, or valsalva. Symptoms usually occur in older patients with disk degeneration or trauma due to compression of lumbar or sacral nerve roots. The major causes of sciatica are:

- Herniated disc
- Spinal stenosis and spondylolisthesis
- OA (degenerative disc disease in which osteophytes impinge on nerve roots).
- SLR: The patient lies supine. Raise symptomatic leg with knee kept straight. Pain in ipsilateral leg at 30° to 60° is sensitive but not specific for sciatica.
- Contralateral SLR: Perform SLR on asymptomatic leg. Pain in ipsilateral symptomatic leg is specific but not sensitive for lumbar disc herniation.

What is the next step in management?

Initial management of sciatica in the absence of alarm findings is conservative therapy. Consider MRI if symptoms do not resolve despite 4 weeks of conservative therapy (Fig. 4-1). MRI is also indicated if the patient develops bilateral or progressive neurological findings.



CT scan is a less accurate alternative to MRI in patients who are claustrophobic or have implanted metallic objects like pacemakers.

Figure 4–1. Initial diagnostic approach to acute low back pain.

The patient's symptoms do not improve with conservative therapy. MRI is obtained (Fig. 4-2).

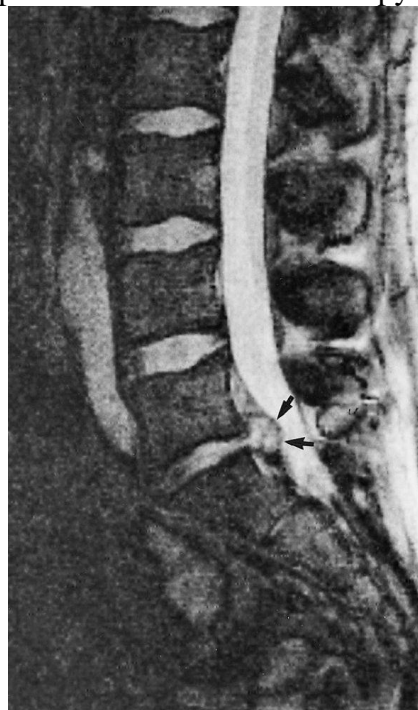

Figure 4–2. MRI: L4–L5 herniation.

What is the diagnosis?

The patient has lumbar disc herniation at L4–L5 (Table 4-1). Herniation of the nucleus pulposus through a weakened annulus fibrosis typically causes pain that is worse with back flexion (bending or sitting) and improves with extension (standing or walking). L4–L5 is the most frequent site of herniation. MRI is the gold standard for diagnosis. Consider surgery (discectomy) if the patient has severe disabling pain or develops signs of cauda equina syndrome. Otherwise, treat chronic back pain as described earlier.

Table 4–1. Neurological exam in lower back pain

Nerve Root	Disc	Motor (weakness)	Sensory (numbness)	Reflexes
L3–L4	L4	Difficulty flexing knee (quadriceps flexion)	Numbness at quadriceps	↓ Knee jerk
L4–L5	L5	Difficulty walking on heels (ankle dorsiflexion) or positive Trendelenburg test a	Numbness over great toe	↓ Posterior tibial reflex
L5–S1	S1	Difficulty walking on toes (ankle plantarflexion)	Numbness at lateral malleolus	↓ Ankle jerk

a Tests hip abductors. Patient stands on one leg. Test is positive if opposite pelvis drops.

Disc herniation is a common incidental finding. Do not treat asymptomatic patients.

What condition would you diagnose if Figure 4 -3 were the patient's MRI?

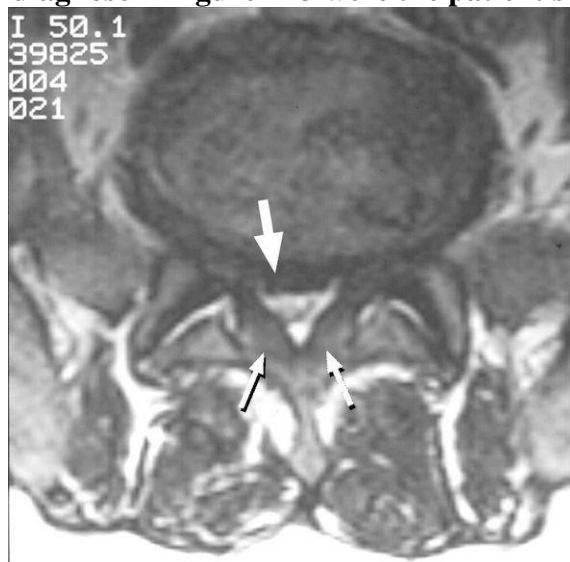

Figure 4–3. MRI: spinal stenosis.

MRI shows the characteristic “trefoil” or “cloverleaf” pattern of spinal stenosis due to hypertrophy of the lamina and pedicles. In addition to back pain, patients often experience lower extremity burning or cramping with ambulation that resolves with rest (pseudoclaudication). Unlike lumbar disc herniation, symptoms increase with back extension and improve with flexion (mnemonic: “STANding worsens STANosis”). Consider surgery (laminectomy) if the patient has severe disabling pain or develops signs of cauda equina syndrome. Otherwise, treat chronic back pain as described earlier.

- Ischemic claudication: Symptoms don't change with flexion or extension.
- Pseudoclaudication: No decreased pedal pulse, impotence, cyanosis, pallor, or nail bed changes.

Type 3 spondylolisthesis: Degenerative conditions like OA predispose to spinal instability, which can cause a vertebra to slip anteriorly and narrow the spinal canal. Symptoms and management are similar to spinal stenosis.

What condition should you suspect if a patient with sciatica has no abnormal findings on MRI, the pain is worse in a sitting position, and the patient reports increased sciatic notch and buttock pain on hip flexion, adduction, and internal rotation?

Consider the diagnosis of piriformis syndrome after other causes of sciatica have been ruled out. This condition occurs when the piriformis compresses the sciatic nerve as it traverses the muscle. Like disc herniation, symptoms are typically worse in the seated position. Electrophysiological testing or the FADIR maneuver may elicit positive findings (increased sciatic notch and buttock pain on Flexion, ADduction, and Internal Rotation of the hip against resistance). Treatment is usually conservative (physical therapy).

Consider corticosteroid injections into the piriformis muscle for refractory debilitating symptoms. Surgical resection of the piriformis muscle or tendon is a last resort measure.

ANSWERS TO CASE 5:

What is the differential diagnosis?

Bilateral neurological deficits and decreased anal sphincter tone are alarm findings for cauda equina syndrome. This syndrome results from compression of the thecal sac below the level of the spinal cord (L1–L2). Compression above L1 is called epidural spinal cord compression (ESCC). Because clinical manifestations and management of both conditions are similar, the terms are often used interchangeably. The major causes of cauda equina syndrome and ESCC are:

- Malignancy (primary or metastasis): most likely cause in this patient
- Musculoskeletal disorders
- Infection (spinal epidural abscess)
- Traumatic injury to the spinal cord

Prostate, breast, and lung cancer are the most common tumors to metastasize to vertebrae.

What is the next step in management?

Obtain emergent MRI in any patient with alarm findings for cauda equina syndrome or ESCC. This patient with a history of cancer should also receive IV corticosteroids prior to imaging (reduces swelling around the spinal cord).

MRI detects a metastatic lesion. What is the next step in management?

Refer the patient for emergent surgery to prevent further neurological deficits. If the patient is not a surgical candidate, treat with radiation therapy instead.

ANSWERS TO CASE 6:

What is the next step in management?

Fever and history of urinary tract infection are alarm findings for infection. Localized back tenderness is the most frequently elicited sign in vertebral osteomyelitis. Many patients also have reduced back mobility. Hematogenous spread is the most common mode of infection. The next step is to obtain x-rays of the spine, CBC, ESR, and urinalysis.

Vertebral osteomyelitis epidemiology: Most patients are >50 years old. Incidence is much greater in men for unknown reasons.

Laboratory studies demonstrate leukocytosis with a left shift and elevated ESR. Radiographs show destruction of L2 and L3 vertebral bodies and decreased disk space between L2 and L3. Blood cultures are negative.

The radiographs findings are characteristic for vertebral osteomyelitis. The next step is CT-guided needle biopsy of the affected bone to determine the causative microbe.

Positive x-ray and blood cultures: Consider foregoing needle biopsy and proceeding directly to treatment.

How is vertebral osteomyelitis treated?

When blood cultures or needle aspiration identify the causative microbe, treat with a 6- to 12-week course of IV antibiotics. Patients with a good response to IV antibiotics can switch to oral antibiotics after 2 weeks. Consider surgery if the patient develops signs of cauda equine syndrome or infection continues to progress despite appropriate antibiotics.

What additional test would have been indicated if the patient were an IV drug user or had a murmur on physical exam?

Perform echocardiography to rule out infective endocarditis as the source of osteomyelitis in the following patients:

- History of heart disease or new murmur on physical exam
- Recent IV drug use
- *S. aureus* detected on blood cultures or CT-guided biopsy.

What would have been the next step if x-ray were normal?

Plain radiographs are often negative in the first 2 weeks. MRI would have been the next step in this patient with a high pretest probability of osteomyelitis. If MRI is positive, perform CT-guided needle biopsy of the affected bone.

What would have been the next step if CT-guided needle biopsy was negative?

Repeat CT-guided needle biopsy. If repeat biopsy is also negative, consider empiric IV antibiotics.

What would have been the initial diagnostic test if the patient presented with fever, back pain, altered mental status, and decreased knee jerk reflex?

Fever, back pain, and neurological deficits are the classic triad of spinal epidural abscess. MRI is the preferred initial diagnostic test. Confirm an MRI-detected abscess with needle aspiration. First-line therapy is surgical drainage and IV antibiotics.

ANSWERS TO CASE 7:

Where is the primary site of disease in AS?

In AS, inflammation occurs at the insertion of a ligament, tendon, or articular capsule into bone, a structure known as the enthesis. The cause of this localized inflammation remains unknown. Sites of enthesopathy in AS include the sacroiliac joints; ligamentous structures of the intervertebral discs, manubriosternal joints, and symphysis pubis; ligamentous attachments in the spinous processes, the iliac crests (whiskering), trochanters, patellae, clavicles, and calcanei (Achilles enthesitis or plantar fasciitis); and capsules and intracapsular ligaments of large synovial joints. Inflammation can also be seen in the synovium, the tissue lining the joints.

What organs can be involved in AS, and what are the clinical manifestations?

Ocular involvement presents as anterior uveitis (25% to 40% of patients); secondary glaucoma and cataracts can also occur. Cardiac involvement includes aortic insufficiency, aortitis, conduction abnormalities, diastolic dysfunction, and pericarditis. Pulmonary involvement includes upper lobe fibrosis and restrictive changes. Renal involvement includes IgA nephropathy, secondary amyloidosis, and chronic prostatitis. Peripheral joint involvement (particularly hips and shoulders) can occur in approximately 30% of patients. Significant spinal osteoporosis can occur. Neurologic involvement includes atlantoaxial subluxations and cauda equina syndrome.

What are three characteristic clinical findings in patients with AS that help distinguish it from RA?

The three clinical manifestations characteristic of AS are inflammatory arthritis of the spine, Achilles tendinitis, and plantar fasciitis. These three findings are extremely rare in patients with RA.

What is the characteristic family history, gender incidence, and HLA pattern found in the context of AS?

Typically, there is a family history of AS, particularly in male family members. In fact, it occurs more commonly in men than women (3:1). This disease is very highly associated with the presence of HLA-B27. Two percent of HLA-B27 positive persons develop AS. Among those HLA-B27 positive persons with an affected first-degree relative, the rate rises to 15% to 20%.

What types of treatment are helpful in AS?

The treatment of AS includes nonsteroidal antiinflammatory drugs (NSAIDs), extension exercises for the back, and physical therapy. It is recommended that all three forms of therapy be used in affected patients. It is thought that extension exercises for the back may help patients maintain a more normal upright posture as the back fuses over time. Sulfasalazine or low-dose weekly methotrexate (MTX) therapy may be beneficial in patients having progressive disease with peripheral arthritis but does not alter the sacroiliitis. Oral corticosteroids are of no value. Local corticosteroid injections may be useful in the treatment of enthesopathies and recalcitrant peripheral synovitis. The tumor necrosis factor O± (TNF-O±) blocking drugs are very effective in AS, act on both spinal and peripheral joints, and may possibly delay or prevent spinal ankylosis (treatment results in improvement in magnetic resonance imaging (MRI) appearance of enthesitis and sacroiliitis). The use of anti-TNF agents should be considered in patients with active AS who have failed to respond to two or more NSAIDs for axial disease and one or more disease-modifying antirheumatic drug (DMARD) for peripheral arthritis.

CASE DISCUSSION

What are three possible causes of LBP in young men?

Three possible causes of back pain in young men include lumbosacral muscle spasm, a ruptured intervertebral disc, and AS or another seronegative spondyloarthropathy. Forms of common autoimmune and chronic inflammatory diseases, such as rheumatoid arthritis (RA) or systemic lupus erythematosus

(SLE), rarely involve the joints of the low back. Therefore, LBP is not one of the initial symptoms of these disorders.

What features in the history and physical examination are helpful in differentiating inflammatory LBP in AS from mechanical LBP?

Table 7.1. Differentiation inflammatory LBP in AS from mechanical LBP

	Inflammatory LBP	Mechanical LBP
Age at onset	<40 y	Any age
Type of onset	Insidious	Acute
Symptom duration	>3 mo	<4 wk
Morning stiffness	>60 min	<30 min
Nocturnal pain	Frequent	Absent
Effect of exercise	Improvement	Exacerbation
Sacroiliac joint tenderness	Frequent	Absent
Back mobility	Loss in all planes	Abnormal flexion
Chest expansion	Often decreased	Normal
Neurologic deficits	Unusual	Possible

LBP, low back pain.

What five diseases are classified as seronegative spondyloarthropathies?

The spondyloarthropathies consist of AS, reactive arthritis (formerly known as Reiter's syndrome), psoriatic arthritis, arthritis secondary to inflammatory bowel disease, and undifferentiated spondyloarthropathy.

What is the definition of sciatica, and what are three possible causes of it?

Sciatica is defined as back pain that radiates laterally down one leg below the knee. The pain is usually sharp or burning. Sciatica usually occurs as a consequence of lumbar spondylosis (degenerative disc or facet joint disease) and can be associated with a ruptured intervertebral disc or an idiopathic sciatic nerve irritation. Infectious, neoplastic, and infiltrative disorders should always be considered.

ANSWERS TO CASE 8:

A 59-year-old woman complains of a 3-week history of severe right- side headaches that are worse at night, when she lies with that side of her head on the pillow. Her medical history is significant for hypertension and “arthritis” of her neck, shoulders, and hips, for which she takes ibuprofen. She has a temperature 100.4°F and normal neurologic and eye examinations. She has moderate tenderness over the right side of her head but no obvious scalp lesions.

- > Most likely diagnosis: Temporal arteritis (TA).
- > Best next step to confirm diagnosis: Erythrocyte sedimentation rate (ESR).

ANALYSIS

Considerations

Although headaches are a very common complaint, this patient has features that are of greater concern: older age of onset, abrupt onset and severe intensity, and dissimilarity to previous milder headaches. These are three of the nine factors of concern for significant underlying pathology outlined in Table 8 -1. She is very concerned about the headaches and is worried that they indicate a brain tumor. She has no meningeal signs and her neurologic examination is nonfocal.

Table 8-1. Red flags for secondary headache disorder

- Fundamental change or progression in headache pattern
- First severe and/or worst headache
- Abrupt-onset attacks, including those awakening one from sleep
- Abnormal physical examination findings (general or neurologic)
- Neurologic symptoms lasting >1 h
- New headache in individuals aged <5 y or >50 y
- New headache in patients with cancer, immunosuppression, pregnancy
- Headache associated with alteration in or loss of consciousness
- Headache triggered by exertion, sexual activity, or

She has stiffness and achiness of the shoulder and hip girdles. Together these factors make the

diagnosis of TA a strong possibility. TA usually has its onset in patients aged 50 years or older (females more than males), and involves inflammation of the medium- or large-size vessels. Her low-grade fever and generalized body aches may represent polymyalgia rheumatica, which is closely associated with TA. The diagnosis would be suggested by an elevated ESR, and then confirmed by temporal artery biopsy. Although TA is not a common cause of headache, untreated patients often progress to permanent visual loss as a consequence of involvement of the ophthalmic artery, so a high index of suspicion is necessary to begin investigation. An elevated ESR necessitates further diagnostic testing, such as a temporal artery biopsy. In the meantime, empiric corticosteroids may help prevent complications.

APPROACH TO HEADACHES

Definitions

TEMPORAL ARTERITIS (TA): Also known as giant cell arteritis (GCA), temporal arteritis is a common form of systemic vascular inflammation affecting patients older than 50 years. Medium- and large-sized vessels especially the superficial temporal artery are affected.

BERRY ANEURYSM: A small outpouching that looks like a berry and classically occurs at the point at which a cerebral artery departs from the circular artery (the circle of Willis) at the base of the brain. They can rupture causing subarachnoid hemorrhage.

Clinical approach

Headache is one of the most common complaints of patients in the western world. It periodically afflicts 90% of adults, and almost 25% have recurrent severe headaches. As with many common symptoms, a broad range of conditions, from trivial to life-threatening, might be responsible. The majority of patients presenting with headache have tension-type, migraine, or cluster; however, fewer than 1 in 20 have significant underlying pathology. Because headache symptoms usually are accompanied by a paucity of associated findings, including those on laboratory examination, the clinician must depend largely upon a thorough history with a general and focused neurologic examination as the initial workup. Careful inquiry and meticulous physical examination, keeping in mind the “red flags” of headaches (Table 50-1), will serve the clinician well. Differentiating serious underlying causes of headache from more benign causes may be difficult. Table 8 -2 lists some typical features of serious causes of headache.

Table 8 -2. Causes of pathologic headaches

Disease	Clinical features	Diagnostic findings
Meningitis	Nuchal rigidity, headache, photophobia, and prostration; may not be febrile	Lumbar puncture is diagnostic
Intracranial hemorrhage	Nuchal rigidity and headache; may not have clouded consciousness or seizures	Hemorrhage may not be seen on CT scan; lumbar puncture shows 'bloody tap' that does not clear by the last tube; a fresh hemorrhage may not be xanthochromic
Brain tumor	May present with prostrating sounding headaches that are associated with nausea and vomiting; should be suspected in progressively severe new 'migraine' that is invariably unilateral	CT or MRI
Temporal arteritis	May present with a unilateral pounding headache; onset generally in older patients < 50 y) and frequently associated with visual changes	Erythrocyte sedimentation rate is the best screening test and usually is markedly elevated (ie, >50 mm/hr); definitive diagnosis can be made by arterial biopsy
Glaucoma	Usually consists of severe eye pain; may have nausea and vomiting; the eye usually is painful and red; the pupil may be partially dilated	Elevated intraocular pressure
Migraine headache	Unilateral throbbing headache with preceding aura, photophobia, and nausea, which is relieved with sleep	
Cluster headache	Male predominance; precipitated by alcohol; occurs with rhinorrhea and lacrimation	

Tension headache	Occipital-frontal headache; constant/"bandlike"; relieved with relaxation	
-------------------------	---	--

One of the most catastrophic secondary causes of headache is subarachnoid hemorrhage, usually secondary to a ruptured intracerebral (berry) aneurysm. Up to 4% of patients presenting to an emergency center with severe headache, or the classic "worst ever headache," have a subarachnoid bleed. The initial hemorrhage may be fatal, may result in severe neurologic impairment, or may produce only minor symptoms such as headache. A high index of suspicion is needed because no neurologic findings may be present initially, and the patient who will benefit the most from intervention will often have the mildest symptoms. The first diagnostic study should be a noncontrast CT scan with thin imaging cuts at the region of the brain base. This study will be positive in more than 90% of cases on the first day, with decreasing sensitivity over the next several days. If hemorrhage is suspected but the CT is negative, lumbar puncture should be performed as soon as possible to assess for the presence of red cells or xanthochromia (yellowish discoloration of cerebrospinal fluid [CSF]); this finding indicates presence of bilirubin and differentiates subarachnoid hemorrhage from a traumatic lumbar puncture.

Giant cell arteritis, or temporal arteritis (TA), is a chronic vasculitis of large- and medium-size vessels, usually involving the cranial branches of the arteries arising from the aortic arch. The clinical criteria for diagnosis include age of onset older than 50 years, new onset or type of headache pattern, tenderness or decreased pulsation of the temporal artery, elevated ESR, and abnormal findings on biopsy of the temporal artery. The presence of three or more criteria yields more than 90% sensitivity and specificity for the diagnosis. TA is closely related to polymyalgia rheumatica (PR), a condition associated with bilateral aching and stiffness of neck, torso, shoulders, or proximal parts of the arms and thighs, as well as an elevated ESR. Both conditions probably are polygenic diseases in which various environmental and genetic factors influence susceptibility and severity. Clinical symptoms may include jaw claudication, and the most worrisome complication is permanent or partial loss of vision in one or both eyes, which can occur as an early manifestation in up to 20% of patients. Temporal artery biopsy is recommended in all patients suspected of having TA, and long segments of the artery may require excision in order to find the typical areas of segmental inflammation. Corticosteroids are the drugs of choice to treat both polymyalgia rheumatica and TA, with daily doses of 10 to 20 mg of prednisone for polymyalgia rheumatica and 40 to 60 mg for TA. Steroids may prevent, but usually do not reverse, visual loss. Steroid dosage is gradually tapered, but relapse is common, as are complications of corticosteroid therapy.

Migraine headache is much more common than TA but is more variable in its presentation. It is the most common cause of initial office visits for headache because of its frequency, disabling qualities, and associated multiorgan symptoms. Migraine attacks are more common in women than in men. Migraine attacks may or may not have a preceding aura, may be unilateral or bilateral, and may have either throbbing or nonpulsatile pain, including the neck. They may have cranial autonomic features such as tearing or nasal congestion, leading to the misdiagnosis of sinus disease. A number of evidence-based guidelines are available for managing migraine headaches. In general, preventive therapies include tricyclic antidepressants and beta-blockers. Treatment of acute episodes involves the initial use of nonsteroidal antiinflammatory drugs (NSAIDs), followed by dihydroergotamine or sumatriptan if symptoms persist.

Episodic cluster headache is much less common, but it is more easily diagnosed by its distinctive pattern of periodic attacks of intense, unilateral, periorbital pain with nasal or ocular watering lasting only minutes to hours but recurring daily over several weeks or months. Acute attacks can be treated with oxygen or subcutaneous sumatriptan.

Comprehension questions

Match the headache type (A-E) to the clinical presentation described in Questions [50.1] to [50.3].

- A. Common migraine headache
- B. Classic migraine headache
- C. Cluster headache
- D. Subarachnoid hemorrhage
- E. Meningitis

1. A 42-year-old man with polycystic kidney disease who complained of a sudden onset of severe headache and then lost consciousness

2. A 22-year-old college student with fever, headache, photophobia, and 25 white blood cells per high-power field but no red blood cells or xanthochromia in CSF

3. A 31-year-old woman with a long history of intermittent severe unilateral headache lasting hours to days associated with nausea and photophobia, but no preceding symptoms and no visual disturbance

Answers

1.D. The sudden onset of severe headache with diminution in level of consciousness is classic for subarachnoid hemorrhage. This patient likely had rupture of a cerebral artery aneurysm, which is associated with polycystic kidney disease.

2.E. The presence of white blood cells but no red blood cells in the CSF is indicative of meningeal inflammation, likely due to viral or bacterial infection.

3.A. The patient's history is strongly suggestive of migraine (common type), which is not associated with a preceding aura or visual symptoms as seen in classic-type migraine.

Clinical pearls

> Temporal arteritis usually involves one or more branches of the carotid artery and almost always occurs in patients older than 50 years. Diagnosis is suggested by an elevated erythrocyte sedimentation rate and confirmed by temporal artery biopsy.

> Visual loss is a common complication of temporal arteritis and can be prevented by initiation of high-dose corticosteroids when the diagnosis is suspected.

> Subarachnoid hemorrhage typically presents as a sudden onset of severe headache and is diagnosed by visualization of blood on a computed tomographic (CT) scan or by finding red blood cells or xanthochromic fluid on a lumbar puncture.

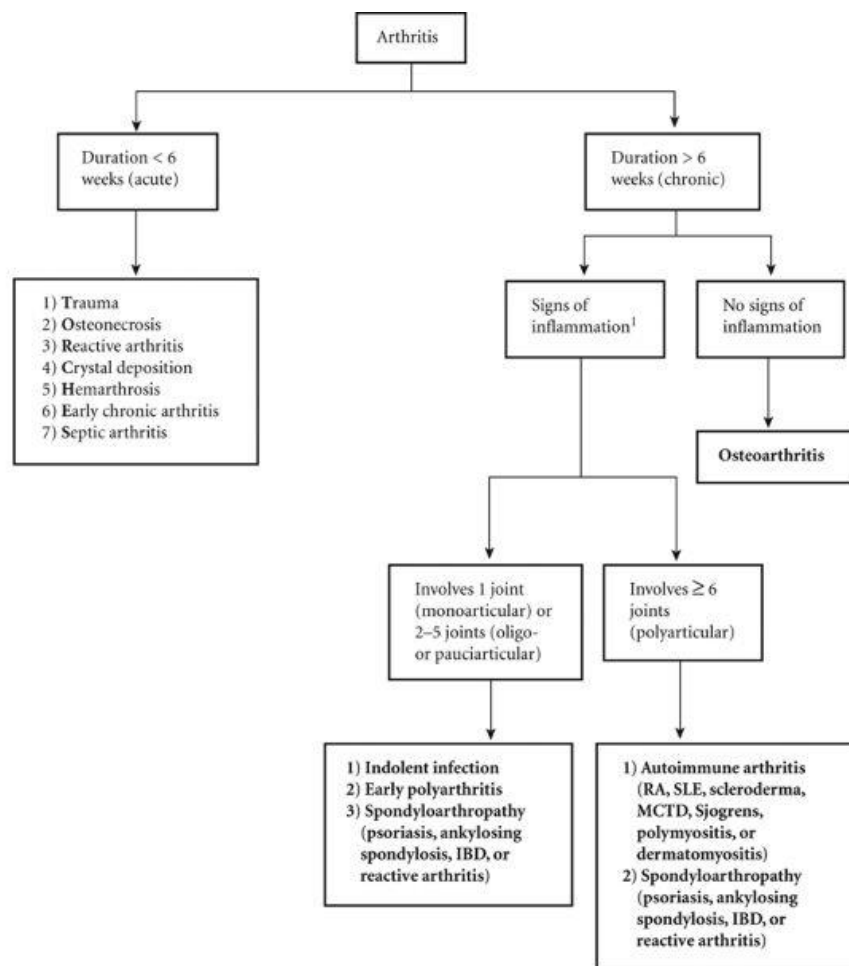
> Migraine is the most common type of headache for which patients seek medical attention in an office setting. The classic variety has a preceding aura, whereas the common type does not.

ANSWERS TO CASE 9:

What is the most likely diagnosis?

Chronic polyarticular pain with features of inflammatory arthritis is most commonly caused by an autoimmune arthritis or spondyloarthropathy. This patient with symmetric involvement of the MCPs and PIPs meets diagnostic criteria for rheumatoid arthritis (RA). Patients must meet four of seven criteria (mnemonic: Rheumatoid Hands Require Some PM&R):

- Rheumatoid nodules: freely moving subcutaneous nodules on bony prominences
- Hand joint symptoms (wrist, MCP, PIP) for ≥ 6 weeks
- Rheumatoid factor (RF): IgM RF sensitive (positive in 70% to 80%) but not specific
- Symmetric joint involvement for ≥ 6 weeks
- Pain in three or more joints for ≥ 6 weeks
- Morning stiffness that lasts ≥ 60 minutes for ≥ 6 weeks
- Radiographic findings: joint space narrowing; bone and cartilage erosions



¹Signs of inflammation include (a) morning stiffness > 30 minutes (b) ↓ Pain with activity (c) tender, swollen, or boggy joint
Adapted from Sabatine M. Pocket medicine 2nd edition

Figure 9–1. Diagnostic approach to arthritis.

This patient with symmetric involvement of the MCPs and PIPs meets diagnostic criteria for rheumatoid arthritis (RA) (Table 9-1). In this condition, an autoimmune lymphocytic infiltrate in the synovium forms a pannus. Pannus growth destroys joint cartilage and bone.

Table 9–1. Classification of rheumatoid arthritis

	Mild	Moderate	Severe
No. of involved joints	<6	6–20	>20
Extra-articular	No	No	Yes
Functional disability a	Mild	Moderate	Severe
RF and anti-CCP	(+) or (–)	(+)	(+)
ESR, CRP	Negative	Occasionally positive	Often positive
X-ray	Normal	Periarticular swelling ± mild joint space narrowing and erosions	Substantial joint space narrowing and erosions ± joint malalignment

Abbreviations: CCP, anti-cyclic citrullinated peptide; CRP, C-reactive protein; ESR, erythrocyte sedimentation rate; RF, rheumatoid factor.

a Assessed using questionnaires such as Stanford Health Assessment Questionnaire.

Rheumatoid arthritis (RA) diagnostic dilemmas:

- There is no single clinical or laboratory feature that is diagnostic of RA.
- Patients with early-stage RA may not meet diagnostic criteria.
- Laboratory and imaging tests are often negative in early-stage RA.

Features of chronic inflammatory arthritis:

- Symptoms: Morning stiffness >30 minutes, decreased joint pain with activity
- Signs: Tender, boggy, swollen joint
- Laboratory features: ↑ Erythrocyte sedimentation rate (ESR) and ↑ C-reactive protein (CRP)

What factors increase the risk of developing RA?

Both genetic and environmental factors are involved in RA pathogenesis. Known risk factors are HLA-DR1 and HLA-DR4, female sex, smoking, and positive family history. Typical age of onset is 20 to 40 years of age.

Autoimmune arthritides are also collectively referred to as connective tissue disorders. All connective tissue disorders are more common in women.

The patient asks about her long-term prognosis.

What should you tell her?

- Approximately 80% of patients have episodes of exacerbations (active disease) and remissions.
- Approximately 10% have a single episode followed by complete remission.
- Approximately 10% have severe, progressive arthritis despite treatment.

Markers of poor prognosis: Erosions on x-ray, rheumatoid nodules, ↑ ESR or CRP, and high-titer RF (e.g., 1:160 is a higher titer than 1:64).

What imaging and laboratory studies are indicated initially?

Obtain the following laboratory and imaging studies to increase diagnostic certainty, assess disease severity, and establish a baseline for comparison:

- X-rays of involved joints
 - Auto-antibodies: Obtain RF ± anti-cyclic citrullinated peptide (anti-CCP). RF is more sensitive, but anti-CCP is more specific. Combination is more sensitive and specific than either test alone.
 - CBC: Patients may have anemia of chronic disease, increased platelets, and increased white blood cells (WBCs).
 - Liver function tests (LFTs) and serum chemistries: Establish baseline because RA drugs can affect liver and kidney function.
 - ESR and CRP: Nonspecific markers of inflammation that are used to monitor disease progression.
- Figure 9-1 is the patient's x-ray. RF and anti-CCP are positive. Remaining tests are normal.

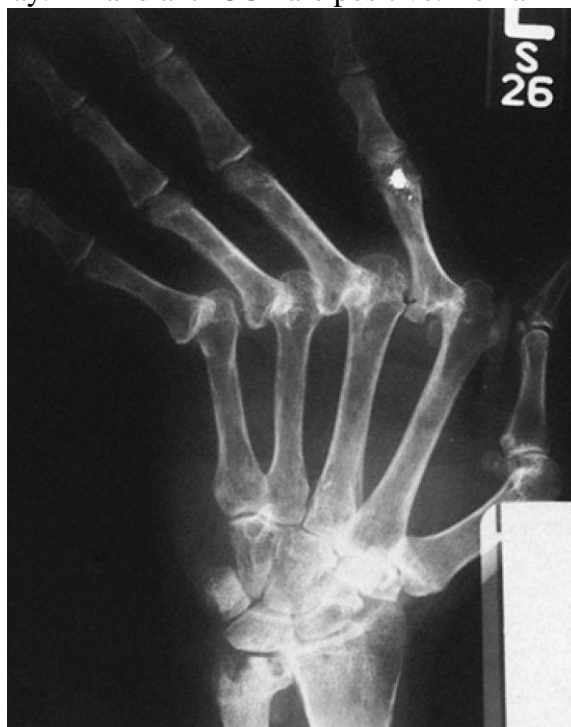

Figure 9–1. X-ray in rheumatoid arthritis showing periarticular swelling but no erosions.

What stage disease does she have?

X-rays demonstrate periarticular swelling but no erosions. This patient with six involved joints, no extra-articular symptoms or joint malalignment, positive autoantibodies, and normal complete blood count (CBC), ESR, and CRP has moderate-stage RA (Tables 9-1, 9-2, and 9-3).

Table 9–2. Extraarticular complications of rheumatoid arthritis

Constitutional
Fatigue, anorexia, and weight loss
Bones

Osteopenia/osteoporosis (additive increased in risk with steroid use)
Muscle
1. Inflammation and disuse atrophy 2. Polymyositis (rare)
Peripheral nerves
Carpal tunnel syndrome and other hand/foot paresthesias
Skin
1. Rheumatoid nodules 2. Neutrophil dermatoses
Eyes
1. Scleritis and episcleritis 2. Sjögren's syndrome
Lungs
1. Pleural effusions 2. Empyema (uncommon; due to rheumatoid nodules in the lungs) 3. Interstitial lung disease
Heart
1. Pericarditis 2. Myocarditis 3. ↑ Risk of heart failure and myocardial infarction 4. Heart block (uncommon; due to rheumatoid nodules in heart)
Blood vessels
Rheumatoid vasculitis
Hematological
Felty's syndrome

Table 9-3. Joint and tendon manifestations in severe or long-standing rheumatoid arthritis

Joint	Clinical Manifestations
Hand and wrists	Mnemonic: “ <i>Fingers BUST</i> ”
	1. Fusiform swelling and tenderness
	2. Boutonnière deformity: hyperflexed PIP and hyperextended DIP
	3. Ulnar deviation: fingers displaced towards the little finger
	4. Swan-neck deformity: hyperextended PIP and hyperflexed DIP
Feet	5. Tendon rupture: causes inability to bend or straighten fingers
	1. Tenderness of the metatarsal joints
	2. Cock-up deformity: toe phalanx articulates at 90° with metatarsal
Elbows	3. Rupture of Achilles tendon: rare; presents with pop or snap followed by sharp pain in back of ankle and inability to walk
	Most common site of rheumatoid nodules
Shoulder	Shoulder stiffness due to adhesive capsulitis (“frozen shoulder”)
Knees	Popliteal (Baker) cyst
Vertebrae	1. Atlanto-axial subluxation
	2. Subaxial subluxation

Abbreviation: DIP, distal interphalangeal; PIP, proximal interphalangeal.

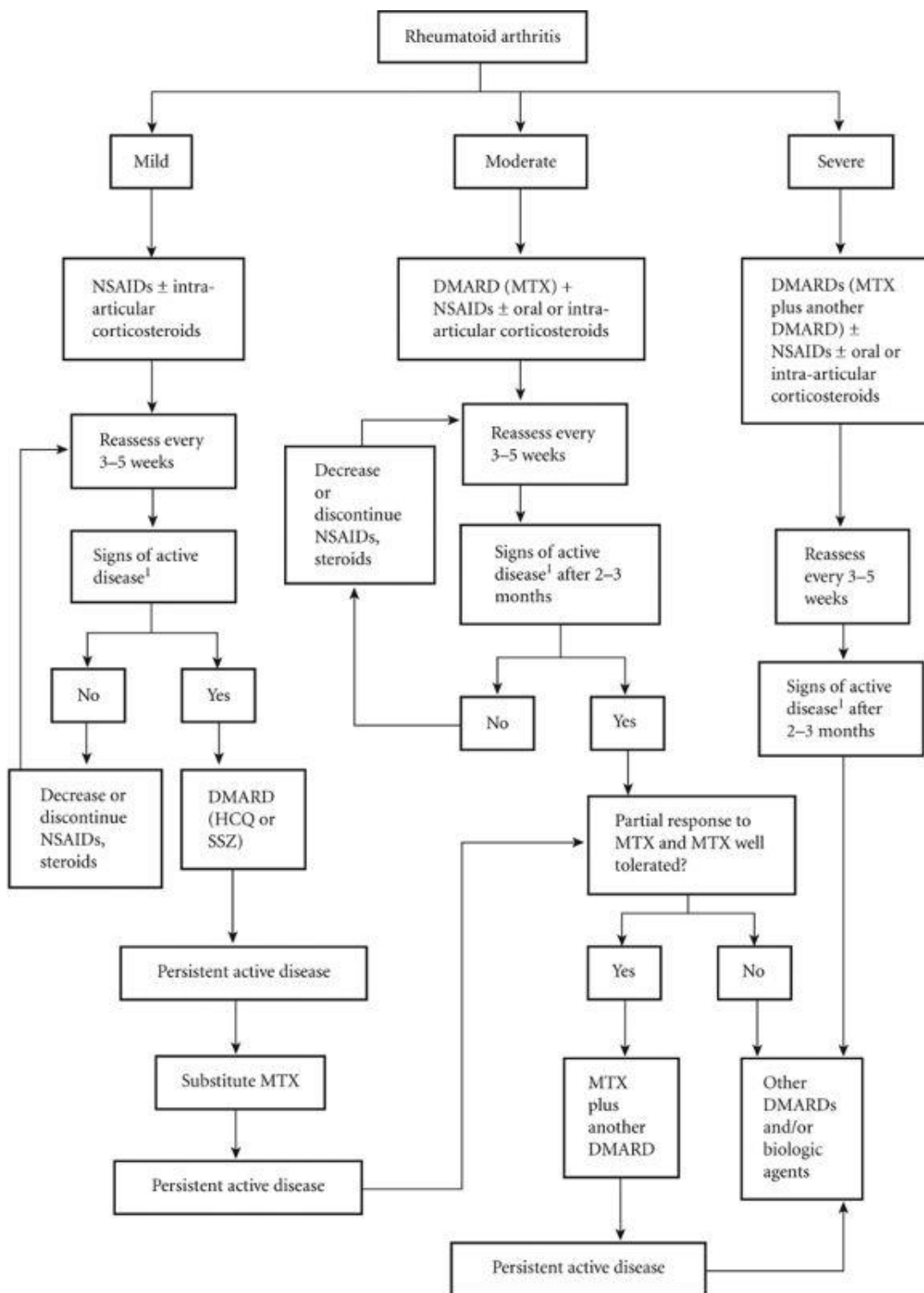
Palindromic RA: Recurrent episodes of oligoarticular inflammatory arthritis that last for hours to weeks and then subside; ESR, CRP, RF, and anti-CCP are usually positive.

How is RA treated?

- Patient education and exercise: Indicated for all patients. Patients with signs of joint deformity (severe RA) should undertake weight-bearing exercise cautiously.

Pharmacotherapy: There are four major drug categories used in RA treatment: nonsteroidal anti-

inflammatory drugs (NSAIDs), corticosteroids, disease-modifying antirheumatic drugs (DMARDs), and biological agents. NSAIDs and steroids rapidly decrease inflammation but do not slow disease progression. DMARDs and anti-cytokine therapies take weeks to months to take effect but can slow disease progression. Therapeutic choices depend on disease severity and the individual patient's response (Fig. 9-2).



¹Physical signs of inflammation, ESR or CRP, progressive erosion on x-ray
 HCQ = hydroxychloroquine, SSZ = sulfasalazine, MTX = methotrexate

Figure 9-2. Therapeutic approach to rheumatoid arthritis.

What are some examples of DMARDs?

- Hydroxychloroquine (HCQ) and sulfasalazine (SSZ): safest side effect profile
- Methotrexate (MTX): relatively rapid effect (4 to 6 weeks)
- Azathioprine, cyclosporine, gold, and leflunomide: less popular because of side effects

What are some examples of biological agents?

- Anti-tumor necrosis factor- α drugs (e.g., Etanercept and Infliximab)
- Anti-interleukin-1 drugs (e.g., Anakinra)
- Anti-CD 20 drugs (e.g., Rituximab)

Combination therapy:

- MTX + azathioprine: Avoid because increased risk of serious febrile reaction.
- MTX + leflunomide: Monitor LFTs monthly.

ANSWERS TO CASE 10:

What is the most likely diagnosis?

This patient with morning stiffness, symmetric joint pain, and elevated ESR but no evidence of arthritis on plain radiographs most likely has polymyalgia rheumatica (PMR). This idiopathic condition almost exclusively affects patients >50 years of age and typically affects the neck, shoulders, and hips.

The term “polymyalgia” is misleading because PMR typically causes joint pain.

How is PMR treated?

First-line therapy for PMR is low-dose oral corticosteroids, which usually causes prompt symptom resolution. Laboratory abnormalities (increased ESR, increased CRP, and anemia of chronic disease) should also revert to normal with steroids.

The patient's symptoms and laboratory abnormalities improve with oral prednisone. Five years later, she presents with a 2-month history of headache, jaw pain, fatigue, and a 10-lb weight loss. Temperature is 38.1°C.

What complication should you suspect?

PMR greatly increases the risk of developing giant cell arteritis (GCA), also known as temporal arteritis. The major clinical manifestations of this large- and medium-vessel vasculitis are systemic symptoms (fever, fatigue, and weight loss), headache (often in the region of the temporal artery), visual loss, and jaw pain. Patients with GCA also have elevated ESR.

- Approximately 10% to 15% of patients with PMR develop GCA.
- Approximately 50% of patients with GCA have PMR.
- Both PMR and GCA are associated with HLA-DR4 (more common in Europeans).

What is the next step in management?

Confirm the suspected diagnosis with temporal artery biopsy. Like PMR, first-line therapy is systemic corticosteroids.

ANSWERS TO CASE 11:

What diagnosis should you suspect?

Although RA is the most common cause of chronic inflammatory polyarthritis, this diagnosis is less likely because RF is negative and the joints are affected in an asymmetric pattern. The additional complaint of photosensitivity should raise suspicion for systemic lupus erythematosus (Table 9-5). A patient must meet four of the 11 diagnostic criteria to receive a diagnosis of lupus (mnemonic: “A RASH POINTs MD to lupus”):

- Arthralgias
- Renal disease: proteinuria or cellular casts
- ANA: positive anti-nuclear antibody
- Serositis: pleuritic chest pain or pericardial friction rub
- Hematologic abnormalities: \downarrow RBCs, \downarrow WBCs, or \downarrow platelets
- Photosensitivity
- Oral ulcers
- Immunological tests: anti-double stranded (ds) DNA, anti-Smith Abs, Leukocyte esterase (LE), Anti-phospholipid Abs (APLA), or false (+) RPR/VDRL
- Neuropsychiatric symptoms: seizures or psychosis
- Malar rash
- Discoid rash

Table 11–1. Important clinical manifestations of systemic lupus erythematosus

RBC, red blood cell; WBC, white blood cell.	
Constitutional	Fever, fatigue, weight loss

Neuropsychiatric	Seizures, psychosis, depression, ↑ risk of thromboembolic stroke
Hair	Alopecia
Eyes	Dry eyes (SS)
Mouth	Nasopharyngeal ulcers
Skin	Malar rash, discoid rash, photosensitivity
Heart	Pericarditis, Libman-Sach's endocarditis, ↑ risk of CHD
Lungs	Pleuritis, interstitial lung disease
Kidneys	Nephrotic or nephritic syndrome
Blood	↓ WBCs, ↓ RBCs, ↓ platelets, ↓ complement, ↑ ESR, ↑ CRP
Musculoskeletal	Migratory asymmetric polyarthritis, myalgias, Raynaud phenomenon

RF is not positive in up to 30% of RA patients, so negative RF does not necessarily rule out RA.

What is the next step in evaluating the possibility of SLE?

The next step is to order ANA. This test is very sensitive test for SLE (most patients have ANA titer $\geq 1:160$).

ANA is 1:32.

What is the next step in management?

ANA is not specific for SLE (often positive in other autoimmune arthritides). Obtain the following tests to establish a baseline as well as to increase diagnostic probability: anti-double-stranded DNA (anti-dsDNA), anti-Smith antibodies, CBC, serum creatinine and urinalysis, LFTs, ESR, and CRP.

Anti-dsDNA and anti-Smith antibodies: specific but not sensitive for SLE.

SLE with negative ANA: <2% to 5% of SLE. Patients often have anti-Ro (anti-SSA) or anti-La (anti-SSB) antibodies.

Discoid lupus: Subtype with discoid erythematous plaques but no other systemic signs of SLE. ANA often negative.

What other diagnostic test would have been indicated if the patient had a 10-year history of hydralazine use?

A number of drugs can cause drug-induced lupus erythematosus (DILE) with long-term use. The most common offenders are hydralazine, procainamide, and quinidine. DILE is associated with all the clinical manifestations of SLE except for neurological and kidney dysfunction. If you suspect DLE, obtain anti-histone antibodies (extremely sensitive and specific). Treatment is to discontinue the offending drug. Prognosis is good.

ANA often positive but anti-dsDNA and anti-Smith antibodies are negative in DILE.

Anti-dsDNA is positive. Serum chemistry is normal.

What initial treatment is indicated?

Consider an NSAID and an anti-malarial (e.g., HCQ) as initial therapy for this patient. NSAIDs are the first-line drug for arthralgias. HCQ is the first-line drug for skin manifestations and second-line therapy for arthralgias.

When are corticosteroids and other immunosuppressive therapies indicated?

Consider corticosteroids and other immunosuppressive medications (cyclophosphamide, mycophenolate) for SLE that involves organ systems like the central nervous system, lungs, or kidneys.

SLE prognosis: Variable course (exacerbations and remissions); can be life-threatening.

The patient's symptoms improve with NSAIDs and HCQ.

What tests should you routinely order to monitor patients with SLE?

Routinely obtain CBC, serum chemistries, urinalysis, LFTs, ESR, and CRP.

The patient wishes to become pregnant at some point in the near future.

What should you recommend?

SLE is not a contraindication to pregnancy, although patients should try to avoid becoming pregnant for at least 6 months after an exacerbation. First-line therapy for an exacerbation during pregnancy is corticosteroids.

ANSWERS TO CASE 12:

What is the most likely diagnosis?

Suspect scleroderma in this patient with sclerotic skin lesions (sclero = tight, derma = skin).

Systemic abnormalities such as polyarthralgia and Raynaud's phenomenon indicate systemic sclerosis (Ssc). The location of sclerotic lesions on the trunk and arms suggests diffuse Ssc (Fig. 12-1).

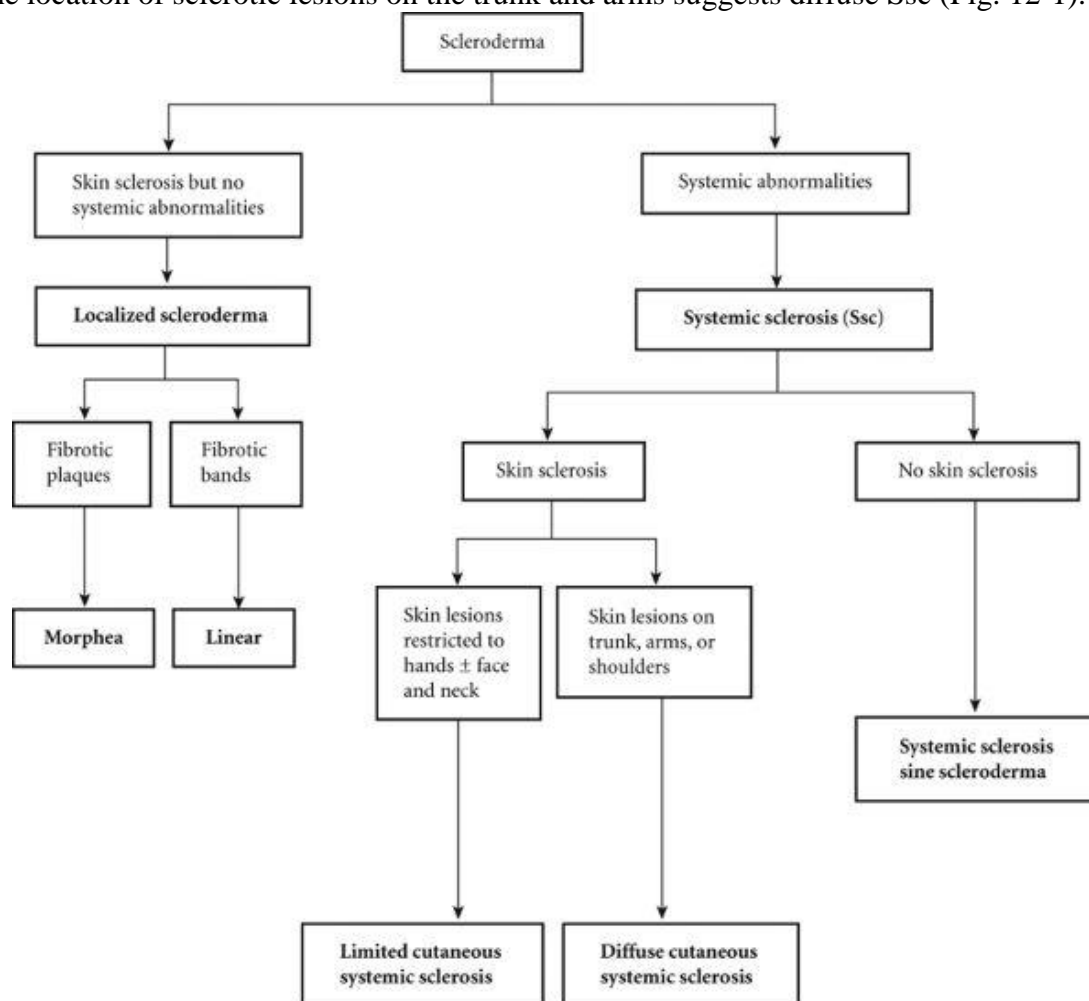


Figure 12–1. Classification of scleroderma.

Although both localized and systemic forms of scleroderma exist, the term “scleroderma” is typically used interchangeably with Ssc.

What causes scleroderma?

In scleroderma, an autoimmune insult stimulates excessive collagen deposition in the skin and other organs. The exact cause of this autoimmune insult is unknown.

What systemic manifestations commonly occur in systemic scleroderma?

Raynaud's phenomenon is the most common initial manifestation in both limited and diffuse systemic scleroderma. Other systemic manifestations occur years later in patients with limited scleroderma but only months later in patients with diffuse scleroderma.

- Limited cutaneous Ssc: Systemic manifestations are usually limited to the CREST syndrome (other abnormalities do occur but less frequently):

- Calcinosis: small, hard Ca²⁺-containing masses on fingers and pressure points
- Raynaud's phenomenon: often the earliest clinical manifestation
- Esophageal dysmotility: leads to dysphagia and heartburn
- Sclerodactyly: thickening of hand and foot digits
- Telangiectasias: can occur on face, trunk, hands, gastrointestinal (GI) tract and oral mucosa

- Diffuse scleroderma: Systemic findings include CREST syndrome as well as:

- Constitutional: fatigue
- Heart: myocardial fibrosis, pericarditis, and arrhythmias
- Lungs: interstitial lung disease and pulmonary hypertension are the leading causes of death.
- GI: peri-oral fibrosis (leads to pursed-lips), constipation, and diarrhea.
- Kidneys: scleroderma renal crisis (acute onset of hypertension and ARF)
- Genitourinary: erectile dysfunction, decreased vaginal lubrication, increased miscarriages
- Musculoskeletal: arthralgias (often out of proportion to inflammation)

- Cancer: increased risk of lung (most significant), skin and blood cancers
- Raynaud's disease: Idiopathic hand and/or foot pain, numbness, and discoloration in response to stress or cold.

• Raynaud's phenomenon: Symptoms are due to secondary causes. Mnemonic is “CCold IS BAD”: Carpal tunnel syndrome, Chemical exposure to vinyl chloride, Injury to hands or feet, Smoking, Blood vessel occlusion due to vasculitides such as Buerger's disease, Autoimmune arthritides, and Drugs (Bleomycin, controversial association with β -blockers and oral contraceptive pills).

Buerger's disease (thromboangiitis obliterans): Suspect this small- to medium-vessel vasculitis if the patient is a 20- to 40-year-old male cigarette smoker with severe Raynaud's and no other underlying cause. Confirm the diagnosis with angiography. Treatment is to stop smoking.

What antibodies are often positive in patients with systemic scleroderma?

- ANA: often positive in both limited and diffuse forms of Ssc.
- Anti-centromere Ab: specific but not sensitive for limited Ssc.
- Anti-scleroderma-70 Ab: specific but not sensitive for diffuse Ssc.

Scleroderma is a clinical diagnosis. Negative antibody tests do not rule out the diagnosis.

Antiscleroderma-70 is positive.

How is scleroderma (Ssc) treated?

There is no effective therapy for scleroderma. Treatment targets correction or minimization of specific abnormalities. For example, treat arthralgias with NSAIDs and heartburn with PPIs or H2-blockers. Although not very effective, corticosteroids \pm cyclophosphamide is sometimes considered for skin sclerosis.

The patient is particularly distressed with the Raynaud's symptoms.

How is this condition managed?

First-line treatment is lifestyle measures (often sufficient for primary Raynaud's). If lifestyle measures fail (most cases of secondary Raynaud's), treat with a long-acting calcium-channel blocker such as amlodipine or nifedipine. If a maximal dose of one calcium-channel blocker is ineffective, switch to another calcium-channel blocker. If symptoms persist, add topical nitroglycerin to the regimen (vasodilator). Surgery (sympathectomy) is a last resort for severe refractory symptoms.

Lifestyle measures: Remind the patient to avoid cold temperatures, smoking, caffeine, stress, and sympathomimetic drugs, and to wear warm clothes (thermals, mittens, etc.).

The major complications of secondary Raynaud's syndrome are digital ulcers and gangrene.

Mixed connective tissue disease: Autoimmune polyarthritis that combines features of RA, SLE, scleroderma, and polymyositis. Key laboratory feature is (+)-anti-U1-RNP antibody. ANA is often positive (Table 12-1).

Table 12–1. Summary of immunological tests in autoimmune arthritides

Autoantibody	Main Indication	Comments
RF	RA	Neither sensitive nor specific
Anti-CCP	RA	Specific but not sensitive
ANA	SLE	97% sensitive for SLE but not specific
Anti-dsDNA	SLE	Specific for SLE but not sensitive
Anti-Smith	SLE	Specific for SLE but not sensitive
Anti-histone	DILE	Approximately 100% sensitive and specific for DLE
Anti-SSA (anti-Ro)	Sjogren's	Neither sensitive nor specific; often positive in ANA-negative SLE
Anti-SSB (anti-La)	Sjogren's	Neither sensitive nor specific; often positive in ANA-negative SLE
Anti-centromere	Limited Ssc	Specific for limited Ssc but not sensitive
Anti-Scl 70	Diffuse Ssc	Specific for diffuse Ssc but not sensitive
Anti-U1 RNP	MCTD	Fairly sensitive and specific for MCTD

Abbreviation: ANA, antineutrophilic antibody; MCTD, mixed connective tissue disease; SLE, systemic lupus erythematosus; Ssc, systemic sclerosis

ANSWERS TO CASE 13:

What diagnosis should you suspect?

Suspect Behçet's disease in this young woman with polyarthralgia, painful genital ulcers, and painful aphthous ulcers. This vasculitis is most common in persons of Turkish or Iranian descent. HLA-B51 is a risk factor, although most people with this gene do not develop Behçet's.

Oral and genital ulcers are painless in reactive arthritis but painful in Behçet's disease.

What other organs does Behçet's commonly affect?

Although Behçet's disease can affect virtually any organ system, frequently affected sites besides the ones mentioned earlier are:

- Central nervous system: aseptic meningitis due to white matter demyelination
- Eyes: uveitis
- Lungs: hemoptysis due to ruptured pulmonary aneurysm
- GI: symptoms and biopsy findings similar to IBD
- Skin: folliculitis and erythema nodosum

What tests can aid in the diagnosis of Behçet's disease?

Although Behçet's disease is largely a clinical diagnosis, the following tests can aid in the diagnosis if positive:

- Biopsy: Consider biopsy of genital or oral ulcer to confirm vasculitis.
- Pathergy test: Prick forearm with a small needle. The test is positive if pustule formation occurs 1 to 2 days after the prick. The test is not sensitive, but it is relatively specific.

Biopsy of an aphthous ulcer demonstrates vasculitis. Pathergy test is positive.

How is Behçet's disease treated?

Topical steroids are sufficient for symptoms limited to the mouth or genitals. This patient with polyarthritis should receive systemic corticosteroids. Consider systemic corticosteroids plus immunosuppressive medications like cyclophosphamide for patients with eye or central nervous system involvement.

ANSWERS TO CASE 14:

What is the most likely diagnosis?

This young, sexually active patient presents with the classic triad of disseminated gonococcal infection (DGI): tenosynovitis (typically the earliest symptom), dermatitis (most common lesion is painless pustules), and polyarthralgias (often migratory). Symptoms often begin at the start of menses. Interestingly, only a few patients with DGI actually have urethral symptoms of gonorrhea infection.

The other common presentation of DGI is joint swelling, warmth, and tenderness with positive synovial fluid findings.

Tenosynovitis: tenderness, swelling, and pain with movement of affected tendon sheath.

What laboratory testing is indicated in patients with known or suspected DGI?

• Blood cultures: All patients should have at least two sets of blood cultures. Positive blood culture is diagnostic, but negative culture does not rule out DGI. Blood culture can also distinguish DGI from other infectious causes of arthritis such as *S. aureus* and *Neisseria meningitidis*.

• Urethral, rectal, skin, and synovial culture (grow on Thayer-Martin media).

• Serology for syphilis (RPR/VDRL) and HIV antibodies.

Synovial fluid analysis is usually negative in patients with tenosynovitis, dermatitis, and polyarthritis. However, blood culture is more likely to be positive than in patients with purulent arthritis.

The first set of blood cultures show Gram-negative diplococci. Remaining laboratory studies are pending.

What is the next step in management?

Gram-negative diplococci on blood culture are diagnostic of DGI. First-line therapy is a 7-day course of IV ceftriaxone or another third-generation cephalosporin PLUS oral doxycycline to cover possible concurrent Chlamydia infection. Also, treat sexual partners with a third-generation cephalosporin + doxycycline

Treatment for patients with purulent arthritis should also include daily joint drainage.

The patient's symptoms resolve after 2 days of IV ceftriaxone.

What is the next step in management?

Consider switching to oral antibiotics if the patient's symptoms resolve within 1 to 2 days of IV therapy. First-line oral antibiotic is cefixime. Continue doxycycline.

ANSWERS TO CASE 15:

What diagnosis should you suspect?

The clinical picture should raise suspicion for Lyme disease, caused by transmission of *Borrelia burgdorferi* spirochetes by the deer tick (Table 15-1). Lyme disease is most prevalent in northeastern United States. Symptoms occur in three stages:

- Stage 1 (early localized disease): Nonspecific flu-like symptoms (fatigue, myalgia, and lymphadenopathy) typically occur 7 to 10 days after the tick bite. Approximately 90% of patients also report an erythematous rash (erythema migrans) at the site of the bite. The rash forms a central clearing (“bull's eye” appearance) in approximately 10% of patients.

- Stage 2 (early disseminated disease): Weeks to months after EM onset, patients develop one or more signs of disseminated disease:

- Migratory mono-, oligo-, or polyarthritis occurs in approximately 60% of patients.
- Neurological: Aseptic meningitis or cranial nerve palsy occurs in 10% of patients.
- Cardiac: Arteriovenous block occurs in 5% of patients.

- Stage 3 (late chronic disease): Occurring months to years after the tick bite in untreated patients, clinical manifestations include chronic arthritis, neurological symptoms (neuro-borreliosis), or dermatological features (rare).

Table 15–1. Important tick-borne illnesses in the united states

Illness	Bacteria	Tick	First-line Therapy
Lyme disease	<i>Borrelia burgdorferi</i>	Ixodes (deer tick)	Doxycycline
Rocky Mountain spotted fever	<i>Rickettsia rickettsii</i>	<i>Dermacentor variabilis</i> (American dog tick)	Doxycycline
Babesiosis	<i>Babesia microti</i>	Ixodes	Atovaquone + azithromycin
Human granulocytic anaplasmosis	<i>Anaplasma phagocytophila</i>	Ixodes	Doxycycline
Human monocytic ehrlichiosis	<i>Ehrlichia chafeensis</i>	Lone star tick	Doxycycline

Patients can present with stage 2 or stage 3 disease with no signs of earlier stages.

What is the next step in management?

This patient from northeastern United States with erythema multiforme, objective signs, and constitutional symptoms has a high pretest probability for Lyme disease. The next step is to initiate antibiotics without further laboratory testing (Fig. 15-1). The choice of antibiotics is as follows:

- Stage 1 disease: Treat with a 10- to 14-day course of oral doxycycline, amoxicillin, or cefuroxime.
- Stage 2 disease: Treat with a 14- to 28-day course of IV ceftriaxone or cefotaxime if patient has third-degree heart block or meningitis. Otherwise treat with a 10- to 14-day course of oral antibiotics similar to stage 1 disease (this patient).

- Stage 3 disease: Treat with a 28-day course of IV ceftriaxone if the patient has encephalopathy (neuroborreliosis). Otherwise, treat with a 28-day course of oral doxycycline or amoxicillin.

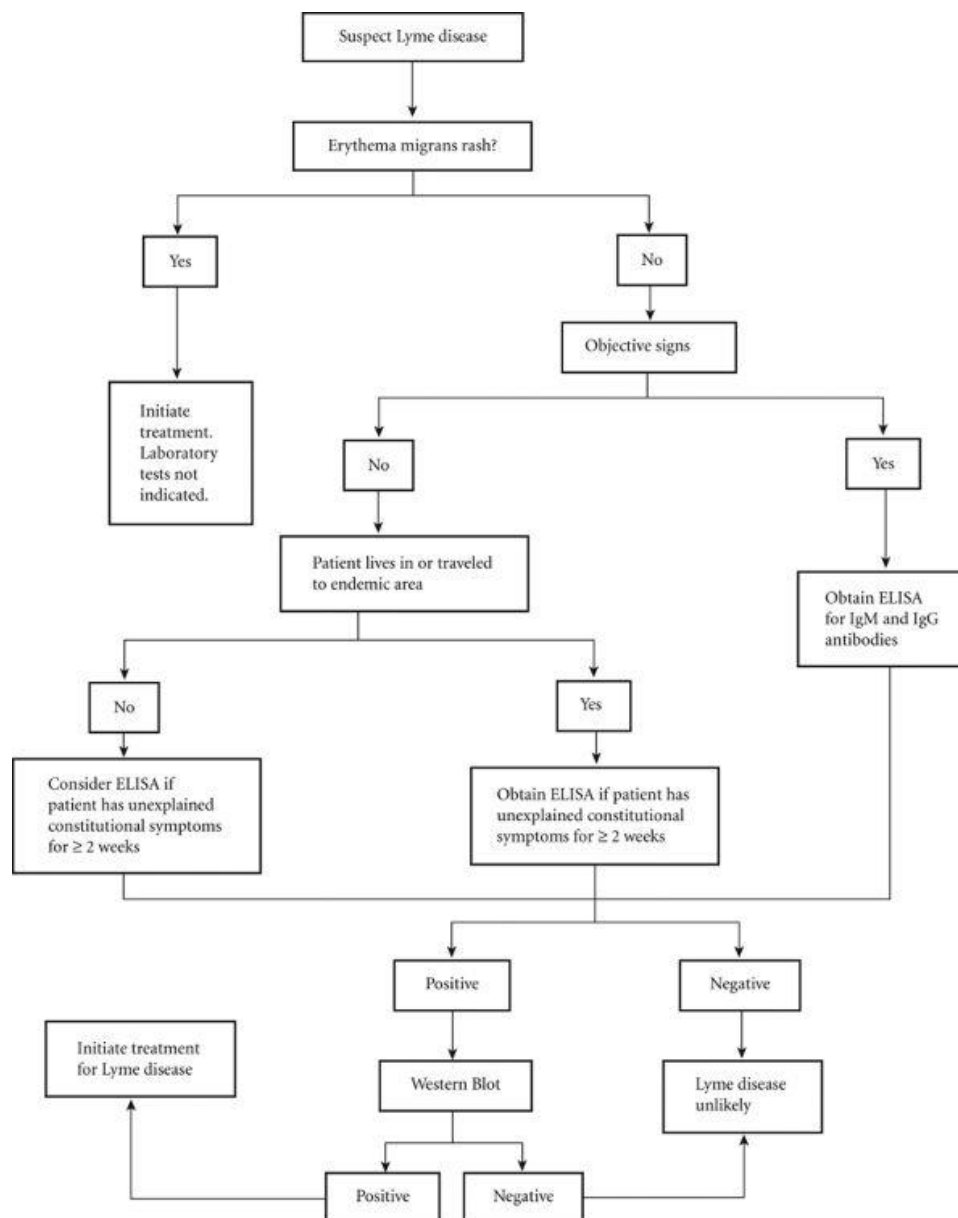


Figure 15–1. Approach to Lyme disease.

- Objective signs: arthralgia, heart block, aseptic meningitis, cranial nerve palsy
 - Constitutional symptoms: fever, fatigue, headache, myalgia, lymphadenopathy, etc.
- Avoid doxycycline in pregnant patients (risk of fetal bone and teeth malformations).

How would management differ if the patient did not have erythema multiforme?

The next step would have been serology for IgM and IgG antibodies using ELISA. Positive ELISA requires confirmation with Western blot (“two-step approach”).

- False-positive ELISA: causes include syphilis, RA, infectious mononucleosis, and Lyme disease vaccine (withdrawn from market).

- False-negative ELISA: usually occurs if patient is tested in the first 1 to 2 weeks of infection.

How would management differ if the patient presented after a tick bite while hiking in the Adirondacks (in New York) but was completely asymptomatic and had no signs of Lyme disease?

Do not test or treat asymptomatic individuals even if they have a history of recent tick bite. Advise the patient to return if she develops erythema multiforme, objective signs, or constitutional symptoms for ≥ 2 weeks.

What other illnesses are associated with Ixodes tick bites?

- Babesiosis: Babesia infection can be asymptomatic, mild, or cause malaria-like symptoms. Diagnose with blood smear (“Maltese cross” inclusions in RBCs), serology, or polymerase chain reaction. Treat malaria-like symptoms with atovaquone plus azithromycin.

- Human granulocytic anaplasmosis (HGA): Anaplasma phagocytophila infection causes nonspecific constitutional symptoms. Preferred diagnostic test is immunofluorescence antibodies (IFA). Treat with doxycycline.

ANSWERS TO CASE 16:

What is the most likely diagnosis?

Constitutional symptoms followed by arthralgias and a maculopapular rash during the spring or summer season in southern United States is the classic presentation of Rocky Mountain Spotted Fever (RMSF). Symptoms result from transmission of the Gram-negative bacterium *Rickettsia rickettsii* by *Dermacentor variabilis* (American dog tick). The tick is endemic throughout the United States, but most infections occur in the South. Patients with advanced disease may have hyponatremia, thrombocytopenia, and abnormal serum creatinine, or LFTs.

Classic triad of RMSF: Fever, rash, and history of tick bite. The characteristic petechial rash is usually not visible for approximately 1 week after symptom onset; 10% to 15% of patients do not have the characteristic rash. Many patients do not report any tick bite.

What is the next step in management?

Obtain IFA and then initiate empiric doxycycline immediately, before laboratory results return.

Give doxycycline to any patient in an endemic area who presents with fever and other constitutional symptoms for >3 days in the spring or summer months.

- IFA IgM: Usually elevated after 5 to 7 days of symptom onset.
- IFA IgG: Usually elevated after 7 to 10 days of symptom onset.

How would the choice of antibiotics differ if the patient were pregnant?

Avoid tetracyclines such as doxycycline during pregnancy; use chloramphenicol instead.

What other validated laboratory tests are available to aid in the diagnosis besides IFA?

- Polymerase chain reaction: most rapid and specific test; not widely available.
- Skin biopsy immunostaining: approximately 70% sensitive; often used in autopsies.

Human monocytic Ehrlichiosis (HME): Caused by *Ehrlichia chafeensis* infection transmitted by the lone star tick. Also known as “spotless” RMSF. The term “spotless” is misleading because 30% of HME presents with a rash. Preferred diagnostic test is IFA. Treat with doxycycline.

ANSWERS TO CASE 17:

What is the next step in management?

Groin pain suggests that the pain originates in the hip joint. Important causes of acute anterior hip pain are hip osteonecrosis (avascular necrosis), hip osteomyelitis, and hip fracture. The initial diagnostic study in any patient with acute onset of groin pain is AP (antero-posterior) and lateral (frog-leg) x-rays. If plain films are nondiagnostic, obtain MRI.

Plain films demonstrate sclerosis, cysts, and subchondral radiolucency (“crescent sign”).

What is the diagnosis?

The findings are pathognomonic for osteonecrosis. In this condition, bone marrow vasculature is compromised, which leads to bone marrow infarction. This patient has the two most common risk factors for osteonecrosis: chronic steroid and alcohol use. Other important risk factors include:

- Inherited and acquired thrombophilias
- Sickle cell disease
- HIV and transplantation
- Bisphosphonate or radiation therapies in patients with cancer

How is symptomatic osteonecrosis managed?

Refer any patient with symptomatic osteonecrosis for surgical management. Surgical options include decompression, osteotomy, or total hip replacement.

Asymptomatic osteonecrosis: Management is controversial (conservative therapy with bed rest and partial weight bearing versus surgery).

ANSWERS TO CASE 18:

What tests are indicated in the initial evaluation of patients who present with chronic polymyalgia and multiple tender areas on physical exam?

Initial laboratory testing in patients with polymyalgia are CBC, serum chemistries, ESR, thyroid function tests, and muscle enzymes (creatinine kinase and lactate dehydrogenase).

Laboratory tests are all negative.

What is the most likely diagnosis?

The most likely diagnosis is fibromyalgia. This idiopathic condition is much more common women. Patients present with fatigue and polymyalgia. Physical exam should demonstrate tenderness to palpation in at least 11 of 18 specified symmetric areas. All laboratory evaluations are negative in these patients. Most fibromyalgia patients also meet criteria for chronic fatigue syndrome.

What is the next step in management?

Explain the chronic nature of her symptoms and reassure her that she does not have an underlying life-threatening disorder. Treatment of fibromyalgia is challenging. Some treatment options of questionable efficacy include low-dose antidepressants, acupuncture, psychotherapy, chiropractic care, massage and physical therapy.

Myofascial pain disorder: a fibromyalgia variant (pain localized to one soft tissue area).

ANSWERS TO CASE 19:**What are two characteristics of the sleep disorder that commonly accompanies FMS?**

The sleep disorder seen in the context of FMS is characterized by early morning awakening and unrefreshing or nonrestorative sleep. Disruption of delta-wave sleep (non-REM stage IV sleep) occurs due to alpha-wave intrusion, and is termed the alpha-delta sleep pattern of FMS. Obstructive sleep apnea and restless leg syndrome should also be considered in patients presenting with FMS.

What are the characteristic physical findings in fibromyalgia?

Patients with FMS have a normal physical examination except for tender points in precise locations. These tender points are typically located at the occiput, at the midportion of the trapezius, the origin of the supraspinatus, low anterior cervical region, second costochondral junction, lateral epicondyle, outer upper quadrant of the buttocks, greater trochanter region, and medial knee area. These areas are usually tender bilaterally in patients with FMS. Control points such as the midforearm and anterior mid thigh are not normally painful in patients with FMS.

Are there any laboratory test abnormalities characteristic of FMS?

All laboratory test results in the setting of FMS are usually completely normal. To initially exclude disorders that may mimic FMS, a complete blood count, ESR, creatinine, liver function tests, thyroid-stimulating hormone, creatine phosphokinase (CPK), calcium, phosphorus, and urinalysis should be performed. Antinuclear antibody (ANA) testing should not be performed unless there is pretest probability of a connective tissue disease (CTD) since a substantial number of individuals with FMS (12% to 30%) can have a low titer, nonspecific positive ANA.

What is the therapy for FMS?

The appropriate therapy for FMS includes patient education, analgesics such as acetaminophen or tramadol, low-dose tricyclic antidepressants or cyclobenzaprine at bedtime to improve the sleep cycle, and low-impact aerobic exercises. Antiinflammatory medications are not generally helpful. Selective serotonin reuptake inhibitors (SSRIs) and pregabalin may have some efficacy in FMS. This is a very frustrating disorder for both the patient and physician. Many patients may be helped by this approach to therapy, the most important element of which is an exercise program.

Which psychological disorders are often associated with FMS?

Functional psychiatric disorders, such as the somatoform disorders, and organic psychiatric disorders, such as major depression and anxiety disorders, have been associated with FMS in approximately 30% of patients. The anxiety and mild depression that often present in FMS may be secondary to chronic pain and concerns regarding personal independence and debility.

CASE DISCUSSION**What is the definition of nonarticular rheumatism, and what are the four forms of the disorder?**

Nonarticular rheumatism refers to aches and pains that arise from structures outside of joints, so it is not actually a true form of arthritis. Four forms of nonarticular rheumatism are tendinitis, bursitis, FMS, and the myofascial pain syndrome. Tendinitis involves inflammation and pain in specific tendons and is usually due to stress or overuse. Bursae are synovium-lined sacs that either overlie or are adjacent to joints and may also become inflamed secondary to overuse. FMS is a diffuse chronic pain disorder that is discussed in later questions. The myofascial pain syndrome, sometimes termed repetitive strain syndrome,

consists of localized (one anatomic region) tender and painful muscles in the absence of any evidence of an inflammatory muscle disease or FMS.

Name four common types of tendinitis and bursitis, and the major structure involved in each type?

Tennis elbow is pain over the lateral epicondyle of the elbow due to inflammation of the tendons of the wrist extensor muscles that insert at this location. Golfer's elbow is pain over the medial epicondyle due to inflammation of the wrist flexor tendons that insert at this location. The shoulder impingement syndrome results from impingement of the tendons of the rotator cuff with shoulder abduction or flexion and can be associated with supraspinatus tendinitis, subacromial bursitis, or rotator cuff tears. Housemaid's knee is prepatellar bursitis brought about by repetitive trauma or overuse such as kneeling. Another common area for bursitis is over the greater trochanter of the lateral hip.

What are the criteria for diagnosis of FMS?

The diagnostic criteria for FMS include at least 3 months of widespread pain that is bilateral, above and below the waist, and includes axial skeletal pain, and pain to palpation at a minimum of 11 of 18 predefined tender points (discussed in subsequent text). The diagnosis of other diseases does not exclude the diagnosis of FMS.

What are five medical illnesses that may exhibit symptoms similar to those of FMS?

Illnesses that may exhibit symptoms similar to those of FMS include celiac sprue, hepatitis C, hyperparathyroidism, hypothyroidism, and polymyalgia rheumatica (PMR). However, each of these illnesses is associated with characteristic historical, clinical, and laboratory abnormalities that distinguish it from FMS. In addition, it is often difficult to differentiate the symptoms of FMS from those of chronic fatigue syndrome. The differential diagnosis for FMS also includes RA, SLE, inflammatory myopathies, obstructive sleep apnea, paraneoplastic disorders, and seronegative spondyloarthropathies.

ANSWERS TO CASE 20:

What are some of the characteristic changes that affect the articular cartilage in patients with OA?

Abnormal joint mechanical factors result in pits, clefts, and ulcerations in the gross articular cartilage surface in OA. Microscopically, osteoarthritic cartilage reveals initial chondrocyte proliferation followed by eventual chondrocyte death; decreased proteoglycan and collagen concentrations with resultant increased water content of the cartilage; increased amounts of matrix metalloproteinases (MMPs) and inflammatory mediators; and decreased amounts of tissue inhibitors of metalloproteinases (TIMPs). This results in cartilage loss with secondary thickening of the subchondral bone and formation of osteophytes.

What are four characteristic radiographic findings encountered in patients with OA?

Radiographic findings typically encountered in patients with OA include loss of joint space, cysts in subchondral bone, subchondral sclerosis or eburnation, and osteophytes (bony spurs) at the joint margins.

Discuss the nonpharmacologic management of OA?

Nonpharmacologic modalities helpful in the management of OA consist of patient education, heat or cold application, weight reduction, physical therapy that focuses on muscle-strengthening exercises, orthotics and bracing, and orthopaedic surgical options in select patients.

Discuss the pharmacologic options for the treatment of OA?

Acetaminophen, an analgesic, should be the first-line therapy for OA. If this is unsuccessful, NSAIDs can be used. Narcotic analgesics should be considered in patients with refractory pain. Topical application of capsaicin cream or intraarticular injection of hyaluronate or corticosteroids may be beneficial in some patients. The nutraceuticals, glucosamine and chondroitin sulfate, may have some benefit in treating OA symptoms. Long-term chondroprotective effects of these agents have not been established.

CASE DISCUSSION

What is the joint structure that is primarily involved in OA?

OA is the most common joint disorder in the world. It is a disorder of articular cartilage with secondary changes in the adjacent bone.

Why is pain at the base of the thumb and the gradual onset of pain in a knee with minimal swelling more characteristic of OA than of RA?

Pain at the base of the thumb represents arthritis of the first carpometacarpal (CMC) joint. This joint is commonly involved in the setting of OA because of frequent mechanical damage incurred during normal

use of the hand. Early OA may be characterized by joint pain with use, without signs of inflammation; morning stiffness is typically for less than 30 minutes. OA is noninflammatory and can involve the distal interphalangeals (DIPs) with associated Heberden's nodes; proximal interphalangeals (PIPs) with associated Bouchard's nodes; the first CMC of the hand; the first MTP joints; the spine; hips; and knees. RA is an inflammatory arthritis and involves bilateral metacarpophalangeals (MCPs) and PIPs in a symmetric manner and can also involve the MTPs and other synovium-lined joints; morning stiffness is typically for more than 60 minutes.

What are the risk factors for developing OA?

The risk factors for developing OA are age, obesity, abnormal joint mechanics, previous joint trauma or inflammatory joint disease, heredity (especially OA of the DIP joints), and certain occupations that require repetitive use of joint groups, bending, or carrying heavy loads. Metabolic disorders associated with OA include crystal deposition diseases, Paget's disease, ochronosis, acromegaly, hemochromatosis, and Wilson's disease.

What are some of the characteristic findings encountered during physical examination in patients with OA?

Typical findings encountered during physical examination in patients with OA include bony overgrowth (osteophytes), joint line tenderness, crepitus on passive motion, and limitation of motion with pain on extremes of motion. The end result may be joint deformity.

ANSWERS TO CASE 21:

What other organs beside muscle may be involved in patients with polymyositis or dermatomyositis?

The lungs, heart, and joints may also be involved in patients with polymyositis or dermatomyositis. Pulmonary involvement includes interstitial lung disease, aspiration pneumonia, respiratory muscle weakness, and pulmonary hypertension. Cardiac manifestations are dysrhythmias, conduction blocks, and myocarditis. Patients may experience polyarthralgia or an inflammatory arthritis. Characteristic skin findings (discussed in subsequent text) are required for a diagnosis of dermatomyositis.

What four different skin lesions are seen in patients with dermatomyositis?

The skin lesions seen in patients with dermatomyositis include an erythematous rash over the anterior chest and neck (V-sign rash), an erythematous rash over the shoulders and proximal arms (shawl-sign rash), erythematous raised lesions over the knuckles (Gottron's papules), and a periorbital lilac colored rash (heliotrope rash). Gottron's papules and the heliotrope rash are considered pathognomonic cutaneous features of dermatomyositis. Mechanic's hands (cracking and/or fissuring of the skin of the finger pads) can be seen in the antisynthetase syndrome often associated with anti Jo-1 antibodies.

What diagnostic evaluation is indicated to search for a possible malignancy in patients with polymyositis or dermatomyositis, and what may happen to the muscle disease when the malignancy is treated?

Malignancies may develop in patients with polymyositis or dermatomyositis, either before or after (3 to 5 years) the onset of inflammatory muscle disease. The diagnostic evaluation for a possible malignancy in this setting should be age appropriate and usually includes a good history and physical examination (including breast, pelvis, and prostate), a chest radiographic study, mammography, stool guaiac testing, and routine laboratory tests. The malignancies found in these patients include among others carcinomas of the lung, gastrointestinal tract, breast, ovaries, and pancreas, and Hodgkin's lymphoma. If the malignancy is treated, the muscle disease may improve.

What is the approach to treatment of polymyositis/dermatomyositis?

The treatment of polymyositis and dermatomyositis should first consist of systemic corticosteroids given in high doses. If patients show a poor response to steroids or if the dosage cannot be decreased, immunosuppressive drug treatment with such agents as azathioprine or MTX may be instituted. Hydroxychloroquine can be used to treat the cutaneous manifestations of dermatomyositis. Refractory cases of inflammatory myopathies may respond to intravenous immune globulin. Progressive physical therapy is recommended to maintain range of motion, prevent contractures, and, as muscle inflammation subsides, to regain muscle strength.

CASE DISCUSSION

What three general categories of joint or muscle disease need to be considered in a patient presenting with diffuse aches and muscle weakness?

A patient with diffuse aches and muscle weakness may have a form of inflammatory arthritis, particularly RA; an endocrinopathy, particularly thyroid or parathyroid disease; or a form of inflammatory muscle disease. The differential diagnosis also includes neuropathic diseases, medications, infections, metabolic myopathies, and neoplasia.

What are the five subgroups of inflammatory muscle disease?

Inflammatory muscle disease can be divided into the following disorders: primary idiopathic polymyositis, primary idiopathic dermatomyositis, childhood dermatomyositis associated with vasculitis, polymyositis and dermatomyositis associated with collagen vascular disease such as SLE or scleroderma, and polymyositis and dermatomyositis associated with malignancy.

What historical information would suggest the presence of inflammatory muscle disease?

Inflammatory muscle disease has an insidious onset over 3 to 6 months usually with no identifiable precipitating event. The weakness initially affects the muscles of the shoulder and pelvic girdle. The patients may experience difficulty in climbing stairs, getting out of chairs, or combing their hair. Weakness of neck flexors occurs in approximately 50% of patients. Pharyngeal muscle involvement may cause dysphonia, dysphagia, or aspiration. Ocular, facial, and bulbar muscle weakness is extremely rare.

What two laboratory test results might be abnormal in patients with inflammatory muscle disease?

Two abnormal laboratory test findings in patients with polymyositis or dermatomyositis are elevations in the ESR and the serum CPK level. Approximately 50% of patients have a positive ANA. Myositis-specific antibodies, such as anti Jo-1, can occur in a subset of patients and can predict clinical manifestations (myositis, interstitial lung disease, nonerosive arthritis, Raynaud's phenomenon, and mechanic's hands) and prognosis.

• What four diagnostic tests or procedures should be performed in any patient with suspected inflammatory muscle disease?

The diagnostic evaluation of patients with suspected inflammatory muscle disease should include serologic testing for ANA subtypes to rule out a myositis overlap syndrome, electrocardiography to screen for cardiac involvement, electromyography (EMG) to confirm a myopathic process, and muscle biopsy to confirm the suspected diagnosis.

ANSWERS TO CASE 22:

What three different rheumatic diseases are suggested by a predominance of skin findings?

A predominance of skin findings in a patient with a suspected rheumatic disease suggests a diagnosis of SLE, dermatomyositis, or scleroderma. The skin findings in each of these diseases, however, are distinct, which allows their differentiation.

Raynaud's phenomenon may occur in association with what four rheumatic diseases?

Raynaud's phenomenon (a cold-induced blanching or cyanosis of the fingers or toes) may be seen in the settings of scleroderma (90%), MCTD (70%), SLE (20%), or polymyositis/dermatomyositis (20%). When the phenomenon occurs alone, without an associated CTD, it is called Raynaud's disease.

Dysphagia or heartburn may predominate in what two rheumatic diseases?

Dysphagia (discomfort when swallowing food) and heartburn are esophageal abnormalities that may occur in the setting of either scleroderma or polymyositis and dermatomyositis. In scleroderma, the lower portion of the esophagus is involved. In dermatomyositis and polymyositis, the muscles in the pharynx and upper third of the esophagus may be involved.

What features characterize CREST syndrome?

CREST syndrome is a clinical variant of limited scleroderma that is characterized by calcinosis, Raynaud's phenomenon, esophageal dysmotility, sclerodactyly, and telangiectases. Patients with the syndrome may experience a more benign course than those with more widespread scleroderma that involves other internal organs. There is an increased risk for the development of pulmonary hypertension with limited scleroderma.

What is the difference between limited and diffuse scleroderma (systemic sclerosis)?

In limited systemic sclerosis, fibrotic skin disease is limited to the hands and forearms, feet, neck, and face. Pulmonary hypertension can occur. Patients with limited systemic sclerosis have a high incidence of anticentromere antibodies. In diffuse systemic sclerosis, fibrotic skin involves the fingers, hands, arms, legs, and typically the trunk and face. Pulmonary (interstitial lung disease), renal, gastrointestinal, and

cardiac involvement can occur. Patients with diffuse systemic sclerosis are more likely to have antibodies to topoisomerase I (anti Scl-70).

CASE DISCUSSION

What is the primary pathophysiologic process in systemic sclerosis?

Systemic sclerosis is a systemic fibrotic disorder. In the skin, there is early CD4⁺ T-cell infiltration and massive normal type I collagen deposition by dermal fibroblasts likely induced by transforming growth factor OI (TGF-OI). Arterial endothelial cell damage with myointimal cell proliferation (onion skinning) occurs, resulting in narrowing of the vascular lumen. Ischemic damage and fibrosis can occur in visceral organs as a result of this vasculopathy.

What four radiographic findings may be seen in patients with systemic sclerosis?

Radiographic abnormalities that may be found in patients with scleroderma include widemouth diverticula of the transverse and descending colon on barium enema, pulmonary interstitial fibrosis, loss of distal digital tufts, and subcutaneous calcinosis particularly in the hands.

What are some of the complications associated with esophageal and small intestinal involvement in systemic sclerosis?

The lower esophageal involvement that can occur in patients with systemic sclerosis may lead to severe esophageal reflux, dysphagia, and ultimately esophageal strictures may develop. Involvement of the small intestine may lead to loss of motility with malabsorption secondary to bacterial overgrowth. Other complications of gastrointestinal involvement with systemic sclerosis include watermelon stomach (gastric antral vascular ectasia) and pneumatosis cystoides intestinalis.

What cardiac and renal problems may arise in patients with systemic sclerosis?

The hearts of patients with systemic sclerosis may be affected by patchy fibrosis, which can cause conduction disturbances and arrhythmias. Pericarditis and congestive heart failure can also occur. In the event of renal involvement, patients can have hypertension with mild proteinuria that sometimes leads to scleroderma renal crisis (accelerated hypertension and rapid loss of kidney function progressing to renal failure). Most patients who develop scleroderma renal crisis have diffuse cutaneous involvement. Microangiopathic hemolytic anemia and thrombocytopenia can be present in the setting of renal crisis.

What is the therapy for patients with systemic sclerosis?

There are currently no known medications that can alter the natural course of scleroderma. Aggressive skin care is helpful in preventing breakdown and local infection. Raynaud's phenomenon is treated with protection from the cold and calcium channel blockers. Gastroesophageal reflux requires aggressive therapy with a proton pump inhibitor. Broad-spectrum antibiotics may be used if diarrhea arises as a result of small intestinal involvement. An angiotensin-converting enzyme inhibitor should be used in hypertensive patients with systemic sclerosis in an effort to prevent further renal damage and possible renal crisis by reversing the underlying hyperreninemia. Patients with early progressive interstitial lung disease may benefit from treatment with cyclophosphamide. Significant pulmonary arterial hypertension, the leading cause of death in patients with limited scleroderma, often requires aggressive therapy with oxygen, anticoagulation, and agents such as bosentan, sildenafil, or prostanoids.

ANSWERS TO CASE 23:

When should arthrocentesis be performed?

The most important reason to perform an arthrocentesis is to exclude a joint infection. Synovial fluid analysis is often helpful diagnostically in a patient with joint pain and swelling of unclear etiology. Synovial fluid analysis will determine if the fluid is normal, noninflammatory, inflammatory including crystal disease, or septic.

What diagnostic tests should be performed on all synovial fluid aspirates regardless of the suspected diagnosis?

Synovial fluid should be routinely sent for cell count with differential, crystal analysis, and Gram's stain and culture. Chemistry determinations are unlikely to yield additional useful information and should not be ordered routinely.

What are the characteristics of normal, noninflammatory, inflammatory, and septic synovial effusions?

Type of Fluid	Special Features	Leukocytes/B μ L
Normal	Clear, colorless, viscous	<200 (<25% PMNs)

Noninflammatory (type I fluid)	Clear, yellow, viscous	200-2,000 (<25% PMNs)
Inflammatory (type II fluid)	Cloudy, yellow, low viscosity, culture negative	>2,000 (>50% PMNs)
Septic (type III fluid)	Purulent, culture positive	>50,000 (>95% PMNs) but not all fluids >50,000 are septic, they may be inflammatory

PMNs, polymorphonuclear leukocytes.

What are the causes of bloody or hemorrhagic synovial fluid?

The causes of hemorrhagic synovial fluid are trauma with or without fracture; bleeding disorders including anticoagulation, hemophilia, von Willebrand's disease, scurvy, and thrombocytopenia; crystalline arthropathy, particularly acute pseudogout and hydroxyapatite deposition disease; Charcot's arthropathy; tumors including pigmented villonodular synovitis; hemangioma; and sickle cell arthropathy.

CASE DISCUSSION

How do bacteria reach the synovium to cause a septic arthritis?

Infectious organisms reach the synovial membrane through hematogenous spread due to a remote infection (most common), dissemination from an adjacent soft tissue infection or osteomyelitis, diagnostic or therapeutic measures, or penetrating puncture from trauma. The most common organism causing septic arthritis in young sexually active adults is *N. gonorrhoeae* and in patients older than 50 years is *Staphylococcus aureus* followed by gram-negative organisms.

What are the risk factors for developing a septic arthritis?

The risk factors for developing a septic arthritis include abnormal joints due to arthritis; prosthetic joints; impaired host defense mechanisms including extremes of age, immunosuppressive drugs, alcoholism, neoplastic diseases, and chronic diseases such as diabetes, chronic kidney disease, cirrhosis, hemoglobinopathies, and HIV; and host phagocytic defects such as impaired chemotaxis and complement deficiencies. Intravenous drug abuse is also a predisposing risk for developing a septic arthritis often with atypical joint involvement. In addition to joints of the lower extremities, intravenous drug abusers can develop septic arthritis of the axial skeleton, vertebral disc spaces, sacroiliac joints, acromioclavicular joints, and sternoclavicular joints.

How do nongonococcal bacterial septic arthritis and disseminated gonococcal arthritis differ?

	Nongonococcal bacterial arthritis	Gonococcal arthritis
Host	Extremes of age, immunosuppressed	Young, healthy adults
Joint pattern	Monoarticular	Migratory polyarthralgias, arthritis
Dermatitis	Rare	Common
Tenosynovitis	Rare	Common
Positive joint cultures	>95%	<25%
Positive blood cultures	50%	<10%
Treatment	Arthroscopic or open joint lavage and prolonged intravenous antibiotics	Ceftriaxone daily until clinical improvement followed by 7-d treatment with oral cefixime or a fluoroquinolone
Mechanism	Bacteremic seeding of the joint	Immune complex or hypersensitivity reaction

What is pseudoseptic arthritis?

Pseudoseptic arthritis typically occurs in the setting of poorly controlled RA. The patient presents with acute onset of one or more swollen joints with synovial fluid WBC count greater than 100,000 cells/BµL and a negative Gram's stain and culture of the fluid. After joint infection has been excluded, the patient responds to increased doses of corticosteroids rather than antibiotics. Pseudoseptic arthritis can also occur in acute crystal-induced arthritis, particularly acute pseudogout, and in seronegative spondyloarthropathies, especially reactive arthritis.

ANSWERS TO CASE 24:

What clinical features suggest a diagnosis of SLE?

For the purposes of clinical studies, any person having 4 or more of the following 11 criteria is considered to have SLE: malar rash, discoid rash, photosensitivity, oral ulcers, arthritis, serositis (pleuritis or pericarditis), renal disorder (persistent proteinuria >0.5 g per day or cellular casts), neurologic disorder (seizures or psychosis), hematologic disorder (hemolytic anemia, leukopenia, lymphopenia, or thrombocytopenia), immunologic disorder (anti-DNA antibodies, anti-Smith [Sm] antibodies, or positive findings of antiphospholipid antibodies), and ANA.

What abnormal laboratory results suggest a diagnosis of SLE?

Almost all patients with SLE demonstrate elevated serum levels of ANA. However, this test is not specific for SLE. Other laboratory abnormalities in SLE can include anti double-stranded DNA antibodies, anti-Sm antibodies, false-positive test for syphilis, low serum complement levels, prolonged partial thromboplastin time, antiphospholipid antibodies, cytopenias, and active urine sediment.

Besides SLE, ANAs are commonly found in what other diseases?

In SLE, ANAs have a sensitivity of 93% to 100% but a lower specificity of approximately 50% since ANAs can occur in many other diseases. Conditions associated with a positive ANA include other autoimmune diseases (scleroderma: 60% to 85%, MCTD: 90% to 100%, inflammatory myopathies: 50%, RA: 30% to 50%, Sjogren's syndrome: 40% to 70%, and drug-induced lupus: 100%), organ-specific autoimmune diseases (such as Hashimoto's thyroiditis: 46%, Graves' disease: 50%, autoimmune hepatitis: 63% to 91%, primary biliary cirrhosis: 10% to 40%, idiopathic thrombocytopenic purpura: 10% to 40%, and multiple sclerosis: 25%), chronic infections (such as mononucleosis, hepatitis C, HIV infection, parvovirus B19 infection, bacterial endocarditis, and tuberculosis), lymphoproliferative diseases, FMS: 12% to 30%, and healthy women and elderly patients: 5% to 30%. In SLE, the positive and negative predictive values of an ANA are 11% to 30%, and 95%, respectively. Therefore, an ANA should be tested only when the patient has a high clinical pretest probability of having a CTD.

Case Discussion

What are the two most common mechanisms of tissue damage in patients with SLE?

Tissue damage in patients with SLE may be caused by antibodies to cell surface components or by the presence of soluble immune complexes in the circulation. Antibodies to platelets, WBCs, or red blood cells may induce thrombocytopenia, leukopenia, or anemia, respectively. Antiphospholipid antibodies may induce venous or arterial thromboses, recurrent fetal loss, or thrombocytopenia. Soluble immune complexes in the circulation may deposit in blood vessels or along basement membranes in the skin or kidneys, resulting in vasculitis, dermatitis, or glomerulonephritis.

Besides the skin and joints, what other organs are commonly affected in patients with SLE?

Other organs that may be affected in the setting of SLE include the central and peripheral nervous systems, lungs (pleuritis, capillaritis, pneumonitis, pulmonary hypertension, and shrinking lung syndrome), heart (pericarditis, myocarditis, and valvular disease), kidneys (mesangial nephritis, diffuse proliferative glomerulonephritis, and membranous nephropathy), and gastrointestinal system (pancreatitis and mesenteric vasculitis), as well as the formed elements of the blood and serous membranes.

What serologic tests and diagnostic procedures may be helpful in the management of lupus nephritis?

Low serum complement levels and/or high titers of antibodies to double-stranded DNA may precede flares of renal disease. A kidney biopsy may aid in the management of patients with lupus nephritis particularly when the severity of the disease appears to be changing, the disease is refractory to high-dose prednisone therapy, and cytotoxic therapy with intravenous bolus cyclophosphamide therapy is being considered.

What are the four possible causes of peripheral edema in patients with SLE?

Peripheral edema in a patient with SLE may be due to renal disease with significant proteinuria, congestive heart failure secondary to cardiac involvement, protein-losing enteropathy due to mesenteric vasculitis, or peripheral venous thrombosis stemming from the formation of anticardiolipin antibodies.

What is the therapy for SLE?

Patients with SLE are managed according to the extent and severity of their organ involvement. Patients with mild disease consisting of arthritis, skin, and non-life-threatening blood or other organ involvement may be treated with NSAIDs, antimalarials such as hydroxychloroquine, and low-dose corticosteroids if necessary. Patients with more severe organ involvement, particularly of the central

nervous system and kidneys, may be treated with high doses of corticosteroids and oral azathioprine or intravenous cyclophosphamide. Recent evidence suggests that mycophenolate mofetil may be useful in some patients with lupus nephritis. Other therapies may be used for the amelioration of specific organ involvement.

ANSWERS TO CASE 25:

What is the likely diagnosis?

This patient has a number of important symptoms, particularly the generalized seizures, auditory hallucinations, fever, arthralgia and alopecia. Investigations show low haemoglobin, white cells and platelets with impaired renal function and blood, protein and cells in the urine. The CSF contains white cells and a high protein content but no organisms. This is a multisystem disease and the symptoms and investigations are explained best by a diagnosis of systemic lupus erythematosus (SLE). SLE is an autoimmune condition which is about nine times more common in women than men, and is especially common in African-Caribbean and Asian individuals. It varies in severity from a mild illness causing a rash or joint pains, to a life-threatening multisystem illness. In the brain, SLE causes a small-vessel vasculitis and can present with depression, a schizophrenia-like psychosis, fits, chorea and focal cerebral/spinal cord infarction. Lumbar puncture usually shows a raised leucocyte count and protein level. A Coombs'-positive haemolytic anaemia may occur. Leucopenia and thrombocytopenia are common. Glomerulonephritis is another common manifestation of lupus and may present with microscopic haematuria/proteinuria, nephrotic syndrome or renal failure. Arthritis commonly affects the proximal interphalangeal and metacarpophalangeal joints and wrists, usually as arthralgia without any deformity.

Differential diagnosis of the combination of headaches/psychiatric features/fits

- Meningitis/encephalitis
- Recreational' drug abuse, e.g. cocaine
- Cerebral tumor
- Acute alcohol withdrawal: delirium tremens
- Hypertensive encephalopathy

How would you investigate and manage this patient?

This patient needs urgent antihypertensive treatment to lower her blood pressure, and anticonvulsant treatment. Blood should be sent for anti-DNA antibodies (present in SLE) and complement C3 and C4 levels (depressed in SLE). A renal biopsy will provide histological evidence of the severity of the lupus nephritis. As soon as active infection has been excluded, treatment should be started with intravenous steroids and cytotoxic agents such as cyclophosphamide. Plasma exchange may be added in severe or resistant cases.

Clinical pearls

- > SLE is particularly common in young African-Caribbean women.
- > SLE may present with predominantly neurological or psychiatric features.
- > A low white cell count or low platelet numbers are often a suggestive feature of SLE.

ANSWERS TO CASE 26:

A 48-year-old hypertensive man complains of acute onset of severe right knee pain of 8-hour duration. He denies previous pain, surgery, or injury to his knees. One year ago, he had great toe pain and swelling for several days that resolved with ibuprofen. He takes hydrochlorothiazide and occasionally drinks alcohol. On examination, his temperature is 100.6°F, heart rate 104 bpm, and blood pressure 136/78 mm Hg. His right knee is swollen, with a moderate effusion, and appears erythematous, warm, and very tender to palpation. He is unable to fully extend the knee because of pain. He has no other joint swelling, pain, or deformity, and no skin rashes.

- > Most likely diagnosis: Acute monoarticular arthritis, likely crystalline or infectious, most likely gout because of history.
- > Next step: Aspiration of the knee joint to send fluid for cell count, culture, and crystal analysis.
- > Best initial treatment: If the joint fluid analysis is consistent with infection, he needs drainage of the infected fluid by aspiration and administration of antibiotics. If analysis is suggestive of crystal-induced

arthritis, he can be treated with colchicine, nonsteroidal anti-inflammatory drugs (NSAIDs), or corticosteroids.

ANALYSIS

Considerations

A middle-aged man presents with an acute attack of monoarticular arthritis, as evidenced by knee effusion, limited range of motion, and signs of inflammation (low-grade fever, erythema, warmth, tenderness). The two most likely causes are infection (eg, *Staphylococcus aureus*) and crystalline arthritis (eg, gout or pseudogout). If the patient is at risk, gonococcal arthritis is also a possibility. The previous less severe episode involving his first metatarsophalangeal (MTP) joint sounds like podagra, the most common presentation of gout.

The previous attack of arthritis in the first MTP joint and the very rapid onset of severe symptoms during the current attack are consistent with acute gouty arthritis. In this patient, the attack could have been precipitated by the use of alcohol, which increases uric acid production, and his use of thiazide diuretics, which decrease renal excretion of uric acid.

Although the first attack was typical of gout, which makes this episode very likely to also be acute gouty arthritis, the current presentation is also entirely consistent with bacterial infection. Untreated septic arthritis could lead to rapid destruction of the joint, so joint aspiration and empiric antibiotic therapy are appropriate until his cultures and crystal analysis are available.

Approach to monoarticular arthritis

Definitions

MONOARTHRITIS: Inflammation of a single joint.

GOUT: A disturbance of uric-acid metabolism occurring mainly in men, characterized by painful inflammation of the joints, especially of the feet and hands, and arthritic attacks resulting from elevated levels of uric acid in the blood and the deposition of urate crystals around the joints.

Clinical approach

Almost any joint disorder may begin as monoarthritis, or inflammation of a single joint; however, the primary concern is always infectious arthritis, because it may lead to joint destruction and resultant severe morbidity. For that reason, acute monoarthritis should be considered a medical emergency and investigated and treated aggressively.

Monoarthritis may be a result of infection (eg, bacterial, fungal, Lyme disease, tuberculosis) or crystal-induced arthritis (eg, pseudogout and gout); less often, it may be the presentation of a systemic disease typically associated with polyarticular disease, such as rheumatoid arthritis or systemic lupus erythematosus. It may also be a result of noninflammatory causes such as trauma or osteoarthritis.

Accurate diagnosis starts with a good history and physical examination supplemented by additional diagnostic testing, such as synovial fluid analysis, radiography, and occasionally synovial biopsy. A history of episodes of arthritis suggests crystalline disease or other noninfectious arthropathies. Patients with crystal-induced arthritis may give a history of recurrent, self-limited episodes. Precipitation of an attack by surgery or some other stress can occur with both crystalline disorders, but gout is far more common than is pseudogout. The clinical course can provide some clues to the etiology: septic arthritis usually worsens unless treated; osteoarthritis worsens with physical activity.

The location of joint involvement may be helpful. Gout most commonly involves the first MTP joint (podagra), ankle, mid-foot, or knee. Pseudogout most commonly affects the large joints, such as the knee; it may also affect the wrist or the first MTP joint (hence, the name pseudogout). In gonococcal arthritis, there are often migratory arthralgias and tenosynovitis, often involving the wrist and hands, associated with pustular skin lesions, before progressing to a purulent monoarthritis or oligoarthritis. Nongonococcal causes of septic arthritis often involve large weight-bearing joints, such as the knee and hip.

The basic approach in physical examination is to differentiate arthritis from inflammatory conditions adjacent to the joint, such as cellulitis or bursitis. True arthritis is characterized by swelling and redness around the joint, and painful limitation of motion in all planes, during active and passive motion. Joint movement that is not limited by passive motion suggests a soft tissue disorder such as bursitis rather than arthritis.

Diagnostic arthrocentesis usually is necessary when evaluating an acute monoarthritis and is always essential when infection is suspected. Synovial fluid analysis helps to differentiate between inflammatory and noninflammatory causes of arthritis. Fluid analysis typically includes gross examination, cell count and differential, Gram stain and culture, and crystal analysis. Table 26-1 gives the typical results that can

help one distinguish between noninflammatory conditions such as osteoarthritis, inflammatory arthritis such as crystalline disease, and septic arthritis, which most often is a bacterial infection.

Normal joints contain a small amount of fluid that is essentially acellular. Noninflammatory effusions should have a white blood cell count less than 1000 to 2000/mm³ with less than 25% to 50% polymorphonuclear (PMN) cells. If the fluid is inflammatory, the joint should be considered infected until proven otherwise, especially if the patient is febrile.

Crystal analysis requires the use of a polarizing light microscope. Monosodium urate crystals, the cause of gout, are needle-shaped, typically intracellular within a PMN cell, and are negatively birefringent, appearing yellow under the polarizing microscope. Calcium pyrophosphate dehydrate (CPPD) crystals, the cause of pseudogout, are short and rhomboid, and are weakly positively birefringent, appearing blue under polarized light. Even if crystals are seen, infection must be excluded when the synovial fluid is inflammatory! Crystals and infection may coexist in the same joint, and chronic arthritis or previous joint damage, such as occurs in gout, may predispose that joint to hematogenous infection.

In septic arthritis, Gram stain and culture of the synovial fluid is positive in 60% to 80% of cases. False-negative results may be related to prior antibiotic use or fastidious microorganisms. For example, in gonococcal arthritis, joint fluid cultures typically are negative, whereas cultures of blood or the pustular skin lesions may be positive. Sometimes, the diagnosis rests upon demonstration of gonococcal infection in another site, such as urethritis, with the typical arthritis-dermatitis syndrome. Synovial biopsy may be required when the cause of monoarthritis remains unclear, and is usually necessary to diagnose arthritis caused by tuberculosis or hemochromatosis.

Table 26-1. Distinguish between noninflammatory conditions such as osteoarthritis

Gross examination	Normal	Noninflammatory	Inflammatory	Septic
Volume (knee)	<1 mL	Often >1 mL	Often >1 mL	Often >1 mL
Viscosity	High	High	Low	Variable
Color	Colorless to straw	Straw to yellow	Yellow	Variable
Clarity	Transparent	Transparent	Translucent	Opaque
Leukocytes/mm³	<200	50-1000	2000-75,000	Often >100,000
Polymorphonuclear cells	<25%	<25%	Often >50%	>85%
Culture results	Negative	Negative	Negative	Often positive
Glucose	Nearly equal to blood	Nearly equal to blood	<50 mg/dL lower than blood	<50 mg/dL lower than blood

Plain radiographs usually are unremarkable in cases of inflammatory arthritis; the typical finding is soft tissue swelling. Chondrocalcinosis or linear calcium deposition in joint cartilage suggests pseudogout. They are often found when evaluating for fracture in patients with a history of trauma.

Generally, patients require initiation of treatment before all test results are available. When septic arthritis is suspected, the clinician should culture the joint fluid and start antibiotic therapy; the antibiotic choice should be initially based on the Gram stain and, when available, the culture results. If the Gram stain is negative, the clinical picture should dictate antimicrobial selection. For example, if the patient has the typical presentation of gonococcal arthritis, intravenous ceftriaxone is the usual initial therapy, usually with rapid improvement in symptoms. Nongonococcal septic arthritis usually is caused by gram-positive organisms, most often *S aureus*, so treatment would involve an antistaphylococcal penicillin such as nafcillin, or vancomycin when methicillin resistance is suspected. It is essential to drain the purulent joint fluid, usually by repeated percutaneous aspiration. Open surgical drainage or arthroscopy is required when joint fluid is loculated, or when shoulders, hips, or sacroiliac joints are involved.

Gout classically progresses through four stages.

Stage 1 is asymptomatic hyperuricemia. Patients have elevated uric acid levels without arthritis or kidney stones. The majority of patients with hyperuricemia never develop any symptoms, but higher the uric acid level and the longer the duration of hyperuricemia, the greater the likelihood of the patient developing gouty arthritis.

Stage 2 is acute gouty arthritis, which most often involves the acute onset of severe monoarticular pain, often occurring at night, in the first MTP joint, ankle, or knee, with rapid development of joint swelling and erythema and sometimes associated with systemic symptoms such as fever and chills. This

usually follows decades of asymptomatic hyperuricemia. Attacks may last hours or up to 2 weeks.

Stage 3 is intercritical gout, or the period between acute attacks. Patients are generally completely asymptomatic. The vast majority of patients will have another acute attack within 1 to 2 years. The presence of these completely asymptomatic periods between monoarthritic attacks is so uncommon, except in crystalline arthritis, that it is often used as a diagnostic criterion for gout.

Stage 4 is chronic tophaceous gout, which usually occurs after 10 or more years of acute intermittent gout. In this stage, the intercritical periods are no longer asymptomatic; the involved joints now have chronic swelling and discomfort, which worsens over time. Patients also develop subcutaneous tophaceous deposits of monosodium urate.

In general, asymptomatic hyperuricemia requires no specific treatment. Lowering the urate level does not necessarily prevent the development of gout, and most of these patients will never develop any symptoms. Acute gouty arthritis is treated with therapies to reduce the inflammatory reaction to the presence of the crystals, all of which are most effective if started early in the attack. Potent NSAIDs, such as indomethacin, are the mainstay of therapy. Alternatively, oral colchicine can be taken every hour until the joint symptoms abate, but dosing is limited by gastrointestinal side effects such as nausea and diarrhea. Individuals affected by acute joint pain with renal insufficiency, for which NSAIDs or colchicine is relatively contraindicated, usually benefit from intraarticular glucocorticoid injection or oral steroid therapy. Steroids should be used only if infection has been excluded. Treatment to lower uric acid levels is inappropriate during an acute episode because any sudden increase or decrease in urate levels may precipitate further attacks.

During intercritical gout, the focus shifts to preventing further attacks by lowering uric acid levels. Dietary restriction is mainly aimed at avoiding organ-rich foods, such as liver, and avoiding alcohol. Patients taking thiazide diuretics should be switched to another antihypertensive if possible. Urate lowering can be accomplished by therapy to increase uric acid excretion by the kidney, such as with probenecid. Uricosuric agents such as this are ineffective in patients with renal failure, however, and are contraindicated in patients with a history of uric acid kidney stones. In these patients, allopurinol can be used to diminish uric acid production. In either case, urate lowering can precipitate acute attacks, so initial prophylaxis with daily low-dose colchicine usually is necessary.

Patients with tophaceous gout are managed as previously described during acute attacks and treated with allopurinol to help tophaceous deposits resolve. Surgery may be indicated if the mass effect of tophi causes nerve compression, joint deformity, or chronic skin ulceration with resultant infection.

Patients with pseudogout are treated similarly for acute attacks (NSAIDs, colchicine, systemic or intraarticular steroids). Prophylaxis with colchicine may be helpful in patients with chronic recurrent attacks, but there is no effective therapy for preventing CPPD crystal formation or deposition.

Comprehension questions

1. A previously healthy 18-year-old college freshman presents to the student health clinic complaining of pain on the dorsum of her left wrist and in her right ankle, fever, and a pustular rash on the extensor surfaces of both her forearms. She has mild swelling and erythema of her ankle, and pain on passive flexion of her wrist. Less than 1 mL of joint fluid is aspirated from her ankle, which shows 8000 polymorphonuclear (PMN) cells per high-power field (hpf) but no organisms on Gram stain. Which of the following is the best initial treatment?

- A. Indomethacin orally
- B. Intravenous ampicillin
- C. Colchicine orally
- D. Intraarticular prednisone
- E. Intravenous ceftriaxone

2. Which of the following diagnostic tests is most likely to give the diagnosis for the case in Question 21.1?

- A. Crystal analysis of the joint fluid
- B. Culture of joint fluid
- C. Blood culture
- D. Cervical culture

3. A 30-year-old man is noted to have an acutely swollen and red knee. Joint aspirate reveals numerous leukocytes and polymorphonuclear leukocytes, but no organisms on Gram stain. Analysis shows few negatively birefringent crystals. Which of the following is the best initial treatment?

- A. Oral corticosteroids
- B. Intraarticular corticosteroids
- C. Intravenous antibiotic therapy
- D. Oral colchicine

Answers

1.E. The patient described best fits the picture of disseminated gonococcal infection. She has the rash, which typically is located on extensor surfaces of distal extremities. Pain on passive flexion of her wrist indicates likely tenosynovitis of that area. The fluid is inflammatory, but gonococci are typically not seen on Gram stain. Ceftriaxone is the usual treatment of choice for gonococcal infection. Nafcillin would be useful for staphylococcal arthritis and would be the more likely choice if she were older, had some chronic joint disease such as rheumatoid arthritis, or were immunocompromised. Gonococcal arthritis is the most common cause of infectious arthritis in patients younger than 40 years. Indomethacin or colchicine would be useful if she had a crystalline arthritis, but that is unlikely in this clinical picture. Intraarticular prednisone is contraindicated while infectious arthritis is a possibility.

2.D. Synovial fluid cultures usually are sterile in gonococcal arthritis (in fact, the arthritis is more likely caused by immune complex deposition than by actual joint infection), and blood cultures are positive less than 50% of the time. Diagnosis is more often made by finding gonococcal infection in a more typical site, such as urethra, cervix, or pharynx.

3.C. Corticosteroids should not be used until infection is ruled out. The inflammatory arthritis as shown by Gram stain of the joint aspirate is suspicious for infection, even with no organisms seen on Gram stain. Also, the presence of a few crystals does not eliminate an infection.

Clinical pearls

1. In the absence of trauma, acute monoarthritis is most likely to be caused by septic or crystalline arthritis.

2. In a febrile patient with a joint effusion, diagnostic arthrocentesis is mandatory. Inflammatory fluid, that is, a white blood cell count more than 2000/mm³, should be considered infected until proven otherwise.

3. Gonococcal arthritis usually presents as a migratory tenosynovitis, often involving the wrists and hands, with few vesiculopustular skin lesions. Nongonococcal septic arthritis is most often caused by *Staphylococcus aureus* and most often affects large weight-bearing joints.

4. Monosodium urate crystals in gout are needle-shaped and negatively birefringent (yellow) under the polarizing microscope. Calcium pyrophosphate dihydrate crystals in pseudogout are rhomboid and positively birefringent (blue).

5. Treatment of gout depends on the stage: nonsteroidal anti-inflammatory drugs, colchicine, or steroids for an acute gouty arthritis, and urate lowering with probenecid or allopurinol during the intercritical period.

ANSWERS TO CASE 27:

This is a 32-year-old woman with a 1-year history of symmetric polyarticular arthritis and morning stiffness. Joint examination reveals the presence of bilateral swelling, redness and tenderness of her PIP joints, MCP joints, wrists, and knees. She has a mild normocytic anemia with an otherwise normal complete blood count (CBC). Urinalysis, renal, and liver function tests are normal. The ESR is elevated, suggesting an inflammatory cause of her arthritis.

- > Most likely diagnosis: Rheumatoid arthritis (RA).
- > Next diagnostic step: Rheumatoid factor and antinuclear antibody titer.

ANALYSIS

Considerations

This patient's history, including the symmetric peripheral polyarthritis and duration of symptoms, is suggestive of RA. Rheumatoid arthritis is a systemic autoimmune disorder of unknown etiology. Its major distinctive feature is a chronic symmetric and erosive synovitis of peripheral joints, which, if untreated, leads to deformity and destruction of joints due to erosion of cartilage and bone. The diagnosis of RA is a clinical one, based on the presence of a combination of clinical findings, laboratory abnormalities, and radiographic erosions.

Approach to polyarticular arthritis

Clinical approach

The first and most important step in evaluating a patient with polyarticular joint pain is determining

whether or not synovitis/arthritis is present, producing soft tissue swelling, joint effusion, tenderness, warmth of the joint, and limitation of both active and passive range of motion. If the only finding is pain without inflammatory changes, then the diagnostic considerations include noninflammatory diseases such as osteoarthritis (OA), fibromyalgia, hypothyroidism, neuropathic pain, and depression. The presence of soft tissue swelling and tenderness with limited active range of motion but normal passive range of motion suggests the problem is extraarticular soft tissue inflammation, such as bursitis or tendonitis.

If there is active synovitis/arthritis, it is clinically useful to distinguish between monoarticular/oligoarticular arthritis and polyarticular arthritis. In polyarticular disease, the next diagnostic clue is the duration of symptoms. If symptoms are relatively acute (<6 weeks), the major considerations are arthritis due to viral infection (such as hepatitis B or C, rubella, or parvovirus B19) or the earliest manifestation of a true rheumatic disease. Viral serologies and compatible clinical history of exposure often can make the diagnosis at this point and obviate need for further rheumatologic evaluation. Treatment of a viral arthritis usually is limited to symptom relief with nonsteroidal antiinflammatory drugs (NSAIDs) because the conditions are generally self-limited.

Symmetric peripheral polyarthritis is the most characteristic feature of RA. Other autoimmune rheumatic diseases, such as systemic lupus erythematosus (SLE) and psoriatic arthritis are often asymmetric. Lupus, which may present with a symmetric polyarthritis, usually is characterized by the presence of other symptoms, such as malar rash, serositis (pleuritis and pericarditis), renal disease with proteinuria or hematuria, central nervous system (CNS) manifestations, as well as hematologic disorders, such as hemolytic anemia, leucopenia, lymphopenia, or thrombocytopenia. Rheumatic fever, which can cause symmetric polyarthritis, is an acute febrile illness lasting only 6 to 8 weeks. In psoriatic arthritis the pattern of joint involvement varies widely. The vast majority of patients have peripheral joint involvement of more than five joints. Others have a pauciarticular asymmetric arthritis or exclusive distal interphalangeal (DIP) involvement. Inflammation is not limited to the joints but also occurs at the periosteum, along tendons, and at the insertion points into the bone, resulting in the development of "sausage digits," which are typical of psoriatic arthritis (and Reiter syndrome). Although the arthritis can precede the development of a skin rash, the definite diagnosis of psoriatic arthritis cannot be made without the evidence of skin or nail changes typical of psoriasis. Reactive arthritis as an asymmetric inflammatory arthritis which follows infection of the gastrointestinal (GI) or genitourinary (GU) tract with bacteria such as *Salmonella*, *Shigella*, *Campylobacter*, *Yersinia*, or *Chlamydia*. Reiter syndrome is a form of reactive arthritis with the triad of arthritis, uveitis, and urethritis.

The peripheral polyarthritis of RA most typically involves the wrists and the MCP or PIP joints of both hands; the DIP joints usually are spared. It is useful to contrast the typical pattern of joint involvement of RA from those of degenerative OA. Degenerative joint disease may affect multiple joints, but it occurs in older age groups, usually is not associated with inflammation or constitutional symptoms, and tends not to be episodic. Also, in OA the hand joints most commonly involved are the DIP joints, where the formation of Heberden nodes can be noted (Figure 27-1). Ulnar deviation of the MCP joints is often associated with radial deviation of the wrists; swan-neck deformities can develop as well as the boutonniere deformity (Figure 27-2).

Swan-neck deformity results from contracture of the interosseous and flexor muscles and tendons, which causes a flexion contracture of the MCP joint, hypertension of the PIP joint, and flexion of the DIP joint. In the boutonniere deformity, there is a flexion of the PIP and hyperextension of the DIP joints. These findings are typical of advanced RA.

Morning stiffness or stiffness after any prolonged inactivity is a common feature of many arthritic disorders. However, stiffness that lasts more than 1 hour is seen only in inflammatory conditions such as RA and reflects the severity of joint inflammation. See Table 27-1 for diagnostic criteria.

Rheumatoid nodules are subcutaneous nodules typically found over extensor surfaces of the proximal ulna or other pressure points. They only occur in 20% to 30% of patients with RA but are believed to have a high diagnostic specificity for RA.

Rheumatoid factors (RFs) are immunoglobulins that react to the Fc portion of immunoglobulin (Ig)G molecules. The usual serologic tests used in clinical laboratories detect IgM RFs, which are found in 80% to 85% of patients with RA. Rheumatoid factor is not specific for RA, as it is found in 5% of healthy patients, but it can support the diagnosis when clinical features are suggestive. High RF titers have a prognostic utility for more severe systemic and progressive disease.

Radiologic findings in RA, such as erosion of periarticular bone and cartilage destruction with loss of

joint space, may help the diagnosis. On X-rays, the typical findings are joint space narrowing, subchondral polysclerosis, marginal osteophyte formation, and cyst formation. Usually, though, the typical X-ray findings do not develop until later in the disease process after a diagnosis has been made based on clinical findings. Joint deformities in RA occur from several different mechanisms, all related to synovitis and pannus formation with resulting cartilage destruction and erosion of periarticular bone. The structural damage to the joint is irreversible and worsens with disease progression. Multiple different joints may be affected, such as hand, foot, ankle, hip, shoulders, elbow, and cervical spine.

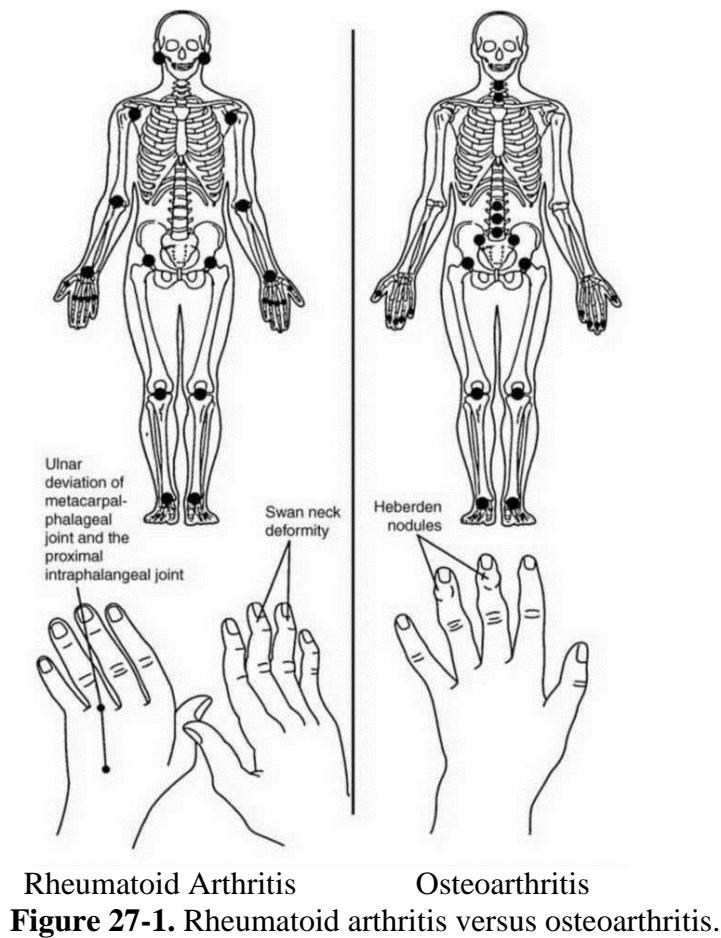


Figure 27-1. Rheumatoid arthritis versus osteoarthritis.

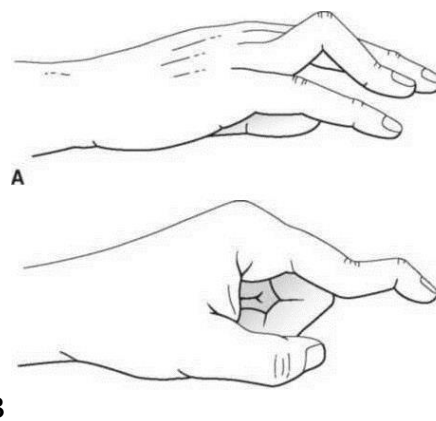


Figure 27-2. Boutonniere (A) and swan-neck (B) deformities.

There are several extraarticular manifestations in RA, including vasculitic lesions with the development of ischemic ulcers, which implies systemic involvement; ocular manifestations with symptoms of keratoconjunctivitis sicca (Sjogren syndrome); respiratory manifestations caused by interstitial lung disease; cardiac manifestations; and several neurologic manifestations, such as myelopathy, related to cervical spine instability. Although not common, the continuous bone erosion may result in an atlantoaxial subluxation with cervical dislocation and spinal cord compression. Entrapment neuropathy may develop, such as carpal tunnel syndrome. Hematologic manifestations include anemia, typically anemia of chronic disease. The combination of RA, splenomegaly, leucopenia, lymphadenopathy,

and thrombocytopenia is called Felty syndrome. Felty syndrome is most common with severe nodule-forming RA.

Table 27-1. 1987 criteria for the classification of acute rheumatoid arthritis*

Criterion	Definition
1. Morning stiffness	Morning stiffness in and around the joints, lasting at least 1 h before maximal improvement.
2. Arthritis of 3 or more joint areas	3 or more of the following joints noted to have soft tissue swelling or fluid: PIP, MCP, wrist, elbow, knee, ankle, or MTP.
3. Arthritis of hand joints	At least one wrist, MCP, or PIP joint with soft tissue swelling or fluid.
4. Symmetric arthritis	Simultaneous involvement of the same joint areas (as defined in criterion 2) on both sides of the body (bilateral involvement of PIPs, MCPs, or MTPs is acceptable without absolute symmetry).
5. Rheumatoid nodules	Subcutaneous nodules, over bony prominences, or extensor surfaces, or in juxtaarticular regions, observed by a physician.
6. Serum rheumatoid factor	Demonstration of abnormal amounts of serum rheumatoid factor by any method for which the result has been positive in <5% of normal control subjects.
7. Radiographic changes	Radiographic changes typical of rheumatoid arthritis on posteroanterior hand and wrist radiographs, which must include erosions or unequivocal bony decalcification localized in or most marked adjacent to the involved joints (osteoarthritis changes alone do not qualify).

**Rheumatoid arthritis is strongly suspected when 4 of 7 criteria are met.*

At this stage in the disease process, our patient is presenting with joint complaints, fatigue, and malaise. No other extraarticular manifestations have developed yet. At the very onset of RA, the characteristic symmetric inflammation of the joints and the typical serologic findings may not be evident. Therefore, initially distinguishing RA from other conditions, such as lupus, may be difficult. Usually, the development of extraarticular phenomenon allows the physician to make a more specific diagnosis.

Treatment

Several drugs currently are used for treatment of RA. Nonsteroidal antiinflammatory drugs (NSAIDs) or cyclooxygenase-2 (COX-2) inhibitors such as celecoxib may control local inflammatory symptoms. Corticosteroids have an immediate and dramatic effect on joint symptoms, but were historically thought not alter the natural progression of the disease. Recent evidence suggests that low-dose corticosteroids may retard the progression of bone erosions.

Disease-modifying antirheumatic drugs (DMARDs) may have a favorable impact on the natural course of the disease, reducing joint inflammation and disease activity, and improving functional status in patients with RA. The DMARDs include methotrexate, hydroxychloroquine, sulfasalazine, oral and parenteral gold, and penicillamine. There is controversy regarding which DMARD is the most effective, but methotrexate is often used as the first drug of choice because of its rapid onset of action and higher tolerability and patient compliance. Toxicity of the various DMARDs is often the most important determinant of which drug is used, and if the patient fails to respond or develops unacceptable side effects, they may be tried on a different agent.

More recently, the biologic agents tumor necrosis factor (TNF) antagonists (etanercept, infliximab, and adalimumab) have been found to reduce disease activity within weeks, unlike other DMARDs, which may take several months to act, and may also control signs and symptoms in patients who have failed DMARD therapy. Side effects of TNF blockers may include increased risk of infection, such as reactivation tuberculosis.

Immunosuppressive agents such as azathioprine, leflunomide, cyclosporine, and cyclophosphamide are as effective as DMARDs in controlling symptoms, but are considerably more toxic, so are generally reserved for patients who have failed DMARDs and biologics.

Comprehension questions

1.A 72-year-old man develops severe pain and swelling in both knees, shortly after undergoing an abdominal hernia repair surgery. Physical examination shows warmth and swelling of both knees with large effusions. Arthrocentesis of the right knee reveals the presence of intracellular and extracellular

weakly positive birefringent crystals in the synovial fluid. Gram stain is negative. Which of the following is the most likely diagnosis?

- A. Gout
- B. Septic arthritis
- C. Calcium oxalate deposition disease
- D. Reactive arthritis
- E. Pseudogout

2. A 65-year-old man with a history of chronic hypertension, diabetes mellitus, and degenerative joint disease presents with acute onset of severe pain of the metatarsophalangeal (MTP) joint and swelling of the left first toe. Physical examination shows exquisite tenderness of the joint, with swelling, warmth, and erythema. The patient has no history of trauma or other significant medical problems. Synovial fluid analysis and aspiration is most likely to show which of the following?

- A. Hemorrhagic fluid
- B. Needle-shaped, negatively birefringent crystals
- C. Gram-negative organisms
- D. Noninflammatory fluid
- E. Rhomboidal, positively birefringent crystals

3. A 17-year-old sexually active adolescent male presents with a 5-day history of fever, chills, and persistent left ankle pain and swelling. On physical examination, maculopapular and pustular skin lesions are noted on the trunk and extremities. He denies any symptoms of genitourinary tract infection. Synovial fluid analysis is most likely to show which of the following?

- A. WBCs $75,000/\text{mm}^3$ with 95% polymorphonuclear leukocytes
- B. RBCs $100,000/\text{mm}^3$, WBCs $1000/\text{mm}^3$
- C. WBCs $48,000/\text{mm}^3$ with 80% lymphocytes
- D. WBCs $500/\text{mm}^3$ with 25% polymorphonuclear leukocytes

4. A 22-year-old man presents with complaints of low back pain for 3 to 2 months and stiffness of the lumbar area, which worsen with inactivity. He reports difficulty in getting out of bed in the morning and may have to roll out sideways, trying not to flex or rotate the spine to minimize pain. A lumbosacral (LS) spine X-ray film would most likely show which of the following?

- A. Degenerative joint disease with spur formation
- B. Sacroiliitis with increased sclerosis around the sacroiliac joints
- C. Vertebral body destruction with wedge fractures
- D. Osteoporosis with compression fractures of L3-L5
- E. Diffuse osteonecrosis of the LS spine

5. A 36-year-old woman was seen by her physician due to pain in her hands, wrists, and knees. She is diagnosed with rheumatoid arthritis. Which of the following treatments will reduce joint inflammation and slow progression of the disease?

- A. NSAIDs
- B. Joint aspiration
- C. Methotrexate
- D. Systemic corticosteroids

Answers

1. E. Pseudogout is diagnosed by positive birefringent crystals.

2. B. The involvement of the great toe is most likely gout, and the synovial fluid is likely to show needle-shaped, negatively birefringent crystals.

3. A. This history is suggestive of gonococcal arthritis, and the rash is suggestive of disseminated gonococcal disease. The synovial fluid would most likely show an acute inflammatory exudate, WBCs $72,000/\text{mm}^3$ with 75% polymorphonuclear cells.

4. B. A young man is not likely to have osteoporosis, osteoarthritis, or compression fractures. His morning stiffness, which worsens with rest, suggests an inflammatory arthritis, such as ankylosing spondylitis, which would include sacroiliitis with increased sclerosis around the sacroiliac joints.

5. C. Although NSAIDs and corticosteroids may help to relieve symptoms, they typically do not alter the disease course significantly. Disease-modifying medications include methotrexate, hydroxychloroquine, sulfasalazine, oral and parenteral gold, and penicillamine. Of these agents, methotrexate is thought to be the first line.

Clinical pearls

- > Rheumatoid arthritis is a chronic systemic inflammatory disorder characterized by the insidious onset of symmetric polyarthritis and extraarticular symptoms.
- > Rheumatoid factor is found in the serum of 85% of patients with rheumatoid arthritis.
- > In nearly all patients with rheumatoid arthritis, the wrist, metacarpophalangeal joints, and proximal interphalangeal joints are affected, whereas the distal interphalangeal joints are spared.
- > Distal interphalangeal joints and large weight-bearing joints are most commonly involved in osteoarthritis.
- > The typical X-ray finding in rheumatoid arthritis—periarticular bone erosion (loss of joint space)—may not develop until later in the disease process, when the diagnosis has already been made based on clinical findings.

ANSWERS TO CASE 28:

What is the most likely cause of her symptoms?

The most likely cause of her symptoms is steroid-induced myopathy, which presents with proximal muscle weakness (symptoms like difficulty climbing stairs and combing hair) but normal ESR. Treatment is to taper down and then discontinue steroids.

What are other important causes of weakness in patients with RA?

- Disuse atrophy: Patients have signs of atrophy ± active inflammation.
- Neuropathy: Patients also have paresthesia or sensory loss.
- Polymyositis (rare): Patients exhibit proximal muscle weakness and increased ESR.

ANSWERS TO CASE 29:

What is the most likely diagnosis?

Suspect rheumatoid vasculitis in any patient with long-standing RA who has new onset of fatigue, fever, or weight loss. Other signs of this small and medium vessel vasculitis are:

- Nervous system: mononeuritis multiplex
- Skin: digital petechiae/infarcts, lower extremity ulcers, and palpable purpura
- Eyes: scleritis and keratitis

Long-standing severe RA: Physical signs of inflammation are often absent because erosive process “burns itself out.” ESR and CRP are still elevated; RF and anti-CCP are usually positive.

How can you confirm the diagnosis?

Confirm the diagnosis with biopsy at the border of the affected skin. Rheumatoid vasculitis is histologically identical to polyarteritis nodosa. The clinical setting of RA distinguishes rheumatoid vasculitis from polyarteritis nodosa.

- Scleritis or keratitis: Biopsy is not necessary.
- No skin lesions: Consider nerve and/or muscle biopsy.

Pyoderma gangrenosum: This rare complication in RA presents with fever and foot ulcer with violaceous border. Biopsy distinguishes pyoderma gangrenosum from rheumatoid vasculitis.

How is rheumatoid vasculitis treated?

No additional treatment is necessary for isolated digital petechiae. This patient with systemic signs of rheumatoid vasculitis should receive glucocorticoids and cyclophosphamide (or azothioprine).

ANSWERS TO CASE 30:

What is the most likely diagnosis?

Neutropenia and splenomegaly in a patient with long-standing RA are the characteristic manifestations of Felty's syndrome. Confirm the diagnosis with bone marrow biopsy (usually demonstrates myeloid hyperplasia).

Bone marrow biopsy confirms the diagnosis.

How is Felty's syndrome treated?

The pathogenesis of Felty's syndrome is similar to RA. First-line DMARD for Felty syndrome is MTX; second-line therapy is gold. Also, consider granulocyte colony-stimulating factor (G-CSF) to rapidly raise neutrophil count. Consider splenectomy for patients with multiple infections due to neutropenia that is unresponsive to DMARDs and G-CSF.

ANSWERS TO CASE 31:

What diagnosis should you suspect?

Dry mouth and dry eyes (“sicca syndrome”) along with salivary gland enlargement are the characteristic manifestations of Sjögren's syndrome (SS). In this disorder, lymphocytes infiltrate multiple organs, particularly the lacrimal and salivary glands. SS can be primary or secondary to autoimmune arthritides such as RA, systemic lupus erythematosus (SLE), or scleroderma.

How can you confirm the diagnosis?

To fulfill the criteria for secondary SS, the patient must have either oral or ocular symptoms plus characteristic findings on one objective test (Table 31-1).

Table 31–1. Diagnostic criteria for Sjögren's syndrome

Indications <ol style="list-style-type: none">1. Ocular symptoms2. Oral symptoms3. Ocular signs: Schirmer's or Rose Bengal test^a4. Positive salivary gland biopsy5. Salivary gland test: salivary flow or salivary scintigraphy or parotid sialography Autoantibody: positive SSA/Ro and/or SSB/La
Primary SS (no underlying cause): <ul style="list-style-type: none">• 4 of 6 criteria are positive (as long as one of them is #4 or #6) OR• 3 of the last 4 criteria are positive.
Secondary SS (secondary to underlying disorder like RA): <ul style="list-style-type: none">• #1 or #2 is positive AND• #3, 4, or 5 is positive.

Abbreviation: RA, rheumatoid arthritis; SS, Sjögren's syndrome.

a Schirmer test: Place a strip of paper under the lower eyelid for 5 minutes, then measure the length of paper that is wet with tears. In SS, decreased length is wet compared to reference. **Rose Bengal test:** Apply Rose Bengal stain to conjunctiva. If conjunctiva is stained, the test is positive for dry eye, suggesting SS.

What are other important complications of SS besides dry eyes and dry mouth?

Lymphocytes can also infiltrate the following organ systems:

- Skin: dry skin, pruritus, and nonpalpable purpura
- Bones: arthralgia (independent of underlying cause)
- Upper airway: dry cough
- Bone marrow: non-Hodgkin's lymphoma (major cause of mortality)
- Kidneys: glomerulonephritis

How is SS treated?

For most patients, treatment is symptomatic:

- Dry mouth: First try sucking on sugarless candy and drinking sips of water. If symptoms persist, try artificial saliva gels. If these are unsuccessful, treat with muscarinic agonists (pilocarpine or cevimeline). Patients should also maintain good oral hygiene because they have an increased risk of dental caries.

- Dry eyes: First-line treatment is artificial tears; second-line treatment for refractory symptoms is punctal occlusion.

Answers to CASE 32:

What is the most likely diagnosis?

Consider spondyloarthropathy in patients with asymmetric oligoarthralgia and negative autoantibodies, particularly if the pain affects vertebrae (suggests spondylitis) and heel (suggests Achilles tendon enthesitis). Patients often have “sausage-like” digits (dactylitis). The characteristic skin lesions and nail pitting indicate that the patient has psoriatic arthritis.

Remember important spondyloarthropathies with the mnemonic “Kelly RIPA”: Reactive arthritis, Inflammatory bowel disease (IBD)-associated arthritis, Psoriatic arthritis, and Ankylosing spondylitis.

What are spondyloarthropathies?

Spondyloarthropathies (seronegative arthritis) are a group of inflammatory arthritides that share the following common features (AEIOU):

- **Arthritis pattern:** Classic pattern is asymmetric oligoarthritis (although some patients have a symmetric or polyarticular pattern), which often affects vertebrae (spondylitis) and buttock joints (sacroiliitis).

- **Enthesitis:** In addition to synovial inflammation, spondyloarthropathies can cause joint inflammation at the attachment of bone to muscle or ligaments.

- **Inheritance:** This is more common in patients with HLA-B27 antigen.

- **Seronegative:** Autoantibodies are usually negative (not always the case).

- **Uveitis:** This is a common extra-articular manifestation.

What patterns of arthritis can occur in patients with psoriasis?

There are five possible patterns of joint involvement in psoriatic arthritis:

- **Asymmetric or symmetric polyarthritis:** most common pattern.

- **Oligoarthritis with spondyloarthropathy (spondylitis and sacroiliitis):** common.

- **Arthritis mutilans:** marked destruction of hand digits (uncommon pattern).

- **Isolated distal interphalangeal (DIP) involvement:** characteristic but uncommon pattern; x-ray often shows “pencil-in-cup” appearance at the DIP.

How is psoriatic arthritis treated?

First-line treatment for arthralgias is NSAIDs. If symptoms persist, consider oral corticosteroids. Immunosuppressants are sometimes used for refractory cases.

ANSWERS TO CASE 33:

What is the most likely diagnosis?

Osteoarthritis (OA) is the most likely diagnosis in this patient with chronic, noninflammatory joint pain. The disorder can be mono-, oligo-, or polyarticular (usually symmetric). OA most frequently affects fingers and weight-bearing joints (knees, hips, and spine). Characteristic symptoms are morning stiffness lasting <30 minutes and increased joint pain with activity. Early signs are joint tenderness and effusions. Patients with advanced disease may have crepitus (grating sensation in the joints), osteophytes (hard, bony swelling in the joints), and limitation of joint movement.

- **Heberden nodes:** hard, bony swelling around DIP.

- **Bouchard nodes:** hard, bony swelling around PIP.

What causes OA?

Both genetic and environmental factors are responsible for articular cartilage degeneration. Risk factors include joint injury, joint overuse, and obesity. Unlike connective tissue disorders, onset typically occurs after age 60 years.

What are the characteristic x-ray findings of OA?

The diagnosis of OA is largely based on history and physical exam. Imaging and laboratory tests are not indicated in this patient with characteristic findings. On the other hand, plain radiographs can provide objective evidence of OA in atypical cases (x-ray findings are specific but not sensitive). The four key features of OA are osteophytes, joint space narrowing, subchondral sclerosis, and subchondral cysts (Fig. 33-1).

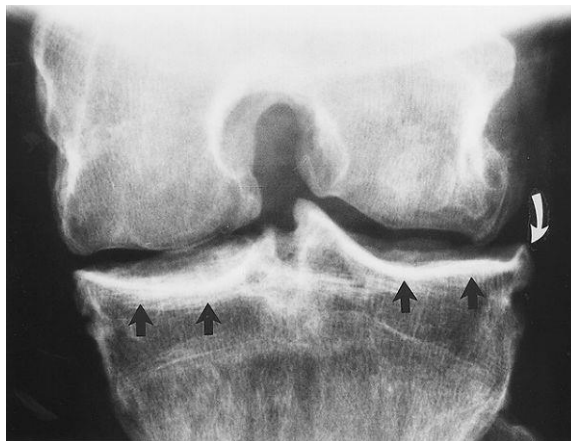

Figure 33–1. Knee x-ray showing all four features of osteoarthritis.

What initial management is recommended?

Initial therapy of OA involves lifestyle measures:

- Exercise: Exercise strengthens the muscles around joints. Recommend exercises that don't stress weight-bearing joints (e.g., aquatic aerobics).
- Cane or crutch: Use if the patient has symptoms in weight-bearing joints. Hold the cane contralateral to the most symptomatic joint. The cane should contact ground at the same time as contralateral foot.
- Weight loss.

If symptoms persist, first-line medication is acetaminophen (Fig. 33-2). NSAIDs are as effective as acetaminophen, but they are not first-line because of potential GI toxicity.

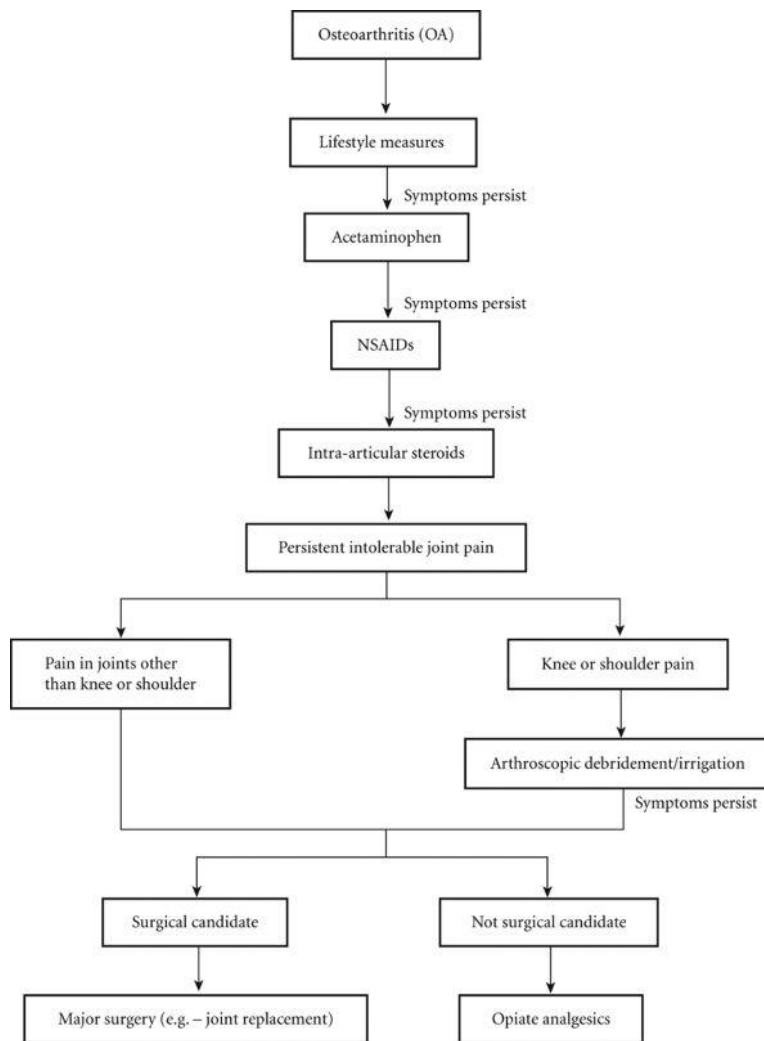


Figure 33–2. Treatment of osteoarthritis.

Glucosamine and chondroitin: Although safe and widely used to treat OA symptoms, their efficacy is actually unclear.

When should you suspect a secondary cause is responsible for OA?

Secondary causes of OA include joint instability (e.g., RA and gout), deposition disorders (e.g., hemochromatosis and calcium pyrophosphate dihydrate (CPPD)), and bleeding disorders (e.g., hemophilia). In addition to findings of the underlying disorder, suspect secondary OA if symptoms occur in atypical joints like the shoulder, elbow, or wrist.

Bleeding disorders can cause secondary OA due to intra-articular bleeding.

ANSWERS TO CASE 34:

What is the differential diagnosis of fever and joint pain?

In immunocompetent patients, joint pain with swelling, warmth, erythema, and tenderness ± fever is most commonly caused by nongonococcal bacterial infection (infectious arthritis) or crystal-induced

arthritis (gout or pseudogout). Occasionally, atypical cases of gonococcal arthritis, Lyme disease, reactive arthritis, or RA can cause these symptoms.

- Pseudogout: The knee is the most commonly affected joint.
- Gout: The great toe is the most commonly affected joint followed by the knee; 20% of cases have an oligo- or polyarticular initial presentation.
- Infectious arthritis: The knee is the most commonly affected joint; 20% of cases have an oligo- or polyarticular presentation. Staphylococcus aureus is the most common organism.

What is the next step in management?

The next step is joint aspiration (arthrocentesis) and synovial fluid analysis (Table 34-1).

Table 34–1. Synovial fluid analysis

	Normal	Noninflammatory Arthritis	Inflammatory Arthritis	Infectious Arthritis
Appearance a	Transparent	Transparent	Translucent or opaque	Opaque
WBC/mm³	<200	200–2000	2000–10,000	>10,000
PMNs	≤25%	≤25%	50–75%	≥75%
Culture	(–)	(–)	(–)	Often (+)
Glucose	Approximately = serum	Approximately = serum	Less than serum but >25 mg/dL	<25 mg/dL
Polarized light microscopy	(–)	(–)	• Gout: Needle-shaped, negatively birefringent crystals	(–)
			• Pseudogout: Rhomboid-shaped, positively birefringent crystals	

Abbreviation: PMN, polymorphonuclear leukocytes.

a Red color indicates traumatic tap or hemarthrosis.

Synovial fluid is opaque. Synovial fluid analysis shows WBC count of 15,000/mm³ with 80% neutrophils, and glucose of 20 mg/dL. There are no crystals on joint microscopy. Gram stain and culture are pending.

What is the diagnosis?

The patient has infectious arthritis. Most cases are caused by hematogenous spread. In this case, IV drug use is the likely source of bacterial entry into the bloodstream.

Gram stain shows Gram-positive cocci in clusters.

How should you treat this patient?

Treat septic arthritis with antibiotics and joint drainage:

- Antibiotics: Initial antibiotic choice in this patient with probable S. aureus infection is vancomycin to cover methicillin-resistant S. aureus (MRSA). Switch to a β-lactam if the susceptibility pattern shows that the bacteria are sensitive to methicillin.

- Joint drainage: Initial approach is daily closed-needle aspiration. If this method is unsuccessful, perform arthroscopic drainage. Analyze the synovial fluid obtained daily to monitor effectiveness of the treatment.

Treatment duration: Typical duration is 14 days of IV antibiotics followed by 14 days of oral antibiotics. Tailor treatment duration on the basis of the patient's response.

What treatment would you initiate if gram stain had showed Gram-negative bacilli?

Treat septic arthritis due to Gram-negative bacilli with joint drainage (as described earlier) and a third-generation cephalosporin. IV drug users should also receive gentamycin because infection with Pseudomonas aeruginosa is a possibility.

How would management have differed if the Gram stain were negative?

Negative Gram stain does not rule out infectious arthritis. Perform joint drainage and initiate empiric therapy. In this case, treat with vancomycin (to cover MRSA) and gentamycin (to cover P. aeruginosa). Tailor antibiotics when culture and sensitivity results return. If culture is negative, continue empiric antibiotics because negative culture does not rule out the diagnosis either.

ANSWERS TO CASE 34:

What is the most likely diagnosis?

Acute monoarticular pain in the first metatarsophalangeal joint (podagra) strongly suggests an acute attack of crystal-induced arthritis due to gout. Patients often have a low-grade fever during acute attacks. This patient also has the classic risk factors for gout: overweight, middle-aged man who frequently consumes alcohol.

What causes gout?

The underlying cause of gout is hyperuricemia, which leads to uric acid or monosodium urate crystal deposition in joints. Patients often have asymptomatic hyperuricemia for years before presenting with an acute attack. Common precipitants of an acute attack are alcohol, trauma or surgery, and drugs (e.g., thiazides, salicylates, and cyclosporine).

Asymptomatic hyperuricemia: Most patients do not develop gout. Treatment to lower uric acid is only indicated when:

- Serum uric acid >13 mg/dL in men or >10 mg/dL in women
- Uric acid excretion >1100 mg

What is the next diagnostic step?

The next step is to obtain serum uric acid. In the acute setting, increased uric acid in a patient with podagra is reasonably accurate to diagnose a patient with gout. If symptoms affect a joint other than the great toe or if serum uric acid is normal, perform joint aspiration (arthrocentesis) and synovial fluid analysis to confirm the diagnosis (Fig. 35-1). Also, obtain CBC, LFTs, and serum chemistries in all patients to establish a baseline.

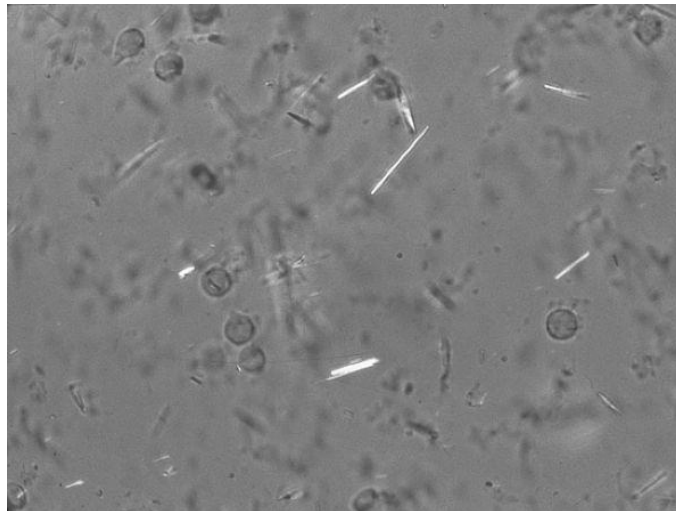


Figure 35–1. Gout: needle-shaped negatively birefringent crystals.

One third of patients have normal serum uric acid even during an acute attack, so normal uric acid does not rule out gout.

Serum uric acid is elevated. CBC and serum chemistries are normal.

How are acute attacks of gout treated?

Without treatment, acute attacks usually resolve in a few days. The goal of therapy is symptom control:

- NSAIDs: First-line treatment; indomethacin (potent NSAID) is most commonly used.
- Colchicine: Second-line treatment; use if NSAIDs are ineffective or contraindicated. Many patients find the GI side effects intolerable.
- Corticosteroids: Third-line treatment; use if NSAIDs and colchicine are contraindicated, ineffective, or not tolerated. Use intra-articular steroids if symptoms are monoarticular. Consider oral or intramuscular steroids if multiple joints are affected.

Colchicine contraindications: ↓ WBCs, ↓ platelets, severe liver or kidney failure.

The patient's symptoms resolve over the next few days.

What measures are recommended to prevent recurrent attacks?

The asymptomatic period after an acute attack has resolved is called intercritical gout. After the first attack, prevent future occurrences by controlling or eliminating risk factors (obesity, alcohol, hyperlipidemia, hypertension, and diuretics). Other important steps during the intercritical period are:

- Perform synovial fluid analysis to confirm the diagnosis.
- Obtain 24-hour urinary uric acid: Levels <800 mg/dL indicate that the defect is decreased uric acid excretion; levels >800 mg/dL indicate the main defect is uric acid overproduction.

Losartan: Increases uric acid excretion. This drug is a commonly prescribed alternative to diuretics in hypertensive patients with hyperuricemia.

Over the next 12 months, the patient has two more attacks despite controlling risk factors. 24-hour urinary uric acid is consistently <800 mg/dL.

What is the next step to prevent recurrences?

Patients with three or more attacks per year should receive uric acid–lowering therapy to prevent recurrences. First-line therapy in underexcretors like this patient is probenecid (continued indefinitely). This drug reduces uric acid reabsorption, which leads to increased uric acid excretion. Probenecid is contraindicated in patients with renal failure (consider benzbromarone in these patients).

What uric acid–lowering therapy would you have recommended if 24-hour urine uric acid was >800 mg/day?

First-line therapy to prevent recurrences in overproducers is allopurinol (continue indefinitely). This drug reduces uric acid production by inhibiting the enzyme xanthine oxidase.

Initially, allopurinol, probenecid, and benzbromarone can paradoxically increase risk of an acute attack. Therefore, continue colchicine or an NSAID after the acute attack and discontinue only after uric acid remains at target levels (5 to 6 mg/dL) for 6 months using uric acid–lowering therapy.

The patient is poorly compliant with probenecid. He resumes heavy alcohol intake. He typically presents for medical care only during acute attacks. During physical exam 15 years later, he has pain and stiffness in his knees and shoulders. There are painless, cream-colored nodules on his knees and behind his ears (Fig. 35-2).

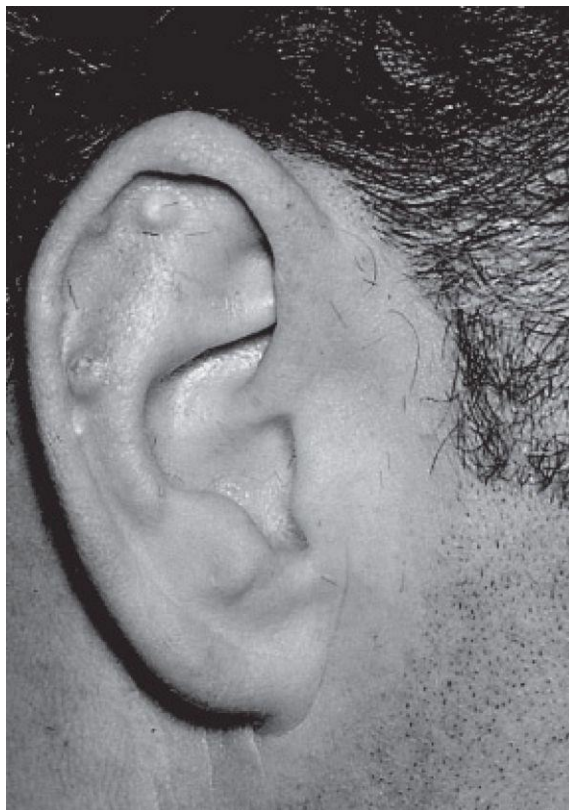

Figure 35–2. Gout: Tophi.

What is this stage of disease called?

Poorly controlled gout can progress to chronic tophaceous gout 10 to 20 years after the initial attack. The name derives from the painless, cream-colored nodules (tophi) that develop on bones and behind the ears. These nodules contain chalky-white urate deposits and may have calcifications visible on x-ray. Polyarthritides symptoms result from bone erosion by tophi (x-ray appearance is sclerotic margins and overlying edges).

ANSWERS TO CASE 36:

What is the diagnosis?

This patient with fever and monoarticular joint pain with positively birefringent rhomboid-shaped crystals on polarized microscopy has pseudogout due to CPPD crystal deposition.

Various manifestations of CPPD deposition: pseudo-OA (45%), asymptomatic (25%), pseudogout (25%), and pseudo-RA (<5%).

Polarized light microscopy: Unlike most materials, crystals are bright in one plane (“birefringent”) but dark when the plane is turned 90°. When a red compensator plate is placed parallel to the long axis of the crystals, they appear blue if they are “positively birefringent” and yellow if they are “negatively birefringent.”

What tests are routinely recommended in patients with CPPD deposition?

Obtain plain radiographs to evaluate the degree of chondrocalcinosis. Also, obtain the following labs to evaluate for predisposing factors: TSH (to detect hypothyroidism), iron studies (to detect hemochromatosis), and chemistries (to detect decreased PO₄, decreased Mg, and decreased PTH).

How is acute pseudogout due to CPPD crystal deposition treated?

- Monoarticular: joint aspiration + intra-articular steroids.
- Polyarticular: NSAIDs or colchicine.

Pseudogout prophylaxis: Consider colchicine if patient has three or more attacks per year.

Milwaukee shoulder-knee syndrome: This rare syndrome affects older women. Basic calcium phosphate crystals cause chronic shoulder and knee arthritis. Crystals are amorphous and nonbirefringent on polarized microscopy. X-rays show destructive arthritis and calcifications in knees and shoulders. Treatment is challenging.

ANSWERS TO CASE 37:

What is the diagnosis?

Suspect reactive arthritis in any patient with asymmetric inflammatory oligoarthritis that begins <6 weeks after a genitourinary or GI infection. Back and heel pain increase the likelihood that the joint pain is due to a spondyloarthropathy. Other common features of reactive arthritis are:

- Mucosal lesions: Characteristic lesions include circinate balanitis (painless, shallow genital ulcers), keratoderma blennorrhagica (palm and sole vesicles that progress to macules, papules, and nodules), and painless oral ulcers.

- Eyes: Most common disorder is transient conjunctivitis, followed by uveitis.

Reiter syndrome: This older term is used to describe a subset of patients with the classic triad of reactive arthritis: Can't see (uveitis), can't pee (urethritis), can't climb a tree (arthritis).

What causes reactive arthritis?

Reactive arthritis occurs as an immune response to bacterial infection in genetically susceptible individuals (associated with HLA-B27). *C. trachomatis* is the most common bacteria. Others include *Campylobacter*, *Salmonella*, and *Shigella*.

Not all patients with spondyloarthropathy are HLA-B27–positive. Diagnosis is based on history and clinical findings.

How is reactive arthritis treated?

Treat the infection with antibiotics and the acute arthralgias with NSAIDs. Symptoms resolve completely in about one third of patients, while others develop chronic arthritis with a waxing and waning course. First-line medications for persistent symptoms refractory to NSAIDs are SSZ and MTX.

ANSWERS TO CASE 38:

How is the diagnosis of gout established?

The diagnosis of gout requires aspiration of synovial fluid or a tophus for crystal analysis by polarized microscopy. MSU crystals are needle-shaped and negatively birefringent. In contrast, CPPD crystals (pseudogout) are rhomboid-shaped and positively birefringent. In gout, synovial fluid is inflammatory (typically 20,000 to 100,000 leukocytes/mm³). The synovial fluid should be sent for Gram's stain and culture as in rare cases, septic joint fluids can contain MSU crystals. Elevated serum uric acid levels are not diagnostic of gout as many individuals have asymptomatic hyperuricemia and never develop gout.

Why are humans predisposed to developing gout?

Uric acid is the end product of the degradation of purines. Humans lack the enzyme uricase, which oxidizes uric acid to the highly soluble compound allantoin. The lack of this enzyme subjects humans to the potential risk of developing hyperuricemia and gout. Although humans possess the uricase gene, it is inactive. Uric acid may have antioxidant and free radical scavenger properties.

What are the four reversible secondary causes of hyperuricemia?

The reversible secondary causes of hyperuricemia include alcohol consumption, diets containing purine-rich foods (meats and organ meats; seafood, particularly shellfish), medications that decrease the renal excretion of uric acid (cyclosporine, nicotinic acid, diuretics, ethambutol, low-dose aspirin, pyrazinamide), and obesity (weight loss can improve hyperuricemia). The current dietary recommendations are consumption of meat, seafood, and alcohol have to be in moderation; purine-rich vegetables are acceptable; and low-fat dairy products and wine may be protective from gout.

What are the four clinical stages of gout?

The four stages of gout are asymptomatic hyperuricemia, acute gouty arthritis, intercritical gout (the asymptomatic interval between attacks), and chronic tophaceous gout. Many patients with asymptomatic hyperuricemia do not progress to gouty arthritis. There may not be sharp demarcations between the last three stages of gout because some patients have both chronic tophaceous gout as well as intermittent acute attacks.

What are the appropriate therapies for an acute attack of gout and chronic symptomatic hyperuricemia?

The preferred treatment for an acute attack of gout is an oral NSAID, if not contraindicated. This should be given in high doses for a few days followed by a tapering, with discontinuation by 7 to 10 days. Oral colchicine can only be used in younger patients with normal renal and hepatic function. Its use is limited by the high incidence of acute gastrointestinal side effects. Intravenous colchicine should be avoided because of the potential for excess dosing in high-risk patients, likely resulting in death. Both orally and intraarticularly administered corticosteroids are effective in the management of acute attacks of gout in patients who are intolerant of or have contraindications to the aforementioned medications. Patients with chronic symptomatic hyperuricemia require lifelong therapy with a urate-lowering medication. Probenecid, a uricosuric, can be used if they are renal underexcretors of uric acid (<700 mg per 24 hours), have a creatinine clearance greater than 50 mL per minute, and are not taking more than 81 mg of aspirin per day. Allopurinol, a xanthine oxidase inhibitor, is indicated if they are overproducers (>700 mg per 24 hours), have uric acid or calcium stones, or tophaceous disease. Allopurinol is more commonly used as it works for both underexcretors and overproducers of uric acid, and is taken only once daily which increases compliance. New therapies under investigation include intravenous polyethylene glycol (PEG)-uricase and febuxostat (a nonpurine, selective inhibitor of xanthine oxidase).

CASE DISCUSSION

What are three different forms of crystal-induced arthritis, and what are the crystals involved?

Gout is a crystal-induced arthritis due to the deposition of monosodium urate (MSU) crystals. Pseudogout results from the formation and release of calcium pyrophosphate dihydrate (CPPD) crystals. The deposition of hydroxyapatite crystals can induce acute inflammatory arthritides such as calcific periarthritis/tendinitis and the Milwaukee shoulder syndrome, a destructive arthropathy of the shoulder associated with rotator cuff defects.

What are four different diseases that characteristically present with arthritis of a single joint?

Arthritis of a single joint (monoarticular arthritis) may be the initial symptom of septic arthritis, crystal deposition diseases, traumatic arthritis, and other causes such as osteoarthritis (OA), coagulopathy, avascular necrosis, and pigmented villonodular synovitis. Other historical and clinical features may be used to distinguish among these three diagnoses. A definitive diagnosis is made on the basis of the findings yielded by synovial fluid examination including cell count with differential, Gram's stain and culture, and polarized light microscopy for crystal analysis.

What three joints are most commonly involved in acute attacks of gout?

Acute gout most commonly arises in the first metatarsophalangeal (MTP) joint; this is known as podagra. The next most commonly involved sites are the instep and ankle. Knees, wrists, fingers, and elbows can also be involved. Gout has a predilection for cool, peripheral joints where the solubility of MSU crystals may be diminished as a result of the cooler temperature.

What are some historical features often found in patients with gout?

Patients with gout may have a positive family history for the disease, particularly in male members. Gout is also more common in people who have a history of obesity, metabolic syndrome, or alcoholism. Acute attacks of gout may occur during or after an episode of excessive alcohol ingestion, excess dietary purine intake, trauma, acute medical illness, or surgery. The attacks commonly begin abruptly during the night or early morning hours.

What are the three laboratory test findings that may be abnormal in the setting of gout?

Patients with acute attacks of gout often have a mild leukocytosis and an elevated erythrocyte sedimentation rate (ESR). To develop gout, these patients have to be chronically hyperuricemic, defined as a serum uric acid level greater than 7.0 mg/dL in men and 6.0 mg/dL in women. At the time of an acute attack, up to 30% of patients may have a normal serum uric acid level.

ANSWERS TO CASE 39:

What other forms of rheumatic disease need to be considered when reactive arthritis is suspected, and what diagnostic tests or procedures should be performed to exclude them?

In a patient suspected of having reactive arthritis, septic arthritis needs to be excluded. The findings yielded by joint aspiration, which includes examination of the fluid for cell count with differential, together with Gram's staining and culture, can clinch the diagnosis of a nongonococcal bacterial septic joint. Gonococcal arthritis is another possible diagnosis. Beside examination and culture of synovial fluid, the evaluation should include urethral or cervical, blood, pharyngeal, and perirectal cultures. Crystal-induced arthritis is diagnosed by the finding of crystals in the synovial fluid by polarized microscopy. Both SLE and RA need to be considered. Serologic testing for ANA, RF, and anticyclic citrullinated peptide (anti-CCP) antibodies is performed to aid in the diagnosis of these conditions. A routine complete blood count and a full chemistry profile, including liver function tests, should also be performed to search for a systemic disease that may present with joint findings similar to those seen in the setting of reactive arthritis. Reactive arthritis can be associated with human immunodeficiency virus (HIV) infection. The most useful laboratory tests in reactive arthritis are swabs or cultures that confirm the presence of arthritogenic organisms such as Chlamydia, Ureaplasma, Salmonella, Shigella, Yersinia, Campylobacter, and Clostridium difficile in the urogenital or gastrointestinal tracts.

What are some of the clinical or laboratory characteristics of reactive arthritis that help differentiate it from RA?

In contrast to RA, an asymmetric arthritis that predominates in the lower extremities is characteristic of reactive arthritis. In addition, sacroiliitis (often unilateral or asymmetric) affects 20% to 30% of patients, the syndrome is associated with HLA-B27 (80% of patients), and patients frequently have an enthesopathy. Since reactive arthritis is one of the serologically negative spondyloarthropathies, the ANA, RF, and anti-CCP antibodies are negative.

What are the three types of skin lesions seen in patients with reactive arthritis?

The skin lesions of reactive arthritis include painless mouth ulcers, keratoderma blennorrhagicum (psoriaform lesions on the soles of the feet; may also involve the scrotum, penis, palms, trunk, and scalp), and circinate balanitis (serpiginous ulceration of the glans penis). The latter two conditions are predominantly associated with urogenital reactive arthritis.

The back disease in patients with reactive arthritis is characterized by what radiographic findings?

The lumbosacral spine film of a patient with reactive arthritis may show asymmetric and bulky syndesmophytes. This is in contrast with AS, in which the syndesmophytes are usually symmetric and flowing. In reactive arthritis, sacroiliitis, if present, is often unilateral and asymmetric.

What is the therapy for reactive arthritis?

Patients with reactive arthritis are initially treated with NSAIDs (typically indomethacin) together with appropriate antibiotics during the acute phase, particularly if urethritis or cervicitis is present. If the disease progresses despite NSAID treatment, sulfasalazine or MTX may be of value for managing the inflammatory arthritis. Intraarticular corticosteroids may be helpful but systemic corticosteroids are usually ineffective. The TNF- α blocking drugs are very effective in refractory cases of reactive arthritis. Topical corticosteroids and keratolytic agents are useful for keratoderma blennorrhagicum. Physical therapy consisting of heat, ultrasound, and range-of-motion exercises may be helpful in patients with reactive arthritis.

CASE DISCUSSION

What is reactive arthritis?

Reactive arthritis is a sterile inflammatory synovitis following a distant infection by an organism that infects mucosal surfaces, particularly urogenital or enteric infections. Reactive arthritis has replaced the term Reiter's syndrome as most patients do not have the Reiter's syndrome's classic triad of arthritis, conjunctivitis, and urethritis.

In what two diseases is arthritis associated with diarrhea?

Arthritis associated with diarrhea may be seen in the setting of either reactive arthritis or inflammatory bowel disease. In reactive arthritis, the diarrhea may precede the arthritis by a few weeks. In inflammatory bowel disease, the peripheral arthritis and diarrhea often arise at the same time and the clinical activity of the arthritis may correlate with the activity of the inflammatory bowel disease.

What two possible diagnoses are suggested when acute arthritis occurs in a patient with urethral discharge?

Acute arthritis occurring in a patient with a urethral discharge suggests a diagnosis of either disseminated gonococcal infection or reactive arthritis. These diagnoses can be differentiated on the basis of characteristic clinical features as well as by a positive urethral or cervical culture for *Neisseria gonorrhoeae*. The urethritis associated with reactive arthritis can present as an aseptic pyuria or be secondary to an infection with *Chlamydia* or *Ureaplasma*.

What are the history and physical examination findings typically observed in patients with reactive arthritis?

Reactive arthritis is diagnosed on the basis of history and physical examination findings and not on the basis of any laboratory result. These clinical findings include the development of an acute arthritis in one or a few joints, often of the lower extremities, after an episode of either diarrhea, or painless urethritis or cervicitis. The diagnosis may be further strengthened by the presence of oral ulcers, conjunctivitis, or anterior uveitis, as well as characteristic skin findings of circinate balanitis or keratoderma blennorrhagicum. Enthesopathies (dactylitis, plantar fasciitis, and Achilles tendinitis) and tenosynovitis can also be common clinical features of reactive arthritis.

ANSWERS TO CASE 40:

What four characteristics of RA help distinguish it from OA?

Unlike patients with OA (noninflammatory), those with RA (inflammatory) experience morning stiffness lasting more than 30 minutes plus gel phenomenon (worse stiffness after rest); symmetric joint disease; characteristic bilateral synovitis of the hands and feet (PIPs, MCPs, and MTPs); and an intermittent or waxing and waning course.

What constitutional symptoms may be seen in RA?

Most patients experience generalized malaise or fatigue. Occasionally weight loss, low-grade fever, sleep disturbance, or mild lymphadenopathy may be present. These symptoms may be the end result of circulating inflammatory cytokines produced in the inflamed synovial tissue of the affected joints.

What are three characteristic physical findings in RA?

Physical findings encountered in the setting of RA may include swelling and warmth of one or more joints typically in a symmetric distribution, tenderness on palpation of the swollen joints, and the presence of nontender subcutaneous nodules (rheumatoid nodules) over the extensor surface of the forearm, Achilles tendon, and digits of the hands.

What five diseases may mimic RA?

RA may be mimicked by SLE and other CTDs such as mixed connective tissue disease (MCTD), scleroderma, and PMR; polyarticular gout or pseudogout; the arthritis of subacute bacterial endocarditis; the arthritis secondary to malignancy; and the seronegative spondyloarthropathies. The diagnosis of RA is based on the history, physical examination, and laboratory findings.

Which serologic tests may be useful in the diagnosis of RA?

RFs are autoantibodies directed against the Fc portion of IgG. In RA, RF has a sensitivity of approximately 80% and specificity of 80%. Therefore, RF is detected in approximately 80% of patients with RA but it is nonspecific and can be detected in many other disorders such as other CTDs and chronic viral or bacterial infections. Anti-CCP antibodies are directed against citrulline-modified arginine residues in a protein. In RA, anti-CCP antibodies have a sensitivity of 60% to 75% and a high specificity of 90% to 96%. Therefore, anti-CCP antibodies are usually detected only in RA. Patients with RA who have a positive RF and/or anti-CCP antibodies are at a higher risk of developing erosive joint destruction and

debility. An elevated ESR or C-reactive protein (CRP) level suggests the presence of an acute inflammatory disease. A complete blood count may show an anemia of chronic (inflammatory) disease. ANAs are found in 30% of patients with RA, usually in a low titer with a negative ANA profile, and are of little diagnostic value.

CASE DISCUSSION

What is the primary pathophysiologic process in RA?

The joint disease in RA begins as inflammation in the synovium and involves the infiltration of macrophages, T cells, and B cells. The synovial tissue proliferates and can grow over the cartilage and bone. This inflammatory proliferative synovitis is known as pannus. The products of macrophages, interleukin 1 (IL-1) and TNF- α , and fibroblasts are abundant in the rheumatoid synovium. The overall process can result in cartilage loss and erosive joint destruction.

What are four characteristic radiographic findings in RA, and what are the mechanisms responsible for their development?

The soft tissue swelling seen on radiographic studies in patients with RA is due to the inflamed, proliferative synovitis. Joint space narrowing results from the loss of articular cartilage; the result of destructive enzymes produced by synovial fibroblasts, and chondrocytes. Juxtaarticular osteopenia is due to the loss of calcium in bones surrounding the inflammatory arthritis and results from the effects of prostaglandins, IL-1, and TNF- α , which are released by the inflamed synovium. Marginal erosions are produced by the proliferative synovitis as it extends into the subchondral bone at the joint margins.

What are the four most common extraarticular manifestations of RA?

The four most common extraarticular manifestations of RA are subcutaneous nodules (rheumatoid nodules), carpal tunnel syndrome, interstitial lung disease, and Felty's syndrome (splenomegaly and neutropenia in the setting of RA). Other extraarticular features include ocular involvement (keratoconjunctivitis sicca, episcleritis, and scleritis), additional pulmonary involvement (pleural disease, nodules, bronchiolitis, and pulmonary hypertension), cardiac involvement (pericarditis and rare myocarditis), and rheumatoid vasculitis.

The natural history of the joint disease in patients with RA assumes what three patterns?

The natural history of RA may consist of a monocyclic pattern (20% of patients), although in retrospect some of these cases may have been a viral-induced, self-limited polyarthritis; a polycyclic pattern (70% of patients) with repeated episodes of active disease interspersed with periods of inactivity; or a progressive pattern (10% of patients) with increasing joint involvement and no disease-free intervals.

What is the treatment for RA?

Early detection and suppression of inflammatory synovitis will likely prevent the progression of cartilage and bony destruction along with functional impairment. NSAIDs and low-dose corticosteroids can provide rapid relief of pain and stiffness. Early in the disease (within 3 months), treatment with DMARDs should be initiated in most patients. These agents include hydroxychloroquine, sulfasalazine, MTX, and leflunomide. The choice of DMARD is a clinical decision based on severity of disease and prognosis. MTX is the most commonly prescribed DMARD. An approach to treatment of RA would be to initiate MTX with rapid dose escalation or MTX in combination with other DMARDs such as hydroxychloroquine and/or sulfasalazine. If the disease is refractory to this treatment, an anti-TNF biologic agent should be considered with continuation of MTX. The available anti-TNF agents are etanercept, infliximab, and adalimumab. Another option is anakinra, an IL-1 receptor antagonist. New therapies for refractory RA include abatacept, cytotoxic T-lymphocyte associated antigen 4-Ig, and the B-cell depleting monoclonal antibody, rituximab. When joints become severely damaged because of chronic RA, reconstructive orthopaedic surgical procedures may be performed to help restore function.

ANSWERS TO CASE 41:

What is the likely diagnosis?

The patient has acute gonorrhoea and gonococcal arthritis. The X-ray of the knee is normal. The diagnosis is made by microscopy of the discharge, which should show Gram- positive diplococci, and culture of an urethral swab. The swab should be inoculated onto fresh appropriate medium straight away and kept at 37°C until arrival at the laboratory. Immediate treatment on clinical grounds with ciprofloxacin is indicated; penicillin should be reserved for gonorrhoea with known penicillin sensitivity, to prevent the development of resistant strains. Septic monoarthritis is a complication of gonorrhoea; other metastatic infectious complications are skin lesions and, rarely, perihepatitis, bacterial endocarditis and meningitis.

How would you investigate and manage this patient?

The patient disclosed that he had had unprotected sexual intercourse with prostitutes in Thailand and Singapore; he had had no intercourse following return to the UK so no follow-up of contacts was necessary. For advice on precautions and investigation for other sexually transmitted diseases he was referred to the sexually transmitted diseases (STD) clinic.

Clinical pearls

- > All students and doctors should be confident in eliciting a sexual history.
- > Accurate sexual histories are more likely when the patient feels confidence and empathy with the interviewer.
- > Contact tracing is an important element of management of sexually transmitted disease.

ANSWERS TO CASE 42:

A 75-year-old white woman tried to stop her fall using her outstretched right hand, heard a “snap,” and felt immediate pain. Her medical history is remarkable only for menopause at age 50 years and hypertension that is well controlled with diuretics. She does have a 50-pack per year history of smoking. She has a swollen, deformed, right distal forearm and wrist, with limited mobility because of pain, and good radial pulses and capillary refill in the right fingernail beds. An X-ray confirms a fracture of the right radial head, and the radiologist notes osteopenia.

- > Risk factor for fracture: Osteoporosis.
- > Causes of this condition: Decreased bone strength as a consequence of demineralization and increased bone turnover as a result of decreased levels of sex steroids (estrogen and testosterone), medications, other hormonal conditions, or diseases of decreased calcium absorption.
- > Preventive measures: Several medications are available to increase bone density, which may decrease the risk of future fractures. Also, her physician would want to work with her to prevent future falls by limiting unnecessary medications that may cause instability, making changes in the home environment, and evaluating her gait, visual acuity, and peripheral sensory system. The patient should be advised to quit smoking.

ANALYSIS

Considerations

This 75-year-old woman with a fracture after a fall likely sustained the fracture because of osteoporosis. Her risk factors for osteoporosis are her race, smoking history, postmenopausal state without hormone replacement therapy, and thin physique. Osteoporosis puts her at risk for future fractures with substantial morbidity, such as painful vertebral compression fractures or incapacitating hip fractures. She requires intervention to reduce her risk of fractures as well as her risk of falls.

Approach to osteoporosis

Definitions

BISPHOSPHONATES: Synthetic carbon phosphate compounds (alendronate, risedronate, ibandronate) that build bone mass by binding to pyrophosphatase in bone and by inhibiting osteoclast bone resorption.

OSTEOPENIA: T score between -1.0 and -2.5 standard deviations (SD) below the mean.

OSTEOPOROSIS: Decrease in bone mass leading to increased bone fragility and predisposing to fracture of the hip, vertebrae, and long bones, with a defined bone mineral density (BMD) less than 2.5 SD below the mean of young healthy adults.

T SCORE: BMD comparison against young healthy adults (in standard deviations from the mean).

Clinical approach

Osteoporosis is an important health issue because the resultant bone fractures cause a great deal of morbidity in chronic pain, loss of independence, and loss of function, as well as mortality. Risk factors for the development of osteoporosis include a low peak skeletal density reached in young adulthood, increasing age, loss of steroid hormone production (menopause or hypogonadism), smoking, nutritional deficiencies, and genetically low bone density. Approximately 14% of white women and 3% to 5% of white men will develop osteoporosis in their lifetime. The prevalence is lower in other ethnic groups.

Osteoporosis can be either idiopathic or a manifestation of another underlying disease process. Probably the most common form of secondary osteoporosis is caused by glucocorticoid excess, usually iatrogenic steroid use for an inflammatory disease such as rheumatoid arthritis. Patients, both men and

women, with rheumatoid arthritis are susceptible to accelerated bone loss with even low doses of glucocorticoids. Gonadal deficiency is another common cause, which is seen physiologically in menopausal women but is seen pathologically in women who are amenorrheic (eg, female athletes such as gymnasts or marathon runners) or as a result of hyperprolactinemia. Men with gonadal failure for whatever reason also are prone to develop osteoporosis.

Osteoporosis is a common feature of several endocrinopathies. Patients with hyperparathyroidism will develop osteoporosis because of increased calcium mobilization from bone. Long-standing hyperthyroidism, either naturally occurring, as in Graves disease, or as a result of excessive replacement of levothyroxine in patients with hypothyroidism, will also lead to accelerated bone loss. Malnutrition and nutritional deficiencies are causative and are often seen in patients with malabsorption; for example, most patients, both men and women, with celiac sprue have osteoporosis. Certain medications, such as cyclosporine, antiepileptics, heparin, and gonadotropin-releasing hormone (GnRH) inhibitors, among others, may accelerate bone loss.

Peak bone density occurs in young adulthood under the influence of sex steroid hormone production. Other influential factors include genetics, which may account for 80% of total bone density, adequate calcium intake, and level of physical activity, especially weight-bearing activity. The type of bone growth at this stage is called *modeling*. After skeletal maturation is reached, the bone growth enters a new phase, termed *remodeling*, in which repairs are made to damaged bone, existing bone is strengthened, and calcium is released to maintain serum levels under the influence of estrogens, androgens, parathyroid hormone, vitamin D, and various cytokines and other hormones. The activity of the osteoclasts approximates the activity of the osteoblasts in that overall bone density remains stable. However, after age 35 years, bone breakdown begins to exceed bone replacement, and this increases markedly after menopause as a consequence of increased osteoclast activity.

Diagnostic approach

The benefits and costs of universal screening for osteoporosis are unclear. Rather, a targeted approach is advocated. Those with a family history or other risk factors should be offered screening, as well as patients undergoing a chronic drug (steroid) therapy that may lead to osteoporosis. Currently, all women older than 65 years or those who have sustained a fracture before age 65 years are recommended to undergo BMD testing. Dual-energy X-ray absorptiometry (DEXA scan) is the technique used to define diagnostic thresholds; however, whether the hip, spine, or forearm is the best site for screening is not clearly established. DEXA scan results can be expressed as a Z score, which compares BMD to that in persons of the same age, and a T score, which compares to the young adult normal range. T scores are more useful for predicting fracture risk. Every 1 SD decrease in BMD below the mean doubles the fracture risk. As mentioned, osteoporosis is defined as a T score of -2.5 SD.

Other laboratory evaluations should routinely be considered in patients with osteoporosis. The serum levels of calcium, phosphorus, and alkaline phosphatase should be normal in patients with osteoporosis, although the alkaline phosphatase level sometimes is mildly elevated in the presence of a healing fracture. Laboratory abnormalities should prompt consideration of alternative diagnoses for the bone disease: hypercalcemia in hyperparathyroidism or hypocalcemia in osteomalacia.

If a patient suffers a pathologic fracture, that is, one with minimal trauma, other diagnoses must be excluded. Osteomalacia is defective mineralization of bone matrix with accumulation of unmineralized osteoid and is most often caused by vitamin D deficiency or phosphate deficiency.

Patients with osteomalacia frequently have diffuse bone pain and tenderness, proximal muscle weakness, and laboratory abnormalities such as elevated alkaline phosphatase level and low or low to normal calcium level. In the absence of fractures, patients with osteoporosis should have no bone pain or laboratory abnormalities. Both of these disease processes can coexist. A less common bone disease is Paget disease, which is characterized by disorganized bone remodeling with a high alkaline phosphatase level causing weakened and enlarged bones with skeletal deformities. Other important causes of pathologic fracture that must be considered include malignancy, such as multiple myeloma or metastatic disease, and vertebral osteomyelitis.

Treatment

Treatment takes a multifaceted approach. Adequate calcium intake, 1000 to 1200 mg/d for premenopausal women and adult men to prevent bone loss and 1500 mg with 400 to 800 IU of vitamin D per day for postmenopausal women, leads to decreased fractures. Estrogen replacement can increase bone density and reduce fracture, as can the use of bisphosphonates, both in combination with calcium and

vitamin D. Bisphosphonates can lead to severe esophagitis and must be used with caution in individuals with gastric reflux disease. Bisphosphonates should be taken on an empty stomach, with a large quantity of water, and the patient should remain in the upright position for at least 30 minutes. Selective estrogen receptor modifiers are used for treatment of osteoporosis as well.

Weight-bearing physical activity decreases bone loss and improves coordination and muscle strength, which may prevent falls. Ensuring that patients can see adequately, that they use a cane or walker if needed, that throw rugs are removed, that patients have railings to hold on to in the shower or bath, or that they wear hip protectors can further decrease the risk of life-altering bone fractures.

Comprehension questions

1. Which of the following patients is most likely to be a candidate for bone mineral density screening?
 - A. A 65-year-old, thin, white woman who smokes and is 15 years postmenopausal
 - B. A 40-year-old white woman who exercises daily and still menstruates
 - C. A healthy 75-year-old white man who is sedentary
 - D. A 60-year-old overweight African American woman
 - E. A 35-year-old asthmatic woman who took prednisone 40 mg/d for a 2-week course 1 week ago
2. During which of the following periods in a woman's life is the most bone mass accumulated?
 - A. Ages 15 to 25
 - B. Ages 25 to 35
 - C. Ages 35 to 45
 - D. Ages 45 to 55
3. A 60-year-old woman presents with the results of her DEXA scan. She has a T score of -1.5 SD at the hip and -2.5 at the spine. Which of the following is the most accurate interpretation of these results?
 - A. She has osteoporosis at the spine and osteopenia at the hip.
 - B. She has osteoporosis in both areas.
 - C. This is a normal examination.
 - D. She has osteoporosis of the hip and osteopenia at the spine.
 - E. You need to know the Z score.
4. You see a 70-year-old woman in your office for a routine checkup, and you order a DEXA scan for bone mineral density screening. The T score returns as -2.5 standard deviations SD in the spine and -2.6 in the hip. Which of the following statements is most accurate?
 - A. This patient has osteopenia.
 - B. Estrogen replacement therapy should be started with an anticipated rebuilding of bone mass to near-normal within 1 year.
 - C. Swimming will help build bone mass.
 - D. Bisphosphonates would reduce the risk of hip fracture by 50%.

Answers

1. A. Of the choices, this woman is the only individual with risk factors. Risk factors include white race, age, postmenopausal status, smoking, positive family history, poor nutritional status, and chronic treatment with a drug known to predispose to bone loss.
2. A. The time of greatest accumulation of bone mass in women is during adolescence.
3. A. The T score is the number of standard deviations of a patient's bone mineral density from the mean of young, adult, white women. It is the standard measurement of bone mineral density used by the World Health Organization. A score of -2.5 SD is the definition of osteoporosis. A Z score is the number of standard deviations from the mean bone mineral density of women in the same age group as the patient.
4. D. Estrogen primarily inhibits loss of bone mass, although it can help to build a modest amount of bone mass. Weight-bearing exercise, and not swimming, is important in preventing osteoporosis. Bisphosphonates decrease the incidence of hip fractures by 30% to 50%.

Clinical pearls

- > Bone mineral density screening should be offered to patients with risk factors for osteoporosis and to all women older than 65 years.
- > Every 1 standard deviation (SD) decrease in bone mineral density below the mean of young adults doubles the fracture risk. Osteoporosis is defined as a T score of -2.5 SD.
- > Patients with osteoporosis should have normal serum calcium, phosphorus, and alkaline phosphatase levels. Laboratory abnormalities should prompt a search for an alternative diagnosis.
- > Fractures can have a devastating effect upon a patient's quality of life, and a multifaceted approach

through nutritional counseling, home improvements, gait stabilization through exercise and with canes or walkers, and medical interventions to improve eyesight or with medications to improve bone density should be offered to patients at risk.

> In patients with a pathologic fracture, osteoporosis is a diagnosis of exclusion; osteomalacia, Paget disease, and metastatic malignancies also must be considered.

ANSWERS TO CASE 43:

The patient is a 56-year-old obese woman with complaints of activity-related joint disease in the left DIP and right knee. There is no evidence of synovitis on examination.

- > Next step: Obtain erythrocyte sedimentation rate (ESR) and plain X-rays of the hand and knee.
- > Most likely diagnosis: Osteoarthritis (OA).
- > Best initial treatment: Acetaminophen up to 4 g qd.

ANALYSIS

Considerations

This patient’s history and examination are characteristic of OA. Laboratory work, typically negative for inflammatory arthritis, and X-rays will confirm the diagnosis. The most important features are the gradual onset, the lack of active synovitis, and the fact that her symptoms worsen with activity. If there were evidence of inflammation or joint effusion, then the best next step would be to aspirate the fluid from the joint and send it for various studies, including Gram stain and culture to assess for infection, crystal analysis to assess for gout or pseudogout, and cell count to assess for inflammation.

Approach to osteoarthritis

Definitions

BOUCHARD NODES: Bony enlargement of proximal interphalangeal (PIP) joints, often asymptomatic.

CREPITUS: A creaking or hook and loop (Velcro)-like sound made by a joint in motion. Typically not painful.

HEBERDEN NODES: Bony enlargement of DIP joints, often asymptomatic.

SYNOVITIS: Inflammation of the joint space characterized by redness, swelling, and tenderness to touch.

Clinical approach

OA is the most common joint disease in adults. The disease affects women more often than men. The incidence increases sharply in the fifth and sixth decades of life. OA begins insidiously, progresses slowly, and eventually may lead to disability, recurrent falls, inability to live independently, and significant morbidity.

Patients with OA often experience joint stiffness, which occurs with activity or after inactivity (“gel phenomena”) and lasts for less than 15 to 30 minutes. This is in contrast to the morning stiffness of patients with an inflammatory arthritis (eg, rheumatoid arthritis [RA]), which often lasts for 1 to 2 hours and often requires warming, such as soaking in a hot tub, to improve. Early in the disease, there are no obvious findings. There may be some crepitus (creaking sound) in the joint, and, unlike inflammatory arthritis, there is often no or minimal tissue swelling (except in the most advanced disease). Bony prominences, especially in the DIP/PIP joints, can occur later. Pain seen in OA typically can be reproduced with passive motion of the joint. Table 43-1 lists the patterns of typical joint involvement.

Laboratory examination typically is unremarkable; inflammatory markers such as ESR, creatinine phosphokinase (CPK), and white blood cells (WBCs) all are normal. Likewise, autoimmune studies such as antinuclear antibody (ANA), rheumatoid factor, and complement levels also are normal. If the joint is aspirated, then examination of the synovial fluid also reflects a lack of inflammation: WBCs less than 2000/mm³, protein less than 45 mg/dL without crystals, and glucose equal to serum. X-ray evaluation in OA may show osteophytes that are the most specific finding in the disease but might not be found early. Other characteristics seen on X-rays include joint space narrowing, subchondral sclerosis, and subchondral cysts.

Table 43-1. Osteoarthritis/degenerative joint disease

Joints affected in oa (in order of involvement/frequency)	Joints spared
Hands (often asymmetric)	Hands (all except DIP/PIP/CMP)

<ul style="list-style-type: none"> . DIP (Heberden nodes) . PIP (Bouchard nodes) . Carpal metacarpophalangeal (CMP) of thumb Knee Hip Feet (usually first toe metatarsophalangeal joint)	Wrist Elbow Shoulder Spine
---	-------------------------------------

It is critical to differentiate OA from other conditions that may present similarly. Periarticular pain that is not reproduced with passive motion suggests bursitis or tendonitis. Prolonged pain lasting for more than 1 hour points toward an inflammatory arthritis. Intense inflammation suggests one of the microcrystalline diseases (gout/pseudogout) or infectious arthritis. Systemic constitutional symptoms, such as weight loss, fatigue, fever, anorexia, and malaise, indicate an underlying inflammatory condition, such as polymyalgia rheumatic, rheumatoid arthritis, systemic lupus erythematosus, or a malignancy, and generally demands aggressive evaluation.

Management

Education is critical. Encourage the patient to stay active, because not using the joint can cause further immobility. Multiple short periods of rest throughout the day are better than one large period.

Equipment such as canes and/or walkers are helpful for patients with advanced disease because these patients are less stable and, as a result, have frequent falls. Physical therapy in the form of heat applied to the affected joints in early disease often is helpful. Perhaps the most important intervention is having the patient maintain full/near-full range of motion with regular exercise.

Pharmacotherapy early in the course of the disease consists primarily of acetaminophen, the mainstay of therapy. It is well tolerated and as effective as nonsteroidal anti-inflammatory drugs (NSAIDs; both nonprescription and prescription strength). The nutraceutical agents glucosamine and chondroitin are as effective as the NSAIDs, but their onset of action is a bit slower. NSAIDs inhibit the enzyme cyclooxygenase (COX) in the prostaglandin catabolism pathway and work as either COX-1 or COX-2 inhibitors. For a long time, COX-1-type NSAIDs were the most commonly prescribed drug for OA. However, COX-1 NSAIDs have well-documented side effects of gastrointestinal irritation and bleeding and renal damage. The COX-2 inhibitor class has the same anti-inflammatory potential, with fewer gastrointestinal side effects. Recent evidence about increased risk of cardiovascular (CV) events in patients using COX-2 inhibitors have led to the withdrawal of rofecoxib and valdecoxib from the market, however, and the remaining members of the class should not be used in patients with known CV disease or multiple CV risk factors. Oral steroids are generally not used to treat OA. Intra-articular steroids may be rarely useful for long-term treatment and can be helpful for the rare inflammation of a loose cartilage fragment, which may cause the joint to "lock up."

Surgery is reserved for only the most severe cases, which include patients who have major instability, a loose body in the joint, intractable pain of advanced disease, or severe functional limitation. Joint replacement is the typical procedure.

Comprehension Questions

1. Which of the following is most likely to be associated with advanced OA?

- A. Disability with recurrent falls and inability to live alone
- B. Joints with redness and effusion
- C. Best treated with oral steroids
- D. Improvement throughout the day after approximately 1 to 2 hours of "unfreezing the joint"

Match the following disease processes (A-F) to the clinical setting described in Questions 2 to 5.

- A. Gonococcal arthritis
- B. Gout
- C. Pseudogout
- D. Osteoarthritis
- E. Rheumatoid arthritis
- F. Systemic lupus erythematosus

2. Symmetric bilateral ulnar deviation of both hands in a 42-year-old woman

3. Painful, swollen metatarsophalangeal great toe (unilateral) with redness and warmth after eating steak and shrimp dinner in a 45-year-old man

4. Acute onset of unilateral elbow swelling, warmth, and tenderness and cervical discharge in a 25-

year-old woman

5. Unilateral nontender bony enlargement of the first DIP and activity-related right hip pain in a 68-year-old woman

6. A 72-year-old man complains of painful joints in his hips and knees, which you have diagnosed as osteoarthritis. Which of the following is the best agent to prescribe for this patient?

- A. Naproxen sodium
- B. Celecoxib
- C. Oral prednisone
- D. Intra-articular prednisone
- E. Acetaminophen

Answers

1. A. Degenerative joint disease is a major cause of decreased functional status in elderly patients and requires ongoing treatment and evaluation by the physician to try to improve symptoms and to promote mobility. Oral steroids are not helpful in this condition.

2. E. Rheumatoid arthritis gives the ulnar deviation of the fingers.

3. B. Gouty arthritis often affects the first metatarsophalangeal joint and can be precipitated by various foods or alcohol.

4. A. Cervical discharge and inflammatory joint are consistent with gonococcal arthritis, which can also present as a migratory arthritis.

5. D. The location and asymmetry of joint involvement, lack of inflammatory signs, and worsening with exertion all are characteristic of OA.

6. E. Acetaminophen is the first agent of choice in the treatment of early osteoarthritis.

Clinical Pearls

> Osteoarthritis is the most common articular disease of adults, most often affecting the distal interphalangeal joints > proximal interphalangeal joints knees > hip joints.

> Pain in osteoarthritis is worsened with activity and is not associated with morning stiffness.

> No pharmacologic agents that modify or stop disease progression are available. Treatment is aimed at symptom relief.

> Initial pharmacologic therapy should be acetaminophen. Joint replacement for severe osteoarthritis is reserved for patients with intractable pain despite medical therapy and for those with severe functional limitations.

ANSWERS TO CASE 44:

What are four possible diagnoses in this patient?

Four possible diagnoses in this patient are Wegener's granulomatosis, Churg-Strauss syndrome (allergic granulomatosis), intranasal drug abuse, or a lung tumor. Churg-Strauss syndrome occurs primarily in patients with a history of allergies or asthma and is often associated with peripheral eosinophilia. ANCA reacting with human neutrophil elastase can occur in cocaine-induced midline destructive lesions. The saddle-nose deformity and palpable purpura would be uncommon manifestations of a primary lung carcinoma.

What diagnostic studies or procedures might be of value in this patient?

Nasopharyngeal examination with biopsy, CT scan of the sinuses and chest, creatinine and urinalysis, and bronchoscopy with biopsy or open lung biopsy would all be helpful in the evaluation of this patient's disorder. An ANCA should be ordered because most patients with systemic Wegener's granulomatosis are c-ANCA positive and have antiproteinase 3 antibodies. In approximately 60% of patients, c-ANCA titers correlate with Wegener's disease activity.

Which disorders are associated with p-ANCA?

A p-ANCA may be present due to a variety of different antibodies directed against myeloperoxidase, elastase, cathepsin, and lactoferrin, and can occur in many different diseases. Diseases associated with p-ANCA directed against myeloperoxidase include Wegener's granulomatosis (10%), Churg-Strauss syndrome (50%), MPA (50% to 80%), and idiopathic crescentic glomerulonephritis (65%). Nonspecific p-ANCAs directed against other various proteins can occur in CTDs, Crohn's disease, ulcerative colitis, sclerosing cholangitis, cystic fibrosis, chronic infections, and rare drug-induced vasculitic syndromes associated with propylthiouracil, hydralazine, and minocycline.

What constitutes appropriate therapy for this patient with Wegener's granulomatosis?

Standard therapy for Wegener's granulomatosis includes both high doses of corticosteroids and oral cyclophosphamide. Oral trimethoprim/sulfamethoxazole prophylaxis against *Pneumocystis carinii* should be considered while on the above therapy.

CASE DISCUSSION

Vasculitis should be suspected in patients presenting with any combination of what clinical manifestations?

Vasculitis comprises a heterogeneous group of diseases characterized by inflammatory changes in the blood vessels with subsequent impairment of flow and tissue/organ ischemia. Patients present with a multisystem inflammatory disease often with fever of unknown origin and/or unexplained constitutional symptoms; suspicious skin lesions such as ulcers, livedo reticularis, and palpable purpura; ischemic neuropathies; and rapidly progressive organ dysfunction such as strokes, pulmonary renal syndromes, and other organ ischemia.

Name the primary vasculitic disorders based on the dominant vessel size and ANCA.

Vasculitides affecting large arteries:

- Takayasu's arteritis: aortic arch and its branches, can involve any part of the aorta; more claudication of upper than lower extremities, central nervous system events; granulomatous panarteritis.
- Giant cell (temporal) arteritis (GCA): temporal arteries, vessels originating from the aortic arch, other arteries less common; temporal headache, jaw claudication, scalp tenderness, visual loss; arteritis with giant cells and disruption of the internal elastic lamina.

Vasculitides affecting predominantly medium-sized arteries:

- Polyarteritis nodosa (PAN): small- and medium-sized arteries; may affect any organ, but skin, joints, peripheral nerves, gut, and kidney are most commonly involved; focal but panmural necrotizing arteritis with a predilection for involvement at the vessel bifurcation.
- Kawasaki disease: small- and medium-sized arteries; acute febrile illness primarily affecting infants and young children; fever, prominent mucocutaneous changes, cervical lymphadenopathy, polymorphous rash, erythema and edema of hands and feet, desquamation, myocarditis, coronary vasculitis; probable infectious vector resulting in cytokine-mediated endothelial damage.

Vasculitides affecting predominantly small vessels (ANCA-positive):

- Wegener's granulomatosis: small- and medium-sized arteries; upper respiratory tract (sinuses), lungs, and kidneys, may affect other organs; pauciimmune, necrotizing, granulomatous arteritis usually associated with serum cytoplasmic antineutrophil cytoplasmic antibodies (c-ANCA) usually directed against proteinase 3 in the primary granules of neutrophils.
- Microscopic polyangiitis (MPA): arterioles, capillaries, and venules; pulmonary hemorrhage, glomerulonephritis, palpable purpura, peripheral neuropathy, joint and abdominal pain; pauciimmune, necrotizing vasculitis, serum perinuclear antineutrophil cytoplasmic antibodies (p-ANCA) usually directed against myeloperoxidase in the primary granules of neutrophils.
- Churg-Strauss syndrome: small arteries and venules; asthma, eosinophilia, multiorgan involvement [lungs, skin, peripheral nerves, gut, heart, and kidneys (rare)]; necrotizing extravascular granulomas and vasculitis of small arteries and venules, eosinophils present in early stage.

Vasculitides affecting predominantly small vessels (ANCA-negative):

- Henoch-Schonlein purpura (HSP): arterioles and venules; palpable purpuric skin lesions on lower extremities, arthritis, abdominal pain, hematuria; leukocytoclastic (neutrophilic perivascular/transmural infiltrate) or necrotizing vasculitis often with IgA deposition.
- Cutaneous leukocytoclastic angiitis: arterioles and venules; palpable purpuric skin lesions, arthralgias, systemic symptoms may be present, usually secondary to immune complexes [drugs, bugs (infections), CTD or malignancy]; leukocytoclastic vasculitis.
- Cryoglobulinemic vasculitis: cryoglobulins are immunoglobulins that are reversibly precipitated by reduced temperatures; cryoglobulins are deposited in small vessels including glomerulocapillaries; purpura, arthralgias, peripheral neuropathy, Raynaud's phenomenon, pulmonary hemorrhage, glomerulonephritis are possible; often RF and hepatitis C antibody positive.

What serologic tests or diagnostic procedures should be performed in patients with suspected vasculitis?

The diagnostic evaluation of a patient with suspected vasculitis should be based on the clinical situation but often includes a chest radiographic study, ESR, CRP, a complete blood count with differential, liver function tests, CPK, creatinine and urinalysis, tests for the presence of ANAs, ANCAs

and RF, cryoglobulins, and biopsy of a skin lesion or an involved organ. In some types of vasculitis, complement levels may be low secondary to consumption. An ESR greater than 100 mm per hour and a CRP greater than 10 mg/dL in the absence of a widespread malignancy or bacterial infection should suggest a vasculitic process.

What more extensive procedures may be of value in helping to establish the diagnosis of a specific form of vasculitis?

More extensive diagnostic procedures for establishing the diagnosis of a specific form of vasculitis include arteriography of the mesenteric vessels if a tissue biopsy is inaccessible, and an electromyography with evaluation of nerve conduction velocities to evaluate a peripheral neuropathy or a mononeuritis multiplex. A computed tomography (CT) scan of the sinuses and chest is indicated if a diagnosis of Wegener's granulomatosis is being considered.