

**MINISTRY OF PUBLIC HEALTH OF UKRAINE
ZAPOROZHYE STATE MEDICAL UNIVERSITY**

**DEPARTMENT OF PROPEDEUTICS OF INTERNAL DISEASES WITH PATIENTS'
CARE**

THE BASIS OF ELECTROCARDIOGRAPHY

**Manual for III–year international faculty students'
independent work**

Zaporozhye 2016

UDK 616.1 / 4-07

Authors: Doctor of Sciences (Medicine), Professor - Sivolap V.V.; assistant-professor Likhassenko I.V., Oleynik A.I.; assistant, c.s.m Avramenko N.F.

The manual are approved by the Central Methods Board of ZSMU

“02” June 2016

№ 5

Reviewers:

1. Sivolap V.D. - Head of department of internal diseases № 1 ZSMU, Doctor of Sciences (Medicine), professor;

2. Vizir V.A. - Head of department of internal diseases № 2 ZSMU, Doctor of Sciences (Medicine), professor.

GLOSSARY

Antiarrhythmia drugs – those commonly administered to counteract irregularities in cardiac rate or rhythm.

Arrhythmia - a cardiac rhythm disturbance due to a dysfunction in impulse formation or conduction.

Artifact - lines displayed on the ECG tracing which are not caused by the electrical impulses of the heart.

Atrium - the upper chambers of the heart which receive the return flow of venous blood.

Automaticity - the ability of the myocardial cells to discharge an electrical impulse.

Bundle of His - small band of cardiac muscle fibers that disperses the atrial contraction consistently to the ventricles.

Cardiac arrest - ventricular standstill. The heart stops beating and death can occur in one to three minutes.

Cardiac output - the amount of blood pumped by the heart per minute (cardiac output = Heart rate x Stroke volume).

Cardioversion - an electric shock, synchronized with the QRS complex or ventricular beat, that depolarizes the entire heart in order to allow the SA node to resume control.

Compensatory mechanism - ability of the heart to change rate and rhythm in order to maintain adequate cardiac output.

Coronary arteries - small vessels that originate from the aorta above the aortic valve and provide the blood supply to the heart.

Defibrillation - electrical shock not timed to the cardiac cycle. It depolarizes all fibrillating myocardial cells simultaneously, allowing the SA node to resume pacing.

Depolarization - process by which the impulse from the SA node stimulates the change of chemicals through the cell membrane. This reverses the electrical polarity of the myocardial cell.

Diastole - resting and filling phase of the cardiac cycle.

Ectopic beat - one arising from a focus outside the sinus node.

Electrocardiogram (ECG) - a graphic recording of the electrical activity produced by the heart muscle.

Electrodes - contacts applied to designated points on a patient's limbs or chest wall. They transmit the heart's electrical impulses to a graphic recorder.

EHA - electric heart axis.

EHMP - electric heart moving power.

Escape beat - one that arises from the junctional or ventricular tissue after a prolonged pause with no beats occurring.

Exit block - a type of conduction disturbance in which the impulse does not leave the place of origin.

Extrasystole - systole originating outside the sinus node; a premature beat is usually an extrasystole.

Fibrillation - arrhythmia characterized by disorganized electrical activity with erratic quivering of the heart muscle instead of a contraction of the chamber.

Ischemia - deficiency of blood supply to tissue because of arterial constriction or obstruction.

Isoelectric - neither negative nor positive in electrical potential; giving off no current, producing a straight line on the ECG.

Myocardial infarction - death of an area of cardiac muscle tissue due to inadequate blood oxygen supply.

Pacemaker (physiological) - normally the SA node, which sends out regular impulses to stimulate the myocardium.

Pacemaker artifact (blip or spike) - the ECG waveform produced by a mechanical pacemaker impulse. It can be either an upward or a downward deflection depending on how the pacing wires are connected to the pulse generator.

Parasympathetic nervous system - portion of autonomic system that acts to maintain a slow heart rate. The vagus nerve is the heart's connection for this system.

PAT - paroxysmal atrial tachycardia.

Precordial ECG waves - those emanating from chest leads of a 12-lead ECG.

P wave - the ECG representation of the electrical impulse going through the atria.

PVC - premature ventricular contraction.

QRS complex - the letters have no specific meaning; Q, R, and S waves represent the electrical impulse going through the ventricles.

Re-entry - an arrhythmia mechanism by which an impulse is conducted in one direction and returns through another pathway (echo beat). If this reactivates the earlier site, rapid repetitive firing occurs.

Refractory - not responsive to stimuli or treatment.

Repolarization - return of electrical potential to the normal (resting) state.

SA (sinoatrial) node - the normal physiological pacemaker in the heart.

Sensing - the mechanical ability of the artificial pacemaker to detect a natural contraction.

Sequential pacing (dual chamber pacing) - the use of two electrodes to pace the atria and then the ventricles in a way that approximates the normal heart cycle.

Sick sinus syndrome - a failing sinus node, manifested as severe slowing, blocking, or arresting of the SA node, or as an alternating sinus tachycardia-sinus bradycardia pattern.

Supraventricular tachycardia (SVT) - a general term for a rhythm disturbance that originates from the Bundle of His or above the ventricles.

Sympathetic nervous system - portion of autonomic nervous system that acts to increase the heart rate.

Systole - contraction phase of the cardiac cycle.

Vector - an electrical force of known magnitude and direction.

Ventricles The thick-walled, muscular lower chambers of the heart.

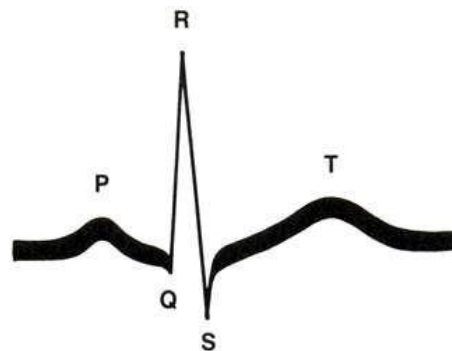
Vulnerable period - the time during the cardiac cycle when the ventricular cells are partially repolarized, but not completely ready for normal response. This occurs during the T wave. Stimulation at this time may produce an erratic rhythm response.

NORMAL ECG AND RELATED HEART ANATOMY

The electrocardiogram presents a visible record of the heart's electrical activity by means of a stylus that traces the activity on a continuously moving strip of special paper.

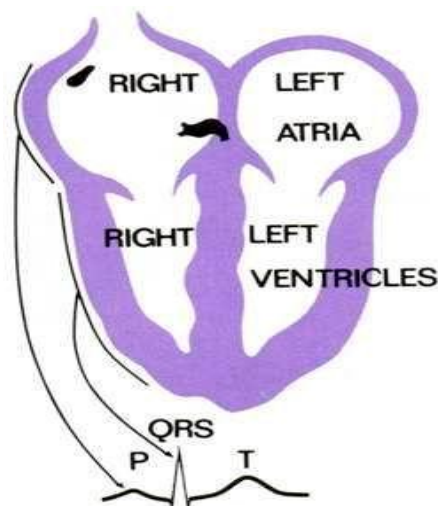
Normal ECG. All beats appear as a similar pattern, equally spaced, and have three major units: P wave, QRS complex, and T wave.

Normal single heartbeat



Normal single heartbeat. Each beat manifests as five major waves: P, Q, R, S, and T. The Q, R, and S all represent the same part of the heart (ventricles). They are usually referred to as a unit: the QRS complex.

The heart in relation to the ECG



The heart in relation to the ECG. Each wave represents transmission of an electrical impulse through the heart muscle (depolarization), which causes the muscle to contract and thus eject blood.

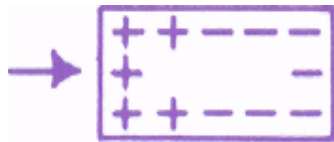- The P wave reflects the impulse going through the atria.
- The QRS complex reflects the impulse going through the ventricles.
- The T wave is produced by the electrical recovery (repolarization) of the ventricles.

Depolarization. As the electrical impulse moves across the cells of the myocardium, the polarity (negative or positive electrical charge) of the cells is changed.

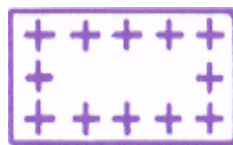The resting cell has a negative charge:




The electrical impulse carries a positive charge into the cells, changing the polarity:



This is called depolarization:



It is followed by a continuing wave of repolarization that restores the cell to its original charge:

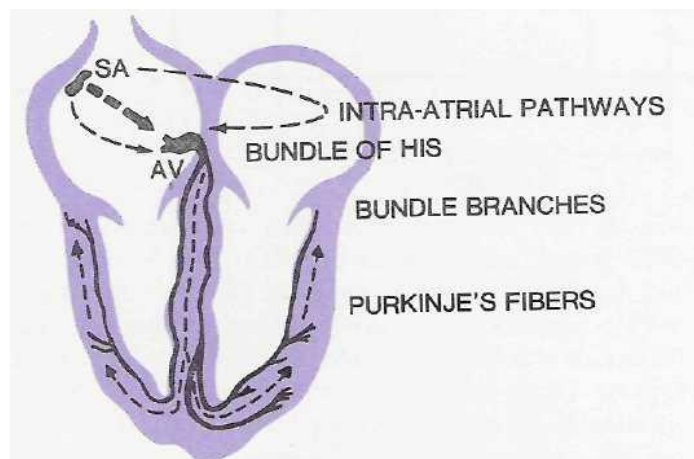


The cell is then ready to receive another stimulus.

Normal electrical pathway. The impulse is conducted to the muscle cells by way of specialized tissue that has automaticity and conductivity. All myocardial tissue has these properties, but they are developed to a greater degree in the conduction system.

The electrical impulse originates in the sinoatrial (SA) node - the normal physiological pacemaker - located near the top of the right atrium. The impulse spreads through intra-atrial pathways to the atrioventricular (AV) node located at the junction of the atria and ventricles. After a brief delay, the impulse continues through the bundle of His, the right and left bundle branches, and Purkinje fibers, and finally activates the ventricular muscle cells. Both the SA and AV nodes are innervated by the sympathetic system, which increases the heart rate, and by the parasympathetic system (vagus nerve), which slows the rate.

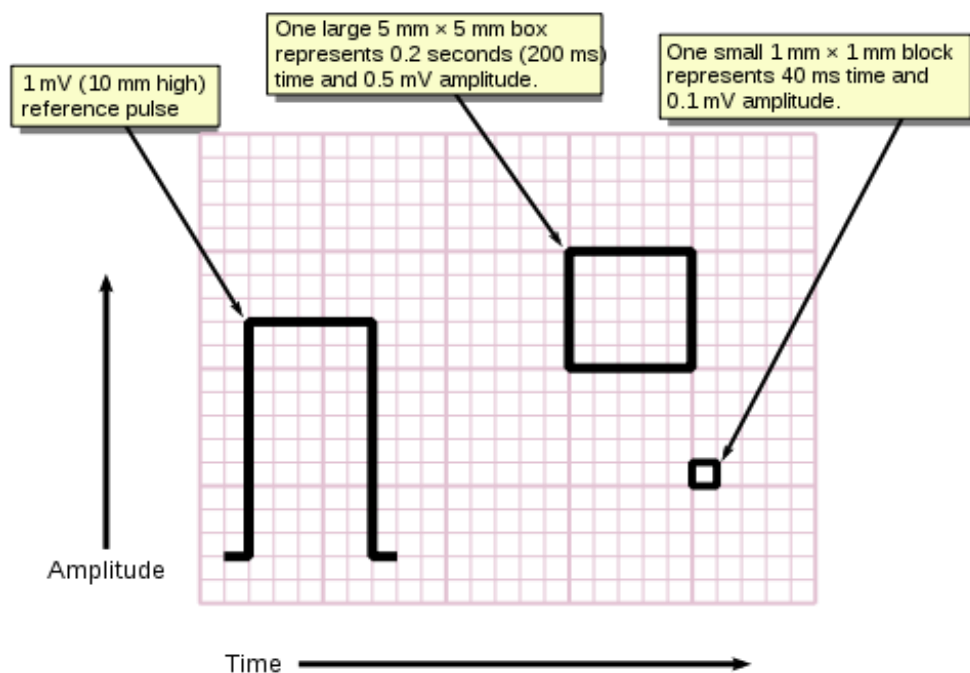
The SA node normally discharges impulses at a rate of 60-90 times per minute, AV junctional tissue at 40-60, and Purkinje fibers at 20-40. The pacemaker firing at the fastest controls the heartbeat. The presence of multiple pacemakers provides a reserve or backup system against cardiac arrest.



ECG paper. To understand the significance of each wave and interval, we need to know the significance of the small and large blocks on the ECG paper. The paper moves through the ECG machine at the speed of 50 mm per second (standard setting). One **small block** represents **0.02 second** on the horizontal line and 1 mm on the

vertical line. Since a **large block** is five small blocks wide and five high, each large block represents **0.1 second** (horizontal) and 5 mm (vertical). 10 mm = 1 millivolt of electrical activity.

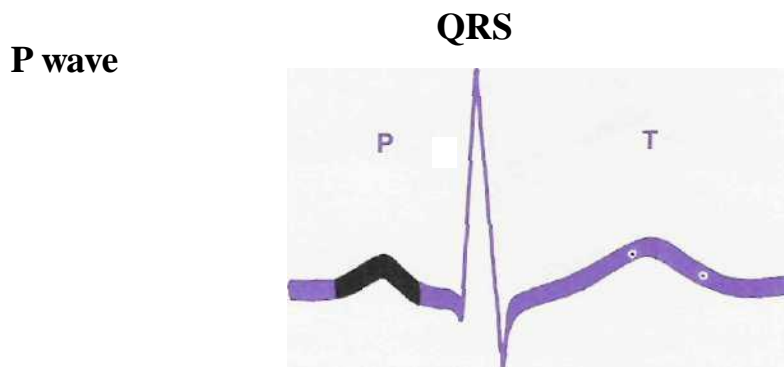
If speed of paper is **25 mm/s** - one **small block** represents **0.04 second** on the horizontal line and 1 mm on the vertical line. Since a large block is five small blocks wide and five high, each **large block** represents **0.2 second** (horizontal) and 5 mm (vertical). 10 mm = 1 millivolt of electrical activity. Wave's amplitude is measured in mm, duration – in seconds.



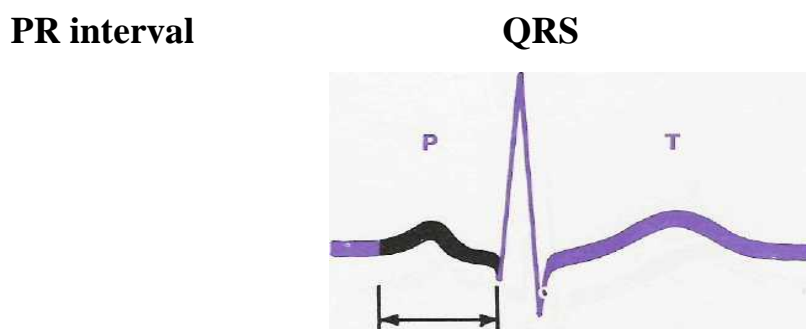
Now that we know these basic measurements and are familiar with the relation of the ECG waves to the heart anatomy, let's discuss the significance of each wave and interval:

The **P wave** is the first upward deflection and represents the atrial depolarization. As impulse at first cause excitation of the right atrium and then the left atrium, the ascending portion of P wave reflects depolarization of the right atrium, and descending portion reflects depolarization of the left atrium. Enlargement of the P wave might occur in such conditions as mitral stenosis or chronic obstructive pulmonary disease, which would cause atrial

hypertrophy. The *normal P-wave* has amplitude of about 1- 2 mm and duration of 0.1 s.



The **PR interval** extends from the beginning of the P wave to the onset of the QRS. It represents conduction of the impulse through the atria and the AV node. The PR interval is abnormally lengthened when the impulse is forced to travel at a slower rate, which can occur in arteriosclerosis, inflammation, insufficient oxygen supply, or scarring from rheumatic heart disease. It can also occur as an effect of depressant drugs or digitalis. The *normal PR interval* is 0.12-0.20 second wide.



The **QRS complex** consists of three deflections:

- **Q wave**, the downstroke before the R and represents depolarization of the interventricular septum;
- **R wave**, the first upward deflection and represents the process of depolarization of the ventricles;

- **S wave**, the downstroke following the R wave and represents depolarization of the basal parts of interventricular septum of right and left ventricles.

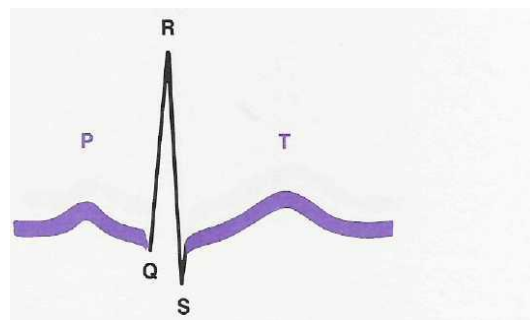
Not every QRS complex shows a discrete Q, R, and S wave, but the configuration is still referred to as the QRS complex to denote a ventricular impulse.

Q wave amplitude is small and does not normally exceed one-fourth amplitude of the R wave; the length of the Q wave does not exceed 0.03 second. The Q wave may be absent on an ECG. An enlarged Q wave may indicate a myocardial infarction.

The normal **R wave** amplitude is 5- 15 mm. In the chest leads R wave amplitude increases from V₁ to V₄, and then slightly decreases in V₅ and V₆ leads. A vertically enlarged R wave usually indicates enlarged ventricles.

The normal S wave amplitude is not exceed 20 mm. In the chest leads S wave amplitude decreases from V₁, V₂ to V₄, and in V₅ - V₆ leads S wave amplitude is very low or S wave may be even absent. Equal S wave and R wave amplitude in the chest leads are usually in the V₃ (“transition zone”) or rare between V₂ and V₃ or V₃ and V₄.

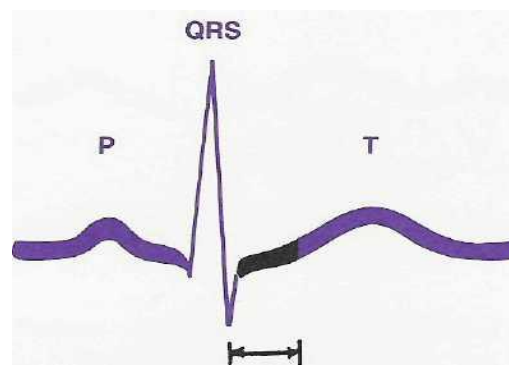
QRS complex



The QRS interval, measured from the beginning of Q wave to the end of S wave, represents the process of depolarization of the ventricles. The normal duration of the QRS is 0.06 – 0.10 second wide.

The **ST segment** begins at the end of the S wave (the point where the line turns right) and ends at the beginning of the T wave. The ST segment represents the period when all parts of the ventricles are in the depolarized state. It is elevated in an acute myocardial infarction or muscle injury. It is depressed when the heart muscle isn't getting a sufficient supply of oxygen - for example, during an episode of angina or coronary insufficiency. It may sag as an effect of digitalis. ST changes are usually transient.

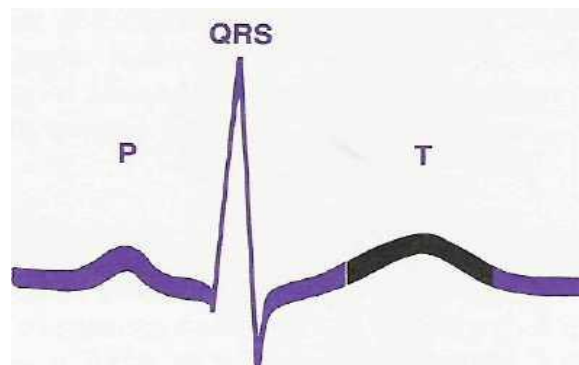
ST segment



ST SEGMENT

The **T wave** represents electrical recovery of the ventricular contraction. (The electrons are in the process of moving back into the normal resting position.) The T wave is flat or inverted in response to ischemia, position change, food intake, or certain drugs. It may be elevated when the serum potassium is elevated. The normal T wave duration is 0.12-0.16 second, amplitude – 2.5 – 6 mm.

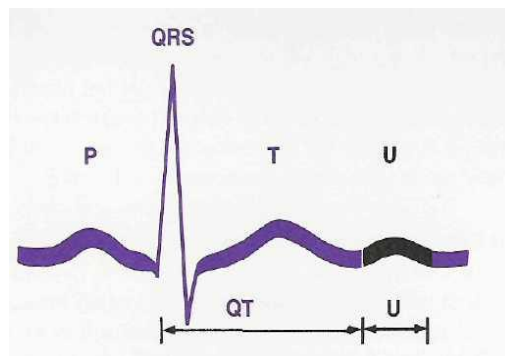
T wave



The **U wave** is a small upward deflection following the T wave. It is seldom present, but may occur when the serum potassium level is low.

The **QT interval** represents the time from the beginning of the Q wave (downward deflection following the P wave) through the QRS and the T wave. It includes the time until the T wave is completed (goes back to the baseline). The time of this interval should be less than one-half of the R-R interval (from the peak of one R wave to the peak of the next R wave). If the QT time is prolonged, it presents an extended opportunity for stray irritable impulses to excite the heart tissue and trigger dangerous ventricular rhythms. After the T wave is completed the tissue is repolarized and at rest, ready to respond normally. Impulses that arrive during the T wave find the ventricular tissue incompletely recovered and vulnerable to an erratic response. The Q-T interval in women is longer than in men (at the same heart rate). For example, at the rate of 60-80 beats per minute, the length of the Q-T interval in men is 0.32-0.37 second and in women: 0.35-0.40 second.

U wave, QT interval



THE APPLICATION AREAS OF ECG DIAGNOSIS

The main applications of the ECG to cardiological diagnosis include the following (Fig. 1):

1. The electric axis of the heart
2. Heart rate monitoring
3. Arrhythmias
 - a. Supraventricular arrhythmias
 - b. Ventricular arrhythmias
4. Disorders in the activation sequence
 - a. Atrioventricular conduction defects (blocks)
 - b. Bundle-branch block
 - c. Wolff-Parkinson-White syndrome
5. Increase in wall thickness or size of the atria and ventricles
 - a. Atrial enlargement (hypertrophy)
 - b. Ventricular enlargement (hypertrophy)
6. Myocardial ischemia and infarction
 - a. Ischemia
 - b. Infarction
7. Drug effect
 - a. Digitalis
 - b. Quinidine
8. Electrolyte imbalance
 - a. Potassium
 - b. Calcium
9. Carditis
 - a. Pericarditis
 - b. Myocarditis
10. Pacemaker monitoring

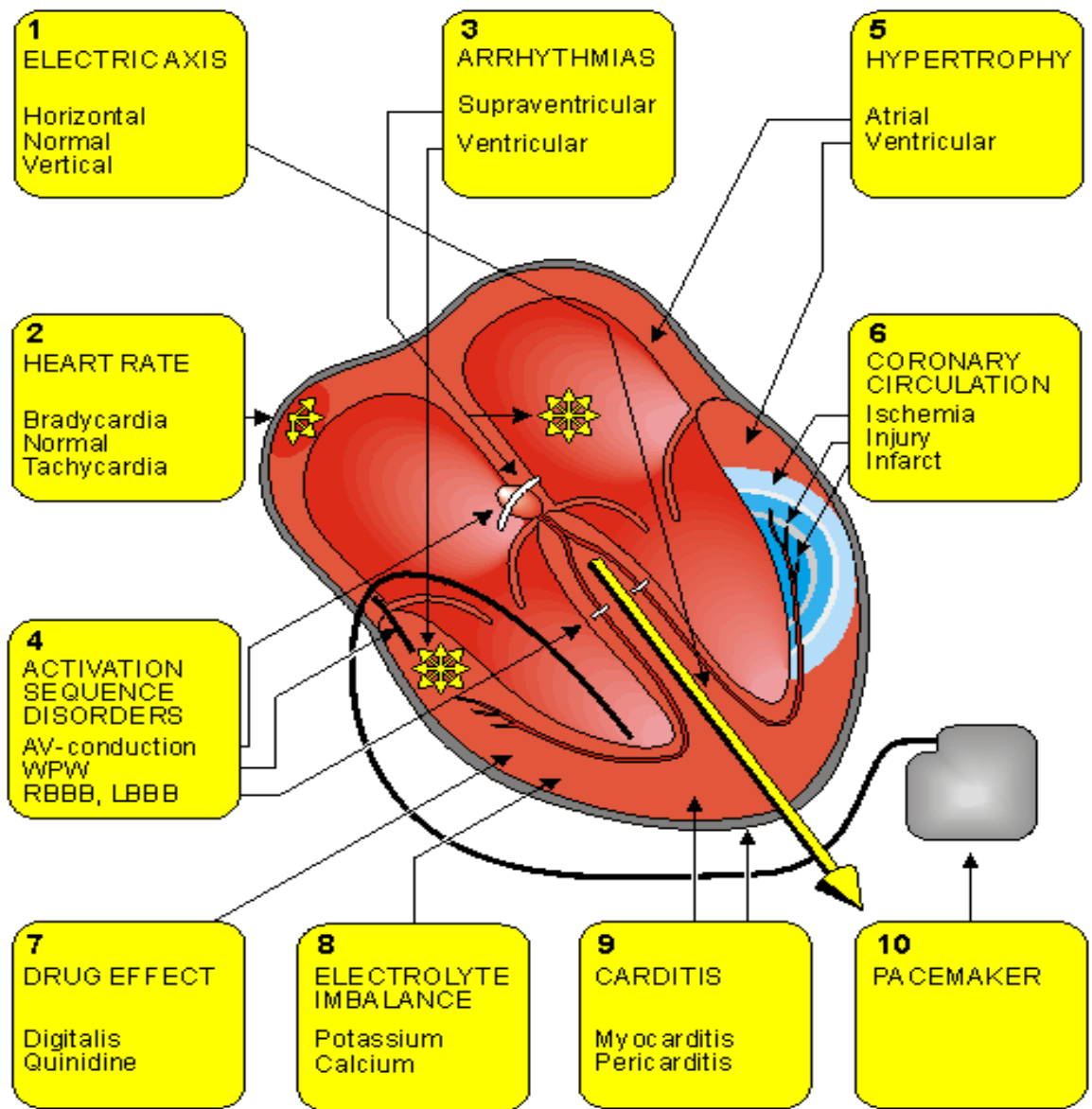


Fig. 1 Application areas of ECG diagnosis.

THE ECG LEADS

ECG leads are formed by placing electrodes at specific places on the body and amplifying and recording the electrical activity that occurs along this pathway. A vector is a force of a known magnitude and direction. The recordings may be said to display certain vectors or electrical forces traveling in the direction between the leads.

Ten electrodes are used for a 12-lead ECG. They are labeled and placed on the patient's body as follows:

Electrode label	Electrode placement
Red	On the right arm (RA), avoiding bony prominences
Yellow	In the same location that RA was placed, but on the left arm this time
Green	On the left leg (LL), avoiding bony prominences
Black	In the same location that LL was placed, but on the right leg this time

To record a routine ECG, 12 leads are used:

On the limbs: I, II, III, aVR, aVL, aVF;

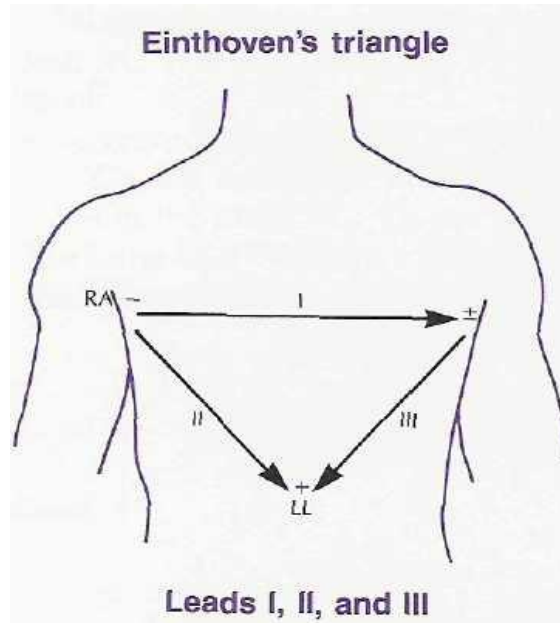
On the chest: V₁, V₂, V₃, V₄, V₅, V₆.

The first three bipolar leads used by ECG pioneer Dr. Einthoven were leads I, II, and III recording the electrical activity along the pathway from a negative electrode toward a relatively positive electrical pole.

Each lead records the same electrical impulse on the ECG but from a different position in relation to the heart. Each can be read separately, or they can be read in combination.

The limb leads show the current flow from one area of the body toward another. **Lead I** shows electrical activity from the right arm to the left arm, **lead II**

from right arm to left leg, and **lead III** from left arm to left leg. The right-leg position is not displayed as part of the flow of current through the heart, as it is used for grounding the system. In the 12-lead ECG, the leads are placed on the limbs. For continuous monitoring, these leads are positioned on the chest in a smaller



configuration.

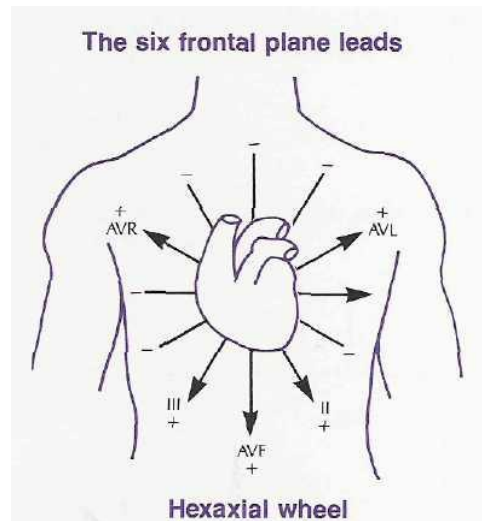
Whenever electrical activity flows from a negative pole toward a positive pole, it causes an upward deflection on the ECG tracing. The lead that will show the tallest upward deflections is the one that is parallel to the actual forces in the body. Lead II is frequently used for monitoring as it is usually parallel to the direction of the electrical activity in the heart, and shows an easily visible P wave. Illustrations in this book are taken from lead II unless otherwise labeled.

If more lead placements are used, specific areas of heart dysfunction can be identified. Therefore the positive or exploring electrode is positioned at other sites and by using combinations of other electrodes for the neutral or negative pole, unipolar lead sites are formed.

Unipolar limb leads **aVR, aVL, and aVF** are augmented limb leads. The abbreviation aVR stands for augmented vector right, an added point of reference for diagnosis. aVL and aVF represent the left-side and left-foot positions, respectively.

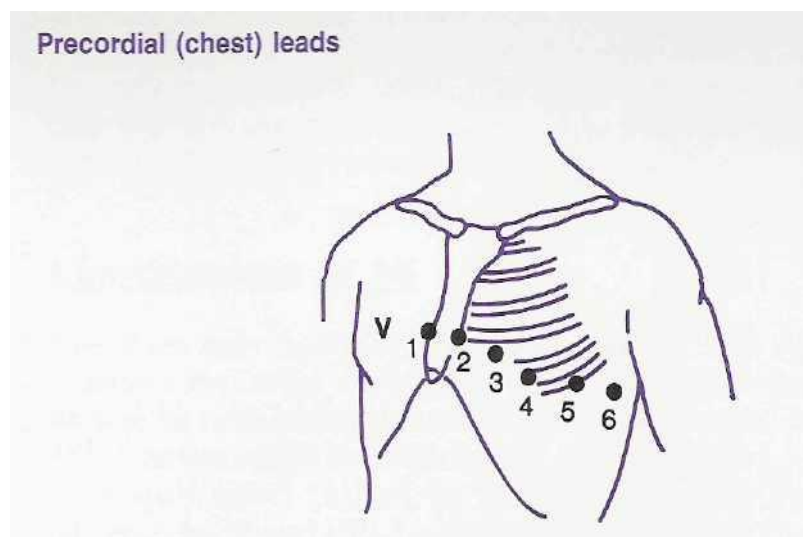
Together with leads I, II, and III, augmented limb leads aVR, aVL, and aVF form the basis of the hexaxial reference system, which is used to calculate the heart's electrical axis in the frontal plane.

In addition to the frontal plane, a horizontal plane of reference can be used for more precise location of problems.



Unipolar chest leads proposed by Wilson are more popular now. The chest electrode, which is attached to the positive pole of the electrocardiograph is only active; the electrodes leading from the limbs are united and connected to the negative terminal of the apparatus. With this connection, the total potential difference recorded from the limbs is practically zero.

The **precordial leads** provide points of reference across the chest wall as illustrated. They differentiate right-sided and left-heart events.



The electrode is placed successively at 6 positions:

V₁ - right sternal border, the 4th intercostal space;

V₂ - left sternal border, the 4th interspace;

V₃ – midway between **V₂** and **V₄** on a line joining these two points;

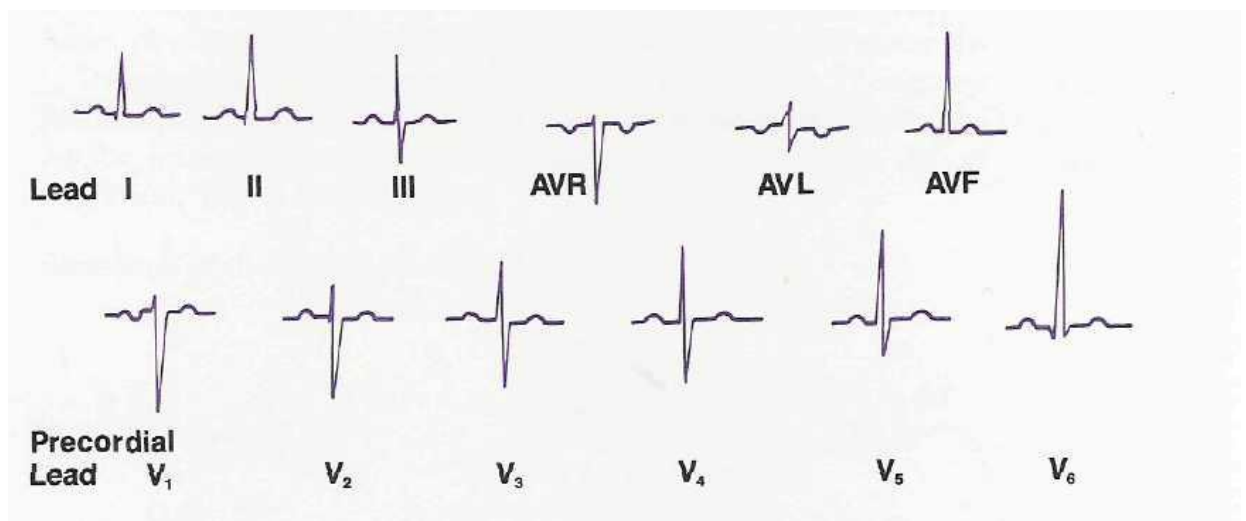
V₄ - left midclavicular line, the 5th interspace;

V₅ - left anterior axillary line, the 5th interspace;

V₆ - left midaxillary line, the 5th interspace.

Modified chest lead I is a monitoring lead that simulates precordial lead **V₁**. This lead will help to differentiate right from left bundle branch block.

The same beat can have a different configuration when seen from a different lead. These are the normal variations in the 12-lead ECG.



The most important leads to remember in relation to the anatomy of the heart are:

I, AVL	Anterior heart
II, III, AVF	Inferior heart
V₁, V₂	Right side of heart
V₃, V₄	Transition between right and left sides of heart

V₅, V₆ Left side of heart

The area of pathology shown on the ECG can be localized by analyzing tracings from different leads. For example: If an infarct shows up on leads II, III, and AVF only, it is located in the inferior aspect of the heart.

DETERMINATION OF THE ELECTRIC AXIS OF THE HEART

The hypothetical line connecting the two electrodes taking part in the formation of the electrocardiographic lead is called the axis of the lead. The axis of the three standard leads in a frontal plane make an equal sides Einthoven triangle as if moving through both the hands and the left leg used for choosing the direction of the heart electric axis and the α angle. The concept of the electric axis of the heart usually denotes the average direction of the electric activity throughout ventricular (or sometimes atrial) activation. The term mean vector is frequently used instead of "electric axis." The direction of the electric axis may also denote the instantaneous direction of the electric heart vector. This is shown in vectorcardiography as a function of time.

The normal range of the electric axis lies between $+0^\circ$ and $+90^\circ$ in the frontal plane.

The direction of the electric axis may be approximated from the 12-lead ECG by finding the lead in the frontal plane, where the QRS-complex has largest positive deflection. The direction of the electric axis is in the direction of this lead vector. The result can be checked by observing that the QRS-complex is symmetrically biphasic in the lead that is normal to the electric axis.

Deviation of the electric axis to the right is an indication of increased electric activity in the right ventricle due to increased right ventricular mass. This is usually a consequence of chronic obstructive lung disease, pulmonary emboli, certain types of congenital heart disease, or other disorders causing severe pulmonary hypertension and cor pulmonale.

Deviation of the electric axis to the left is an indication of increased electric activity in the left ventricle due to increased left ventricular mass. This is usually a consequence of hypertension, aortic stenosis, ischemic heart disease, or some intraventricular conduction defect.

The clinical meaning of the deviation of the heart's electric axis is discussed in greater detail in connection with ventricular hypertrophy.

The heart vector, a scheme arrow showing the direction of the heart moving power (the length of which characterises the quality of this power, starts in the center of the heart). To find the direction of this electric heart axis (EHA) one must find the algebra sum of R and S waves of the QRS complex in the I and III leads and mark this figure on the axis of the corresponding lead, then draw a perpendicular from every point appeared and draw a vector to the place of their crossing. This will be direction of the electric heart axis.

The EHA can be determined by the R and S waves in standard leads.

- EHA isn't inclined: $R_{II} = R_I + R_{III}$;
- EHA is inclined to the left: $R_I S_{III}$;
- EHA is inclined to the right: $S_I R_{III}$.

The angle between EHA and the first horizontal lead is called angle α (Fig. 2).

- EHA isn't inclined: $0^\circ < \alpha < +90^\circ$
- EHA is in inclined to the left: $-30^\circ < \alpha < 0^\circ$
- EHA is in inclined to the right: $+90^\circ < \alpha < +120^\circ$.

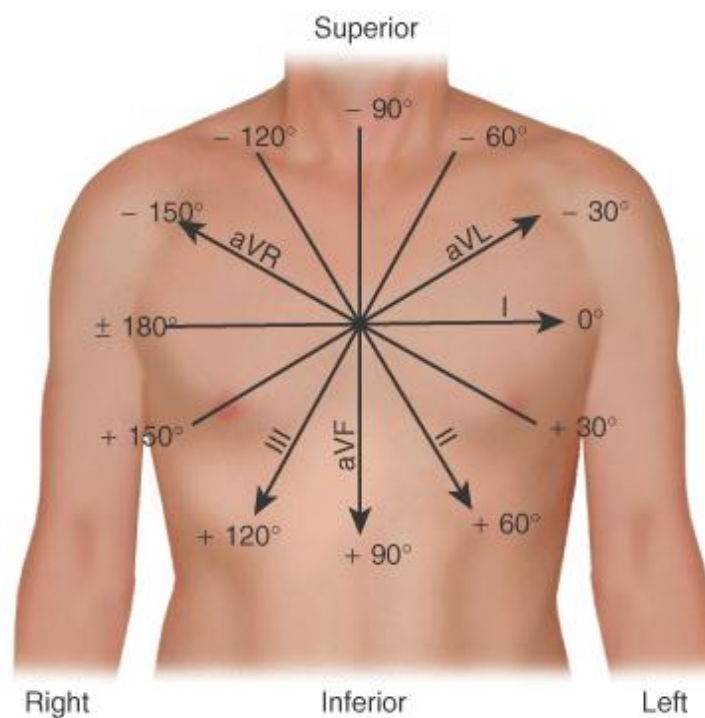


Fig. 2 Cabrera system

ATRIAL AND VENTRICULAR HYPERTROPHIES

The increase in the atrial or ventricular size is called *atrial* or *ventricular enlargement*. The increase of the atrial or ventricular wall thickness is called *atrial* or *ventricular hypertrophy*.

Right atrial hypertrophy

Right atrial hypertrophy is a consequence of right atrial overload. This may be a result of tricuspid valve disease (stenosis or insufficiency), pulmonary valve disease, or pulmonary hypertension (increased pulmonary blood pressure). The latter is most commonly a consequence of chronic obstructive pulmonary disease or pulmonary emboli.

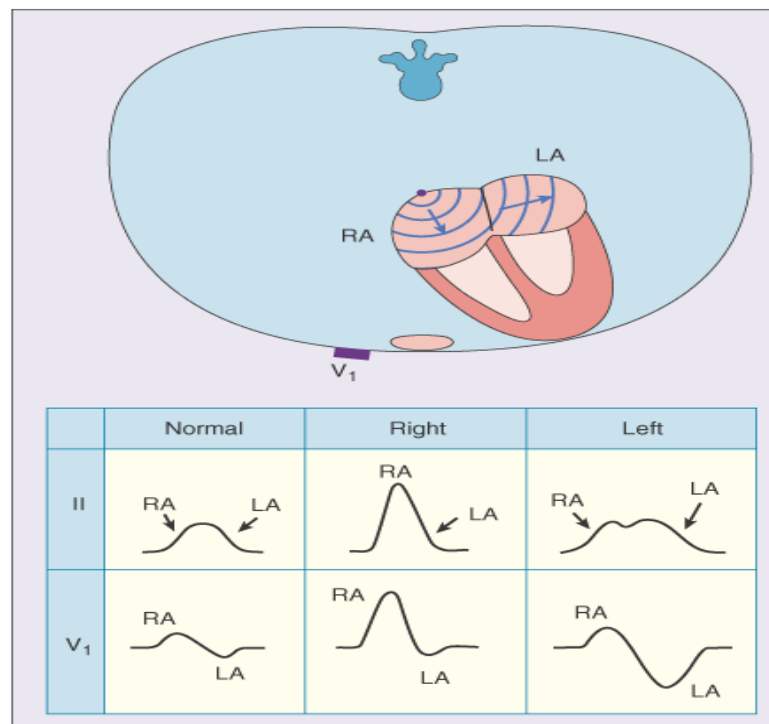
In right atrial hypertrophy the electrical force due to the enlarged right atrium is larger. This electrical force is oriented mainly in the direction of **lead II** but also in leads **aVF and III**. In all of these leads an unusually high-amplitude, peaked P-wave more than 2.5 mm is seen. This typical P-wave form is called the *pulmonale P-wave*.

Left atrial hypertrophy

Left atrial hypertrophy is a consequence of left atrial overload. This may be a result of mitral valve disease (stenosis or insufficiency), aortic valve disease, or hypertension in the systemic circulation.

In left atrial hypertrophy the electrical impulse due to the enlarged left atrium is strengthened. This electrical impulse is directed mainly along lead I or opposite to the direction of lead V₁. Because the atrial activation starts from the right atrium, the aforementioned left atrial activation is seen later, and therefore, the P-wave includes two phases. In lead I these phases have the same polarities and in lead V₁ the opposite polarities. This typical P-wave form is called the *mitral P-wave*. The specific diagnostic criterion for left atrial hypertrophy is the terminal

portion of the P-wave in V_1 , having a duration ≥ 0.04 s and negative amplitude ≥ 0.1 mV. The P wave duration is more than 0.1 s.



VENTRICULAR HYPERTROPHY

Left ventricular hypertrophy.

Left ventricular hypertrophy (LVH) is a consequence of left ventricular overload. It arises from mitral valve disease, aortic valve disease, or systemic hypertension. Left ventricular hypertrophy may also be a consequence of obstructive hypertrophic cardiomyopathy, which is a sickness of the cardiac muscle cells.

Left ventricular hypertrophy increases the ventricular electric forces directed to the left ventricle - that is, to the left and posteriorly. Evidence of this is seen in lead I as a tall R-wave and in lead III as a tall S-wave. Also a tall S-wave is seen in precordial leads V_1 and V_2 and a tall R-wave in leads V_5 and V_6 .

There are several sets of criteria used to diagnose LVH via electrocardiography:

■ **The Sokolow-Lyon index:**

S in $V_1 + R$ in V_5 or V_6 (whichever is larger) ≥ 35 mm

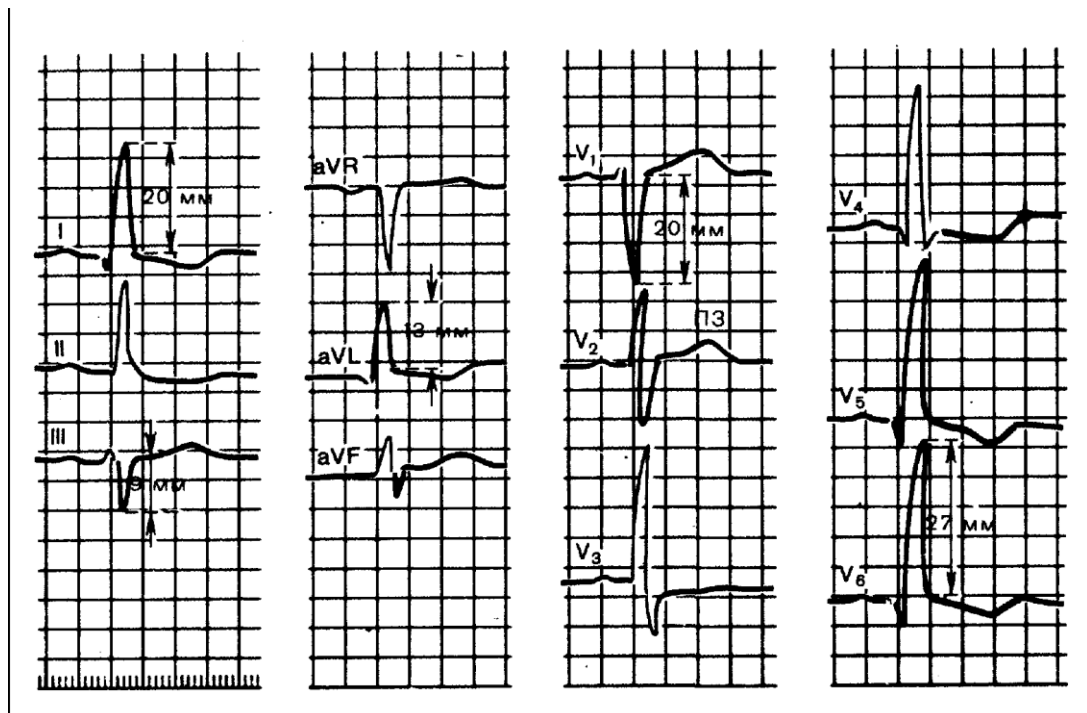
R in $aVL \geq 11$ mm

■ **The Cornell criteria** (sum of the R wave in lead aVL and the S wave in lead V_3).

S in $V_3 + R$ in $aVL > 28$ mm (men)

S in $V_3 + R$ in $aVL > 20$ mm (women)

1. The position of the electrical heart axis is inclined to the left: $R_I S_{III}$;
2. The tall R wave in I, aVL and V_5, V_6 ;
3. The deep S wave in III, aVF , V_1, V_2 ;
4. S - T depression and T wave inversion in leads I, aVL and V_5, V_6 .

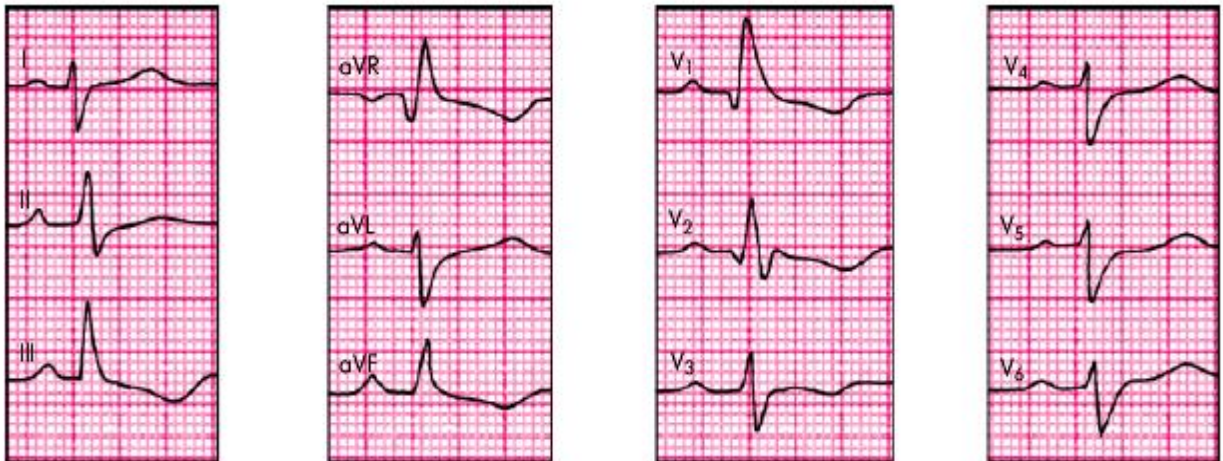

Right-ventricular hypertrophy.

Right ventricular hypertrophy is a consequence of right ventricular overload. This is caused by pulmonary valve stenosis, tricuspid insufficiency, or pulmonary

hypertension. Also many congenital cardiac abnormalities, such as a ventricular septal defect, may cause right ventricular overload.

Right ventricular hypertrophy increases the ventricular electrical forces directed to the right ventricle - that is, to the right and front.



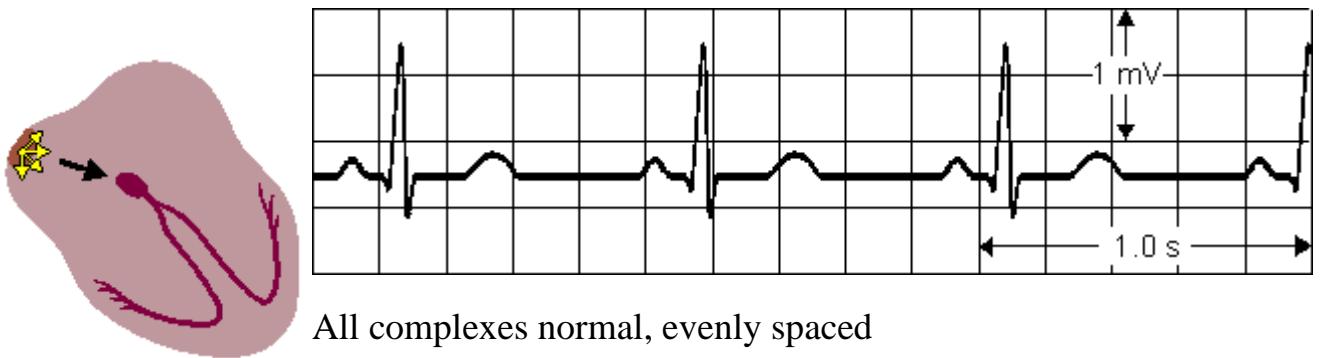
1. The position of the electrical heart axis is inclined to the right: $S_I R_{III}$.
2. The tall R wave in II, III, AVF and V_1, V_2 ;
3. The deep S wave in I, AVL, V_5, V_6 ;
4. S-T depression and T wave inversion in leads II, III, AVF and V_1, V_2 .

CARDIAC RHYTHM DIAGNOSIS

NORMAL SINUS RHYTHM

Normal sinus rhythm is the rhythm of a healthy normal heart, where the sinus node triggers the cardiac activation. This is easily diagnosed by noting that the three deflections, P-QRS-T, follow in this order and are differentiable. The sinus rhythm is normal if its frequency is between 60 and 100/min.

Impulses originate at S-A node at normal rate



All complexes normal, evenly spaced

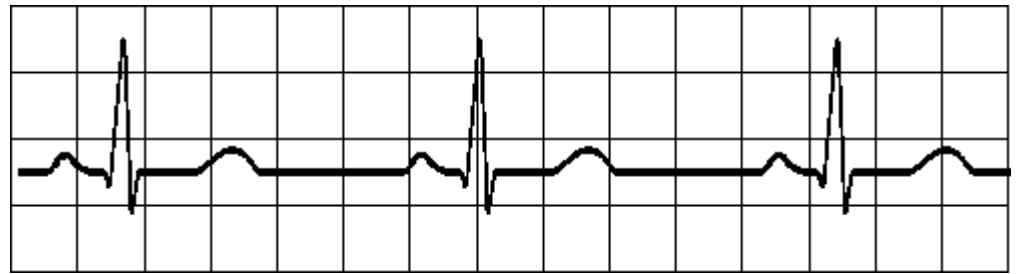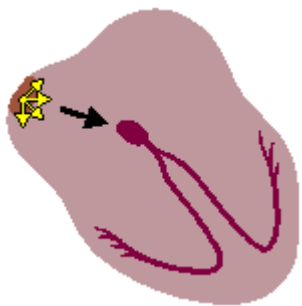
Rate 60 - 100/min

SINUS BRADYCARDIA

A sinus rhythm of less than 60/min is called sinus bradycardia. This may be a consequence of increased vagal or parasympathetic tone. Sinus bradycardia is seen as an expected manifestation in well-trained athletes. It may occur in patients on digitalis, propranolol, morphine, and pressor amines for treatment of low blood pressure. A significant slowing may cause a decrease in cardiac output that can lead to cerebral or coronary insufficiency. An additional hazard is that bradycardia may permit ectopic pacemaker foci to take over, causing serious arrhythmias. Sinus bradycardia may be beneficial in a person at rest but if seen during stress, it could indicate inability of the heart to compensate.

The decision to treat sinus bradycardia is based on an evaluation of the patient's clinical picture. If drug therapy is indicated, IV atropine is used to inhibit the vagus (heart-slowng) nerve, thus speeding up the heart rate. If the patient does not respond, use of an artificial pacemaker may be necessary.

Impulses originate at S-A node at slow rate



All complexes normal, evenly spaced

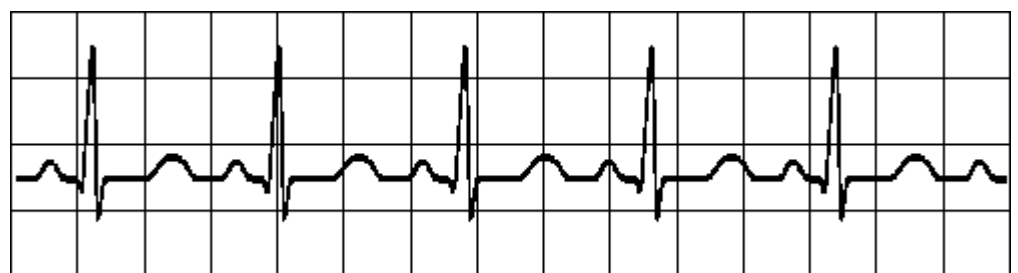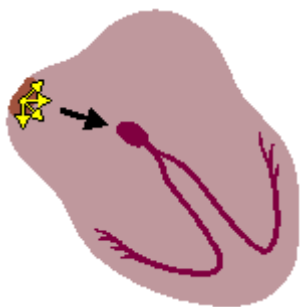
Rate < 60 - 100/min

SINUS TACHYCARDIA

A sinus rhythm of higher than 100/min is called sinus tachycardia. Common causes are physical activity, anxiety, and fever. An increased rate may also be a compensatory response to decreased cardiac output.

Complications such as congestive heart failure, pulmonary embolism, cardiogenic shock, or bleeding may show sinus tachycardia as an early symptom.

Impulses originate at S-A node at rapid rate



All complexes normal, evenly spaced

Rate > 100/min

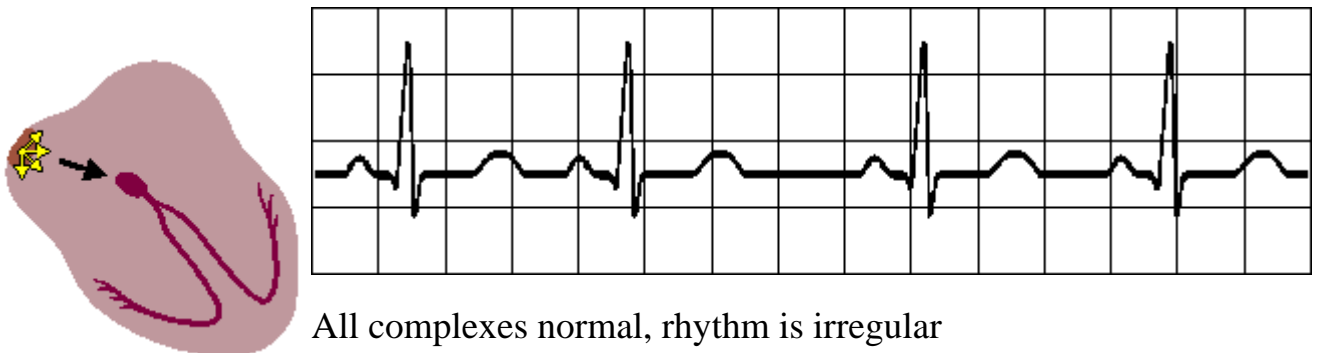
SINUS ARRHYTHMIA

If the sinus rhythm is irregular such that the longest PP- or RR-interval exceeds the shortest interval by 0.16 s, the situation is called sinus arrhythmia. This

situation is very common in all age groups. This arrhythmia is so common in young people that it is not considered a heart disease. One origin for the sinus arrhythmia may be the vagus nerve which mediates respiration as well as heart rhythm. The nerve is active during respiration and, through its effect on the sinus node, causes an increase in heart rate during inspiration and a decrease during expiration. The effect is particularly pronounced in children.

Note, that in all of the preceding rhythms the length of the cardiac activation cycle (the P-QRS-T-waves together) is less than directly proportional to the PP-time. The main time interval change is between the T-wave and the next P-wave. This is easy to understand since the pulse rate of the sinus node is controlled mainly by factors external to the heart while the cardiac conduction velocity is controlled by conditions internal to the heart.

Impulses originate at S-A node at rapid rate



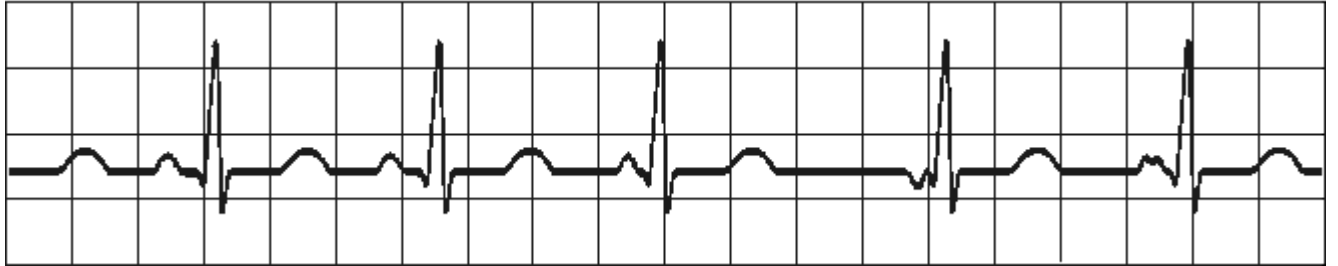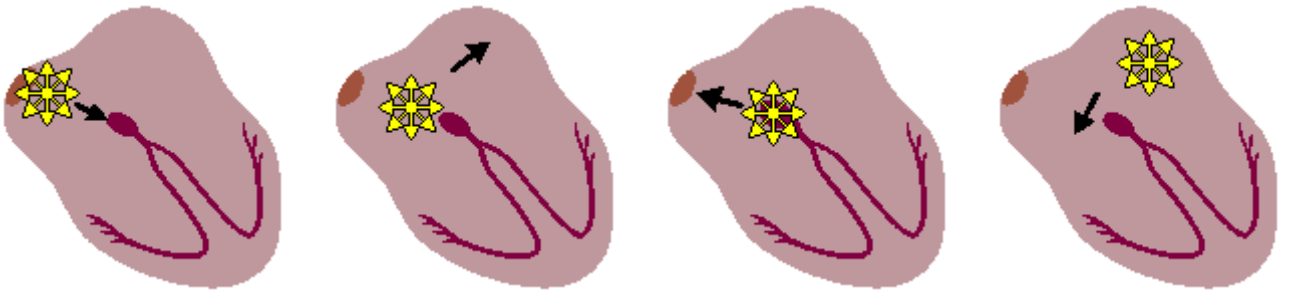
All complexes normal, rhythm is irregular

Longest R-R interval exceeds shortest > 0.16 s

WANDERING PACEMAKER

The origin of the atrial contraction may also vary or *wander*. Consequently, the P-waves will vary in polarity, and the PQ-interval will also vary.

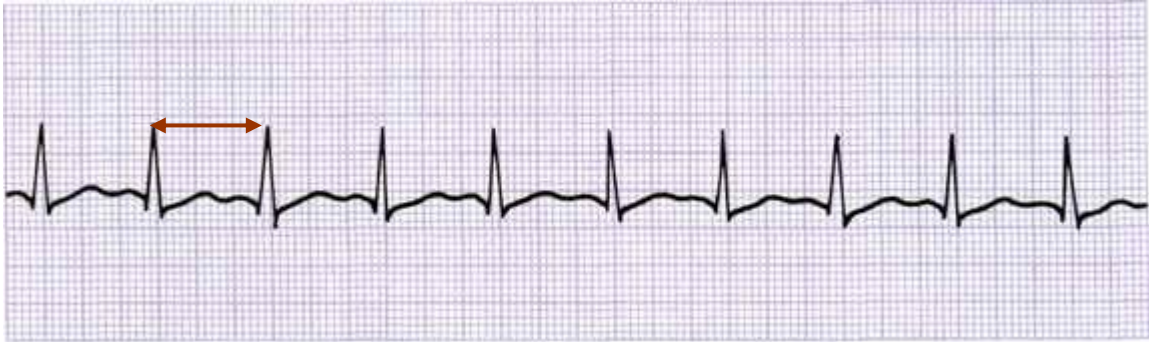Impulses originate from varying points in atria



Variation in P-wave contour, P-R and P-P interval and therefore in R-R intervals

DENERMINATION THE HEART RATE

Regularity may be determined using calipers or any device that can be marked to show a fixed interval for comparison.



R-R interval - **3 large blocks**

Alternative methods of **determining the heart rate (HR)**. To that end, duration of one cardiac cycle (the R-R interval) and the number of such cycles in one-minute length should be determined.

$$\text{HR} = \frac{60}{\text{R - R}}$$

For example, if one cycle lasts 0.3 second, there will be 200 such cycles in a minute ($60 : 0.3 = 200$). If the heart rhythm is irregular, the length of five or ten R-R intervals is determined, the mean R-R interval found, and the cardiac rate is finally determined as for regular cardiac rhythm. Lengths of the maximum and minimum R-R intervals are given in parentheses.

Summary of normal findings

ECG characteristic	Normal finding
Voltage	The amplitude of the highest R wave more than 5 mm in standard leads
Rhythm	Regular (distance between QRS complexes varies by no more than three small squares)
Rate	60-90 beats per minute
P wave	Present and upright (in leads I, II, AVF, V ₂ - V ₆) All shaped alike
PR interval	P wave precedes QRS 0.12 - 0.20 sec. Time interval is the same for all beats
QRS complex	Present All shaped alike 0.10 sec.
T wave	Present and upright (in leads I, II, AVF, V ₂ - V ₆) T _I > T _{III} , and T _{V6} > T _{V1} leads

INTERPRETATION of the ECG

1. Determination of the cardiac rhythm regularity.
2. Calculation of the heart rate.
3. Measurement of the ECG amplitude (voltage).
4. Determination of the cardiac rhythm pacemaker site.
5. Estimation of the conductivity.
6. Determination of the electrical axis of the heart.
7. Measurement of the duration and amplitude of the ECG waves and intervals.

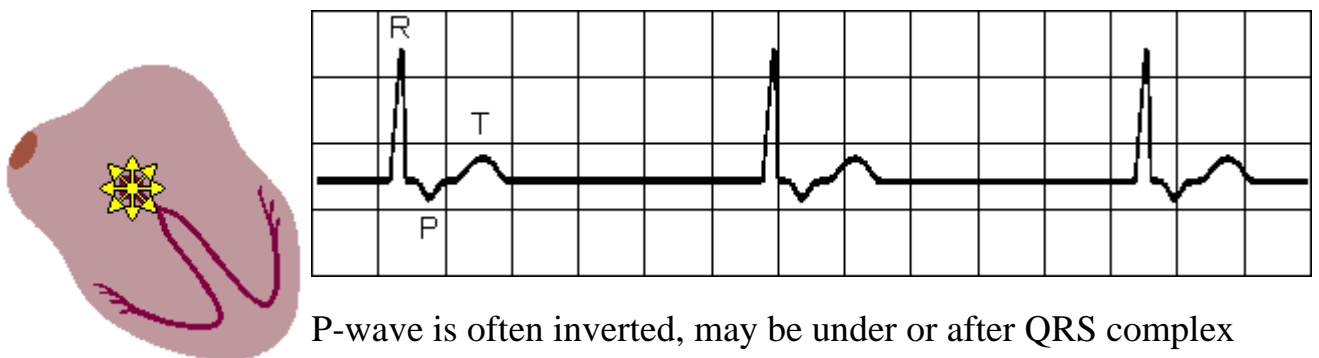
ECG CONCLUSION. In the ECG conclusion it is necessary to note following:

- The cardiac rhythm pacemaker (sinus or nonsinus rhythm);
- Regularity of the cardiac rhythm (regular or irregular);
- The heart rate;
- Position of the electrical axis of the heart; Presence of the four ECG syndromes: arrhythmias, abnormalities of conductivity, atrial and ventricular hypertrophy, myocardial damage (ischemia, injury, necrosis, scar).

ECTOPIC RHYTHMS

Junctional (nodal) rhythms. If the heart rate is slow (40-55/min), the QRS-complex is normal, the P-waves are possibly not seen, then the origin of the cardiac rhythm is in the AV node. Because the origin is in the junction between atria and ventricles, this is called *junctional rhythm*. Therefore, the activation of the atria occurs retrograde (i.e., in the opposite direction). Depending on whether the AV-nodal impulse reaches the atria before, simultaneously, or after the ventricles, an opposite polarity P-wave will be produced before, during, or after the QRS-complex, respectively. In the second case the P-wave will be superimposed on the QRS-complex and will not be seen.

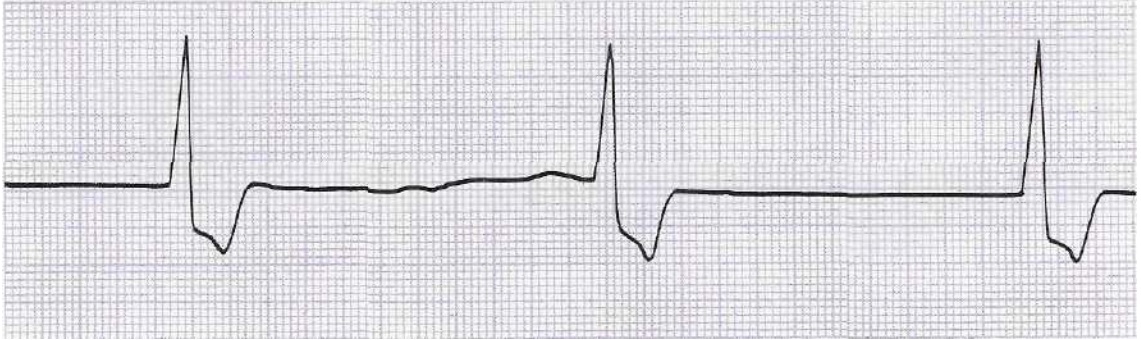
Impulses originate at AV node with retrograde and antegrade direction



P-wave is often inverted, may be under or after QRS complex
Heart rate is slow

Idioventricular rhythm appears when all complexes originate from the ventricles (wide, distorted, identical QRSs). This occurs when there is no adequate atrial pacemaker, or when the impulse is blocked at the AV node. The rate corresponds to that of ventricular pacemakers (usually below 40). The patient with this condition requires close observation and may be treated with stimulants and/or a pacemaker depending on the underlying pathology. When the ventricular function is due to clinical conditions that are not reversible, this is a terminal event. The complexes will gradually deteriorate to a straight line.

ECG for idioventricular rhythm



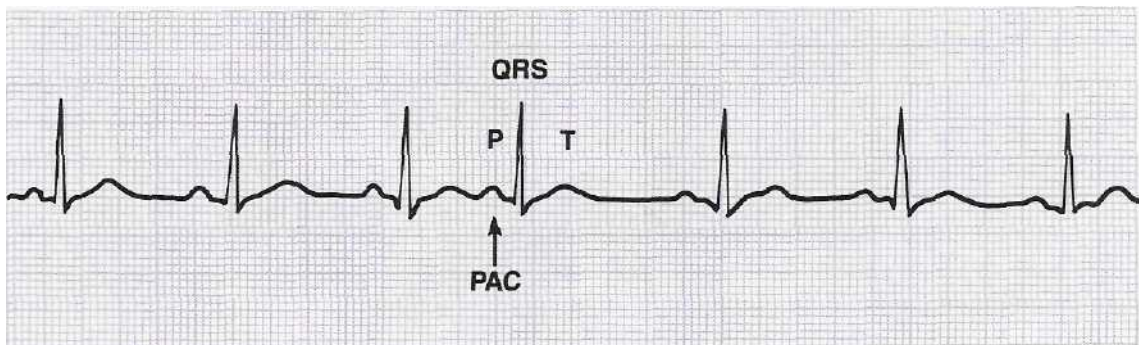
PREMATURE CONTRACTIONS OR ECTOPIC BEATS

Portions of atrial tissue may become excitable and initiate impulses. These ectopic foci will control the heartbeat if they occur at a rate faster than impulses from the SA node.

Premature atrial contraction (PAC) is a beat initiated by an ectopic atrial focus that appears early in the cycle (before the next expected sinus beat). Since the impulse arises from a site other than the sinus node, **the shape of the P wave and the length of the PR interval may be different**. The premature P wave is sometimes difficult to distinguish when it is superimposed on the preceding T wave.

The PAC is usually conducted through the ventricular pathway in the normal manner not affecting the shape of the QRS. A pause will follow the beat, and the SA node will start a new cycle of sinus beats.

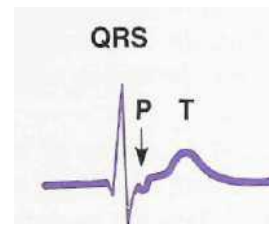
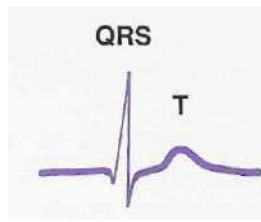
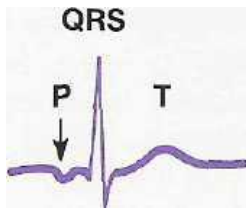
ECG for PAC



A junctional premature contraction (JPC) is an ectopic beat that arises from tissue in the junctional area and appears before the next expected sinus beat. **The P will be inverted before or after the QRS, or it may be completely hidden in the QRS.**

The inverted P will always be very close to the QRS. A JPC can be distinguished from a PAC by the appearance of the P wave. Infrequent JPCs do not require treatment. Frequent JPCs indicate tissue irritability and may be treated with a myocardial depressant.

JPC

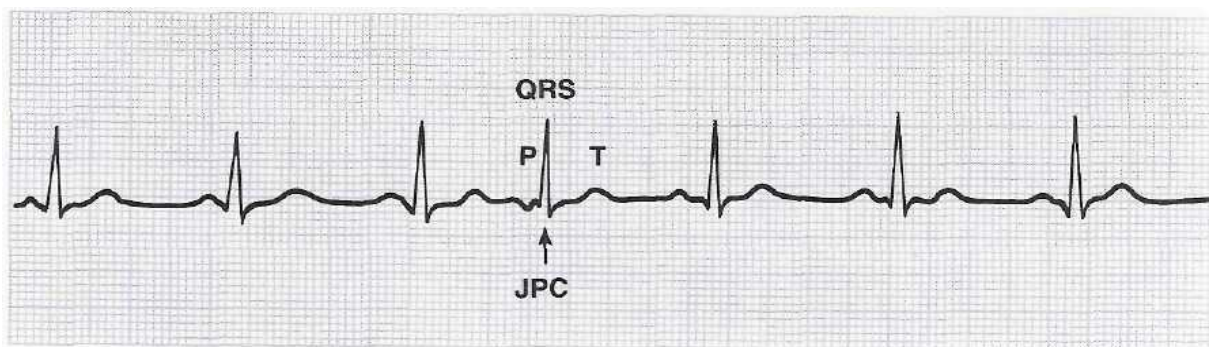


INVERTED P BEFORE

HIDDEN IN QRS

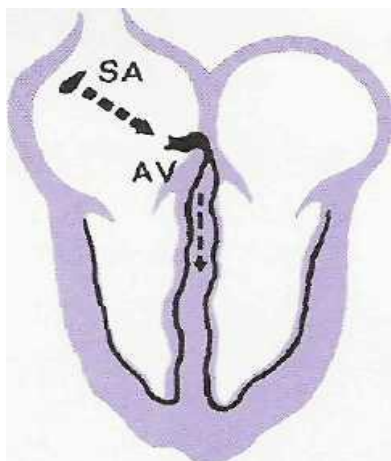
INVERTED P AFTER QRS

Junctional premature contraction

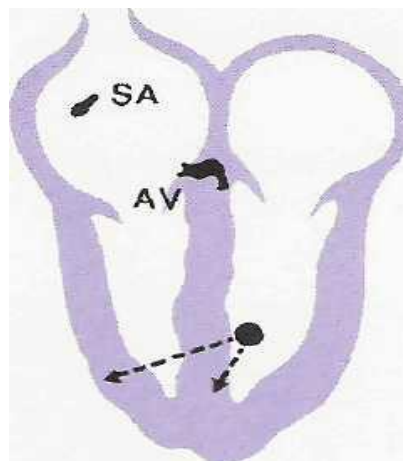


Premature ventricular contractions (PVCs) or ventricular premature beats (VPBs) occur in most myocardial infarction patients and are the most common and easily recognized rhythm disturbances seen on the ECG. They are also seen in normal persons, and may be caused by smoking, coffee, and alcohol. When pathological, they are seen most often in patients with ischemic or arteriosclerotic heart diseases.

Normal pathway



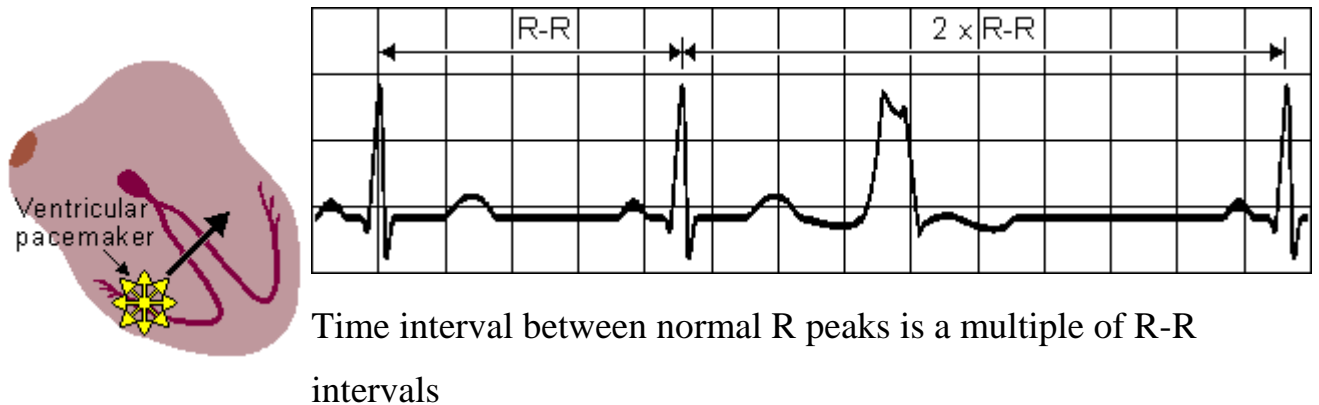
PVC pathways



As the name denotes, PVCs originate in the ventricles below the AV node. If the origin is in the ventricular muscle, the QRS-complex has a very abnormal form and lasts longer than 0.1 s. Usually the P-wave is not associated with it.

PREMATURE VENTRICULAR CONTRACTION

A single impulse originates at right ventricle



Time interval between normal R peaks is a multiple of R-R intervals

ECG for PVCs. Notice that the PVCs come early in the cycle (premature) and are wider than the normal beat. PVCs can be identified because they:

1. Usually occur early in the cycle.
2. Are not usually preceded by a P wave.
3. Have a wide and distorted QRS.
4. Have a large looping ST segment opposite in direction to that of the QRS.
5. Are usually followed by a full compensatory pause. (The interval between the R waves before and after the PVC is twice that of the normal R-R interval.)

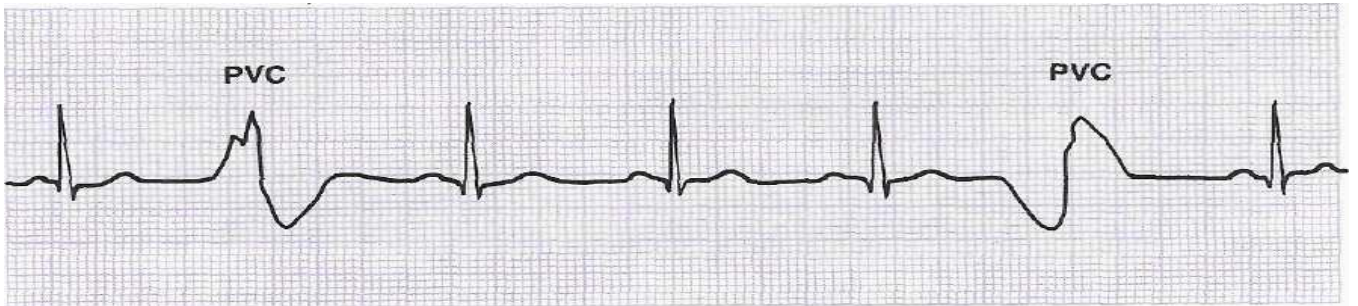
Left ventricular PVC is seen in the ECG *deep S-wave in leads I, aVL, V₄, V₅, V₆* and *in leads III, aVF, V₁, V₂ high amplitude R-wave.*

Right ventricular PVC is seen in the ECG as *high amplitude R-wave in leads I, aVL, V₄, V₅, V₆* and *in leads III, aVF, V₁, V₂ deep S-wave.*

Terms used to describe PVCs

Unifocal PVCs. Those that originate from the same site and therefore have the same configuration.

Multifocal PVCs. Those that originate from different sites and have different shapes.



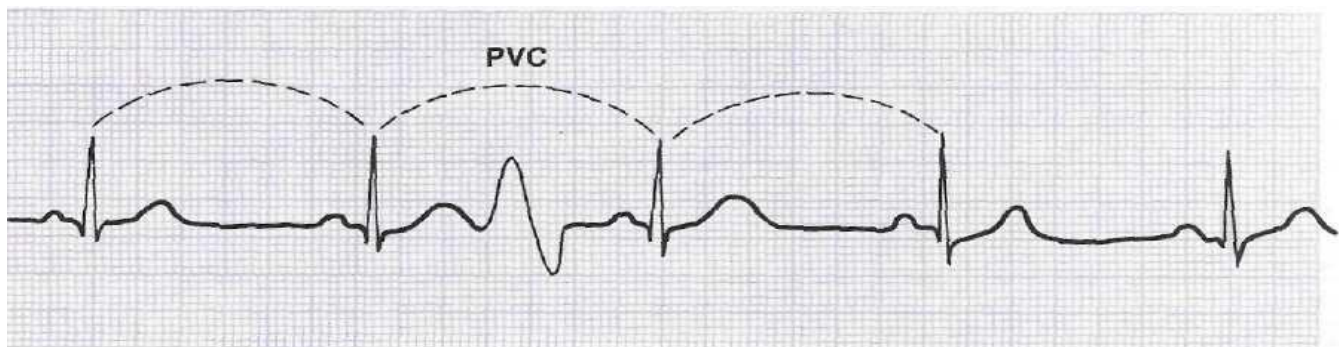
ECG for multifocal PVCs

Bigeminy. Paired or coupled rhythm; a repeating pattern of two beats, with PVCs and normal beats alternating.

Trigeminy. Rhythm with a repeating pattern of three beats; the ratio of PVCs to normal beats is 2:1 or 1:2.

Interpolated PVCs. Those that fall between two normal beats without interrupting the rhythm. These PVCs are not followed by compensatory pauses.

ECG for interpolated PVC



For the patient with an infarct, PVCs are usually given vigorous treatment because they can precipitate ventricular fibrillation by occurring on a T wave. They are especially dangerous when they:

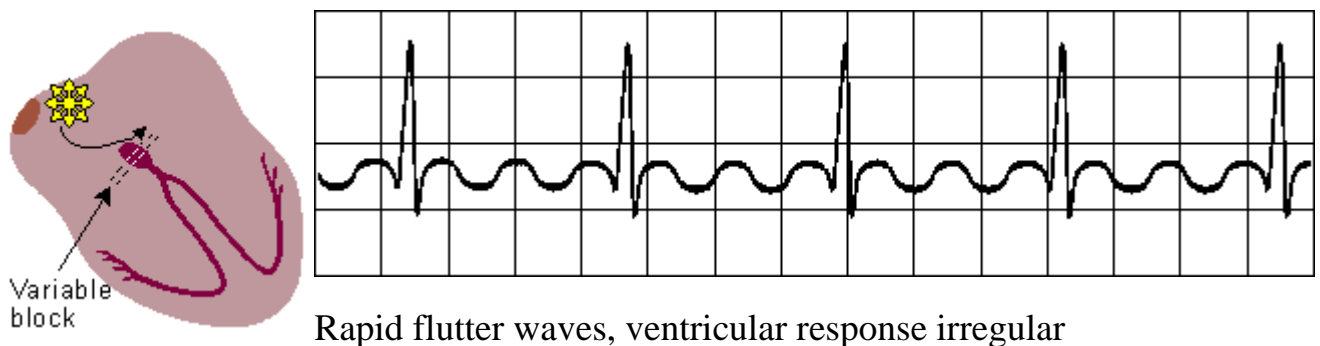
1. Occur more frequently than one in 10 beats.
2. Occur in groups of two or three.
3. Are multifocal: several ventricular sites are irritable.

Occur on or near the T wave. At this time (the vulnerable period) in the cycle, the conduction tissue is partially repolarized and may respond in an erratic manner. Some cells respond immediately and others later, causing intermittent depolarization and triggering ventricular fibrillation.

ATRIAL FLUTTER AND FIBRILLATION

When the heart rate is sufficiently elevated so that the isoelectric interval between the end of T and beginning of P disappears, the arrhythmia is called **atrial flutter**. The origin is also believed to involve a reentrant atrial pathway. The flutter ("F") waves take on a saw-toothed appearance because they are coming from a focus other than the sinus node at a very rapid rate. The frequency of these fluctuations is between 220 and 300/min. The AV-node and, thereafter, the ventricles are generally activated by every second or every third atrial impulse (2:1 or 3:1 heart block). The ventricular response may be **regular or irregular**.

Impulses travel in circular course in atria

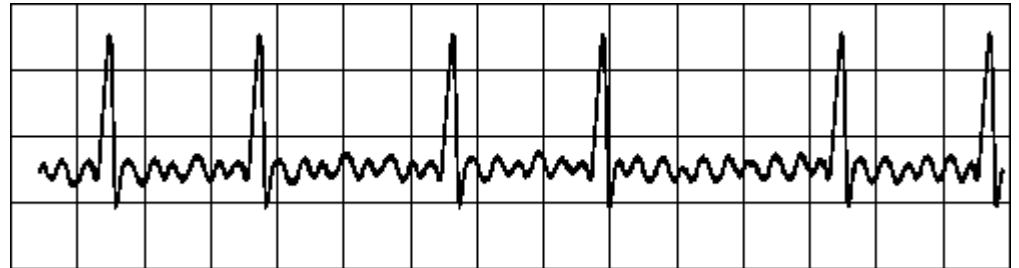
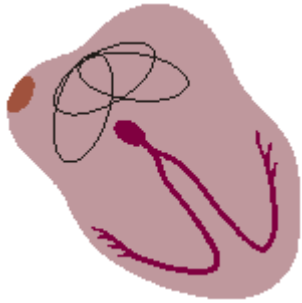


Atrial fibrillation is a very fast atrial rate arising from many ectopic foci. There is an irregular ventricular response, normal P waves are replaced by irregular rapid waves, and the total atrial configuration may resemble a wavy baseline or almost straight line.

These waves (often called fibrillatory or "f" waves) assume different shapes because different parts of the atrial tissue are depolarized in a variable, uncoordinated way. The activation in the atria may also be fully irregular and chaotic, producing irregular fluctuations in the baseline. A consequence is that the ventricular rate is rapid and irregular, though the QRS complex is usually normal. Atrial fibrillation

occurs as a consequence of rheumatic disease, atherosclerotic disease, hyperthyroidism, and pericarditis. (It may also occur in healthy subjects as a result of strong sympathetic activation.)

Impulses have chaotic, random pathways in atria



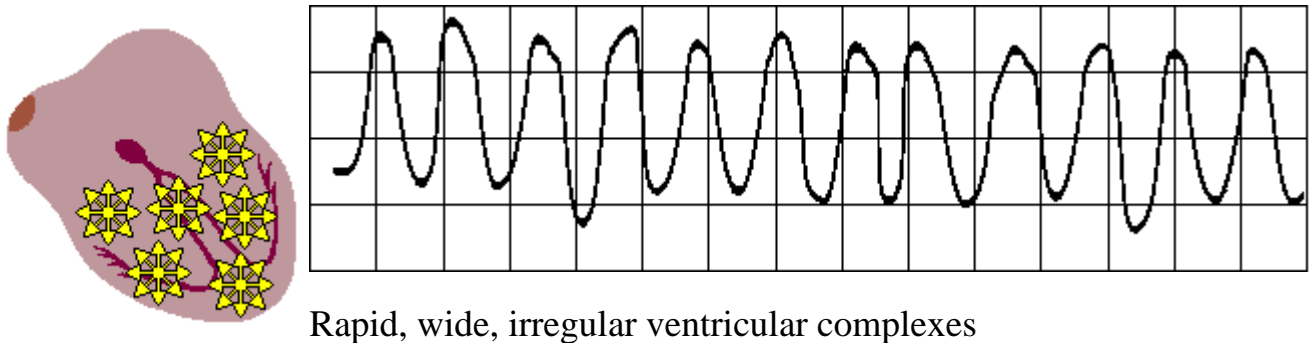
Baseline irregular, ventricular response irregular

VENTRICULAR FIBRILLATION

When ventricular depolarization occurs chaotically, the situation is called ventricular fibrillation. This is reflected in the ECG, which demonstrates coarse irregular undulations without QRS-complexes. The cause of fibrillation is the establishment of multiple re-entry loops usually involving diseased heart muscle. In this arrhythmia the contraction of the ventricular muscle is also irregular and is ineffective at pumping blood. The lack of blood circulation leads to almost immediate loss of consciousness and death within minutes. The ventricular fibrillation may be stopped with an external defibrillator pulse and appropriate medication.

VENTRICULAR FIBRILLATION

Chaotic ventricular depolarization



Rapid, wide, irregular ventricular complexes

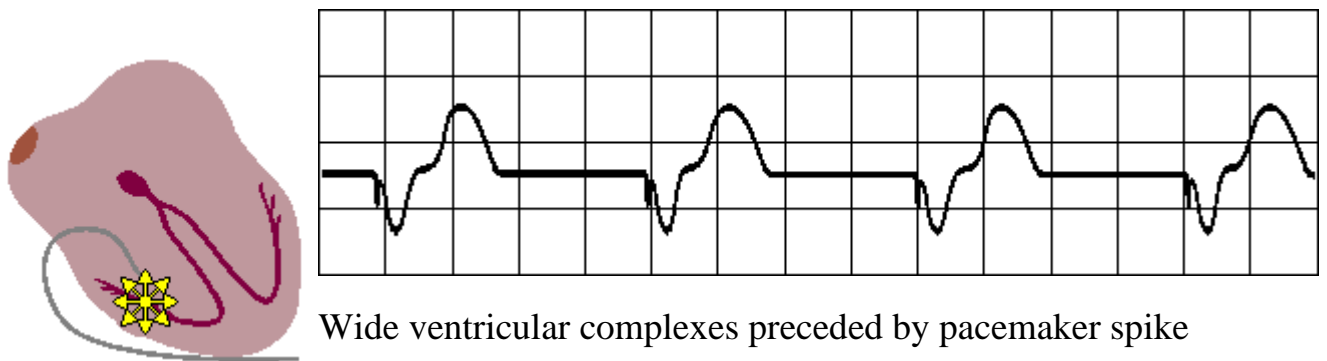
Treatment of ventricular fibrillation. If the patient is unresponsive and pulseless, call for help and begin cardiopulmonary resuscitation (CPR). At the onset of witnessed fibrillation, a precordial thump may be effective. If not, continue CPR and defibrillate as soon as possible starting with 200 joules. Defibrillation depolarizes all of the myocardial cells simultaneously and allows the SA node to resume normal conduction. Be sure the synchronizer, which is used only for elective cardioversion, is turned off during defibrillation.

Good oxygenation of the patient with intubation and/or assisted respiration is vital to successful response and correction of acidosis. The use of sodium bicarbonate should be guided by blood gas results.

PACER RHYTHM

A ventricular rhythm originating from a cardiac pacemaker is associated with wide QRS-complexes because the pacing electrode is (usually) located in the right ventricle and activation does not involve the conduction system. In pacer rhythm the ventricular contraction is usually preceded by a clearly visible pacer impulse spike. The pacer rhythm is usually set to 72/min

Impulses originate at transvenous pacemaker



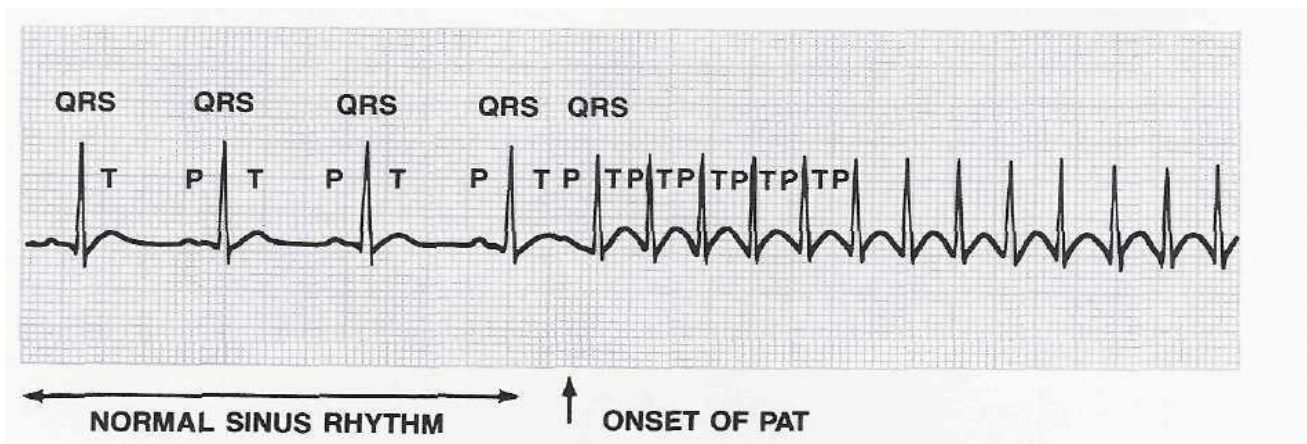
Wide ventricular complexes preceded by pacemaker spike

Rate is the pacer rhythm

PAROXYSMAL TACHYCARDIA

Paroxysmal atrial tachycardia (PAT) is an abrupt episode of tachycardia with the heart rate usually between 140 and 250 beats per minute, averaging about 170. The pacemaker site is an ectopic atrial focus. As with a PAC, the P wave may be abnormally shaped, or not seen because it is buried in the preceding T wave. The QRS appears normal. PAT may be seen in young adults with normal hearts or in individuals with organic disease. The patient frequently complains of a sudden pounding or fluttering in the chest associated with weakness or breathlessness.

ECG for PAT



The fast rate stresses the heart and increases its need for oxygen. Tachycardia may also diminish cardiac output because of shortened ventricular filling time. The heart is beating so rapidly that the ventricle does not have time to fill completely. Therefore, each beat pumps out less blood. In a relatively asymptomatic and stable patient, sedation and calming measures may be helpful. If PAT persists, the usual treatment is stimulation of the vagus nerve, which slows the heart rate. The physician may accomplish this by carotid sinus massage. Since this can produce dangerous slowing or cardiac arrest, the patient should be monitored, resuscitation equipment should be readily available and an IV line established.

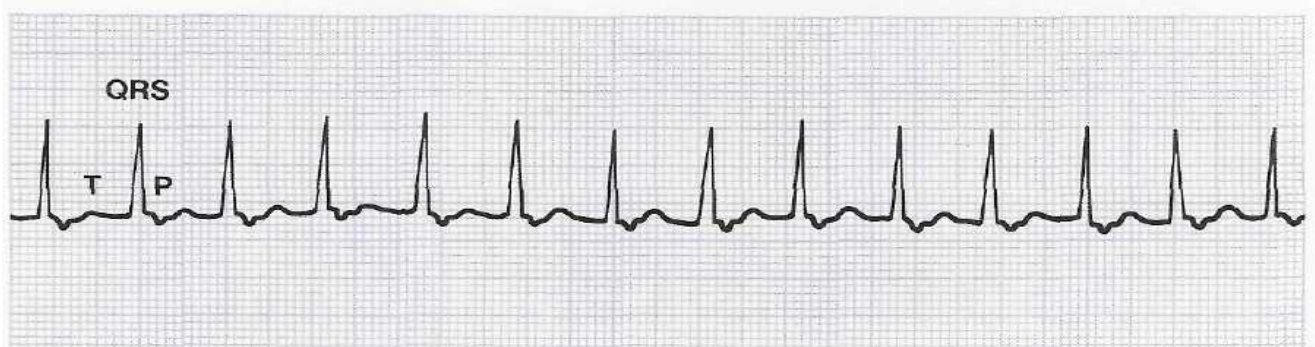
Other measures that stimulate the vagus nerve include: vomiting, stimulating the anal sphincter with a rectal thermometer or tube, and applying pressure to the eyeball. These measures are not suggested as therapy but explain some cardiac responses to such activities. A cough or Valsalva maneuver will increase intrathoracic pressure, decrease venous return, raise the blood pressure, and possibly slow the pulse. A Valsalva maneuver consists of tightening abdominal muscles while holding the breath. This is similar to the activity of bowel elimination and causes indirect vagal stimulation.

When the heart continues to beat rapidly for a period of time, or if the patient becomes symptomatic, a synchronized electrical shock (cardioversion) can be used for immediate conversion.

Junctional tachycardia is a junctional rhythm with a rate of 100 – 180 beats per minute. This arrhythmia may be difficult to distinguish from sinus or atrial tachycardia. Whenever the origin of the tachycardia cannot be determined, and the QRS complex is of normal configuration, the term **supraventricular tachycardia** is used (often called SVT).

As with other fast-rate arrhythmias, this inefficient rhythm puts stress on the heart and may cause angina, congestive heart failure, or other dangerous conditions. Treatment would be similar to that used for atrial tachycardias. Digitalis toxicity may be a possible cause.

Junctional tachycardia

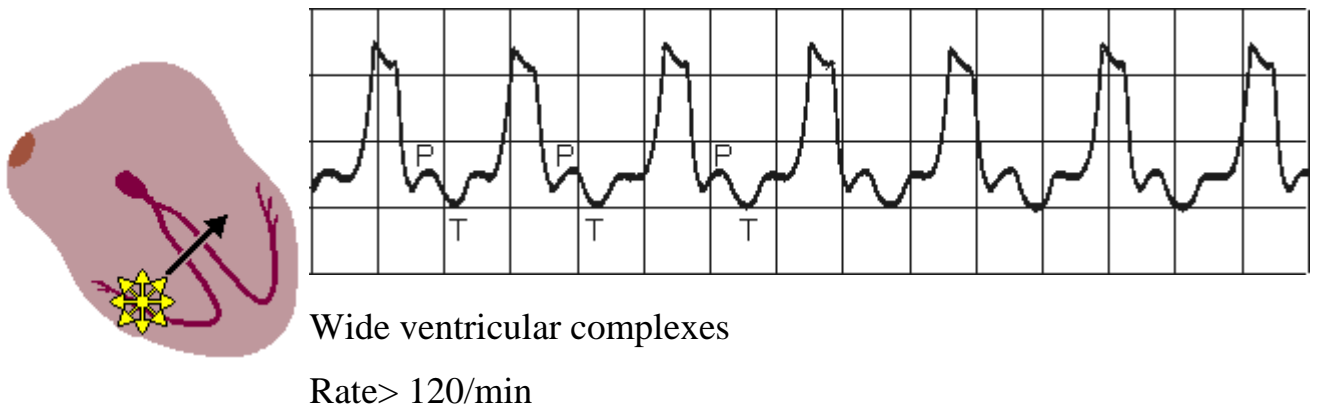


Ventricular tachycardia. This dreaded complication of a myocardial infarction may be defined as a series of multiple (three or more), consecutive PVCs occurring at a rate usually between 150 and 200 per minute. Ventricular tachycardia is very dangerous because it leads to reduced cardiac output and, many times, to ventricular fibrillation.

A rhythm of ventricular origin may also be a consequence of a slower conduction in ischemic ventricular muscle that leads to circular activation (re-entry). The result is activation of the ventricular muscle at a high rate (over 120/min), causing rapid, bizarre, and wide QRS-complexes; the arrhythmia is called ventricular tachycardia. As noted, ventricular tachycardia is often a consequence of ischemia and myocardial infarction.

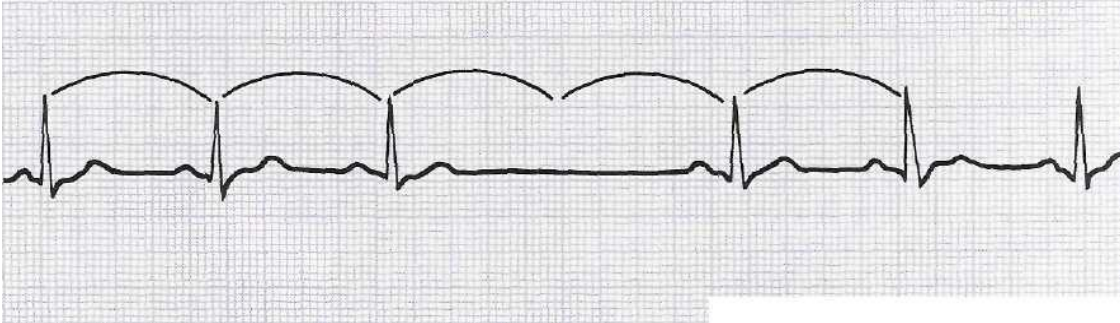
VENTRICULAR TACHYCARDIA

Impulse originate at ventricular pacemaker



BLOCKS

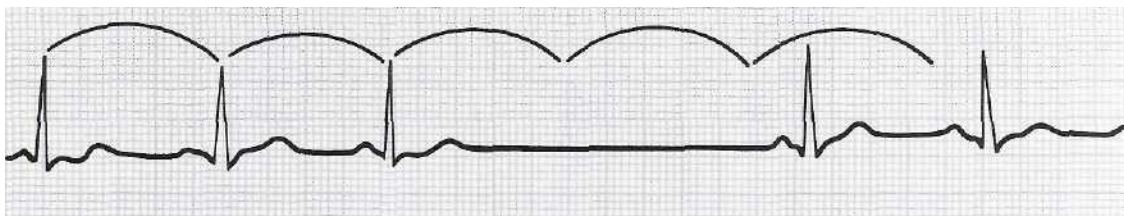
Sinus block occurs when a beat is not transmitted out of the SA node. No R QRS, or T is present at the cycle interval for one or more beats.



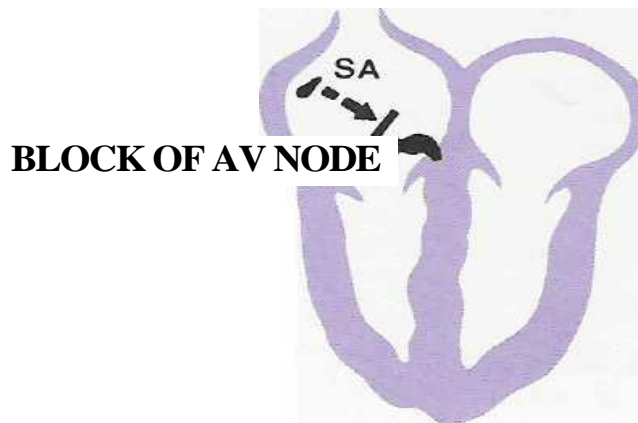
Sinus block

Sinus arrest occurs when the SA node fails to send out an impulse for a period of time. This interval between beats is not a multiple of the heartbeat cycle length. If either event produces symptoms of hemodynamic insufficiency, treatment (atropine or an artificial pacemaker) is indicated.

Sinus arrest



AV blocks. In this condition the AV node is diseased and has difficulty conducting the P waves into the ventricles. The most common causes are arteriosclerosis and myocardial infarction. Digitalis toxicity may also produce such blocks. Scarring, inflammation, or edema prevents or slows



transmission of the electrical impulse by the AV node. The degree of block varies from very slight to complete, and is classified as first, second, or third degree block.


AV BLOCK, FIRST DEGREE

Because the tissue around the AV node is abnormal, the impulse takes longer to traverse the area.

This is reflected by an increased length in the PR interval on the ECG. (The PR interval represents the impulse going through the atrium and the area of the AV node). When the P-wave always precedes the QRS-complex but *the PR-interval is prolonged over 0.2 s*, first-degree atrioventricular block is diagnosed.

First degree AV block.

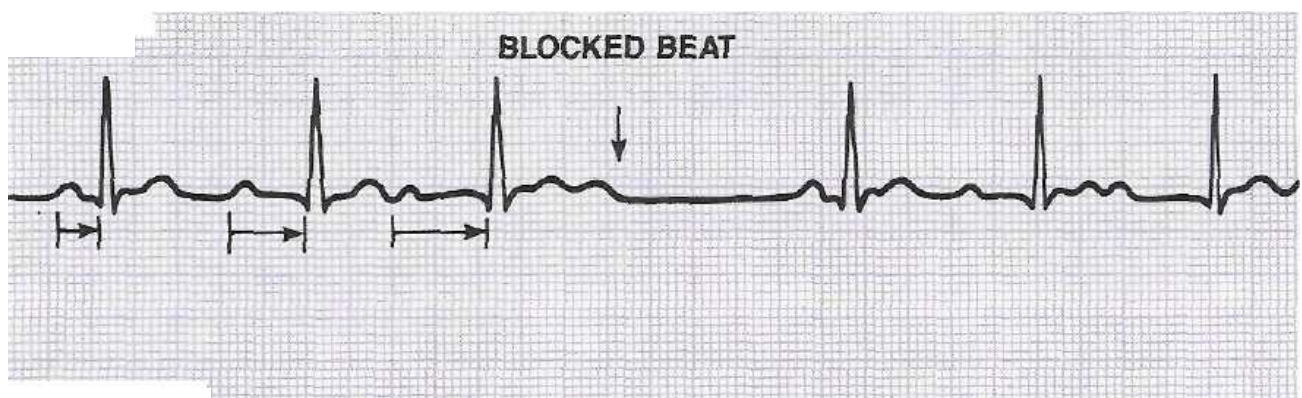
Atrio-ventricular conduction lengthened



SECOND DEGREE AV BLOCK exists when some of the P waves are conducted to the ventricles and others are blocked at the AV node. This condition is divided into two classifications: Mobitz I (Wenckebach) and Mobitz II, or Type I and Type II.

Mobitz I (Wenckebach). The ischemic or drug-affected AV node requires a progressively longer interval of time to transmit each beat until a beat fails to be conducted. When the next impulse arrives, the rested AV node is able to transmit the beat in a shorter time, but the PR interval again lengthens, and the cycle repeats. On the ECG, this results *in a progressive lengthening of the PR interval until a beat is blocked* (P not followed by a QRS), and then the cycle repeats. The rhythm (R-R interval) is irregular, and there are more P waves than QRS complexes.

Mobitz I (Wenckebach) second degree block

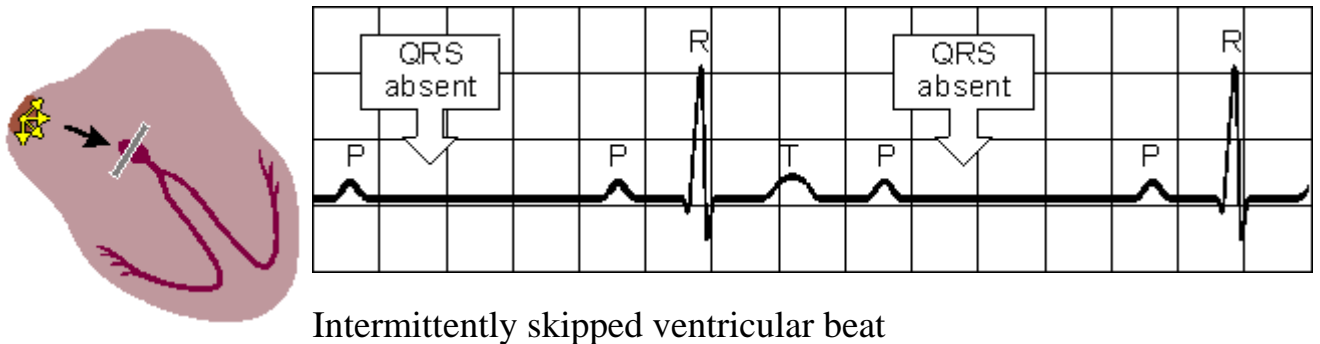


Wenckebach block may be caused by digitalis or MI, especially one involving the inferior wall. It is generally transient and reversible.

In Mobitz II, some beats are conducted and others are not. Conducted beats have a consistent PR interval. In blocked beats, there is a P wave not followed by a QRS complex. One type of pattern shows a specific ratio of blocked beats such as 2:1, 3:1, or 4:1. In such cases, the R-R interval will be regular.

Mobitz II second degree block (2:1 ratio)

Sudden dropped QRS-complex



Third degree AV block is also called **complete heart block**. In this arrhythmia, no atrial impulses (P waves) activate the ventricles. The QRS originates from a junctional or ventricular pacemaker site. Therefore, the P waves and QRS complexes occur independently.

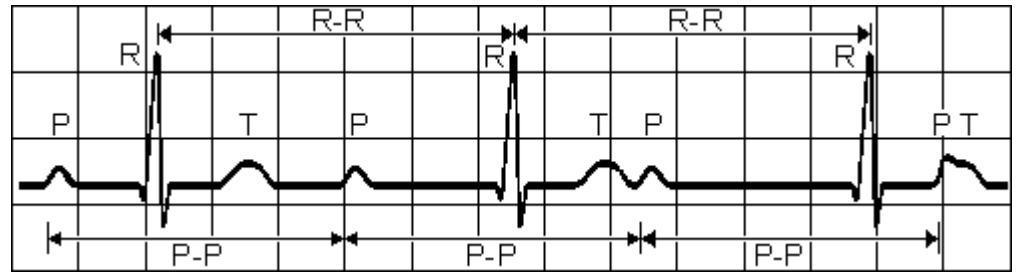
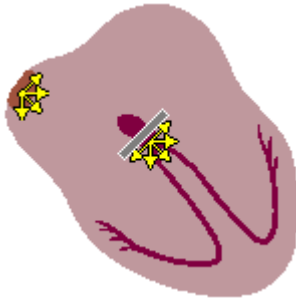
Both the P waves and QRS complexes occur regularly, but there is no relationship between them. The PR interval varies and some P waves may be partly obscured by QRS complexes.

Complete heart block may be caused by inflammation, scarring, myocardial infarction, or drugs such as digitalis. The pulse rate is usually slow because of the inherent rate of junctional or ventricular pacemaker sites. Since these secondary pacemakers are not dependable, the treatment of choice is an artificial pacemaker.

Third degree AV block

Impulses originate at AV node and proceed to ventricles

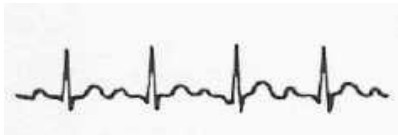



Atrial and ventricular activities are not synchronous



P-P interval normal and constant,

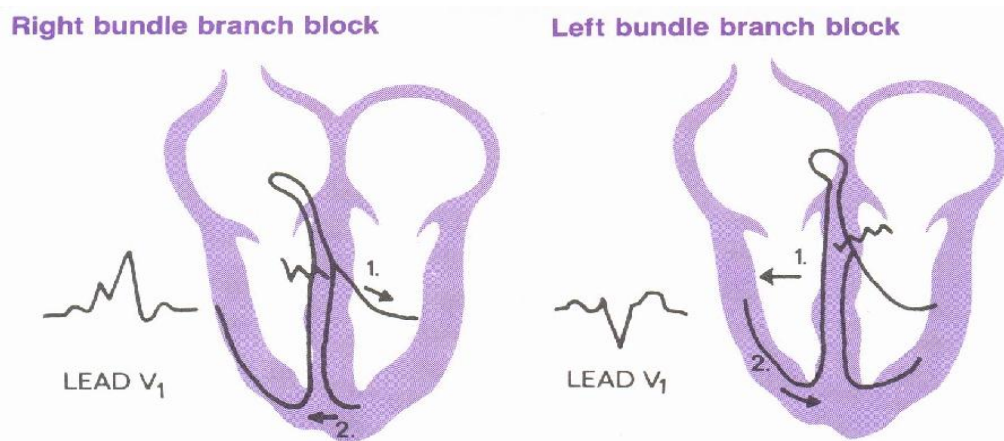
QRS complexes normal, rate constant, 20 - 55 /min

Conduction delays in AV blocks

AV block	Impulses	Rhythm	PR interval	ECG
First degree	All conducted (with delay)	Regular	Prolonged (>0.20 sec); constant	
Second degree Mobitz I (Wenckebach)	Some conducted, some blocked	Irregular	Progressively longer until dropped beat; cyclic pattern	
Second degree Mobitz II	Some conducted, some blocked	Regular or irregular	Constant for conducted beats; some Ps without QRSs; can appear 2:1, 3:1, or occasionally blocked Ps	
Third degree	None conducted	Regular QRS; independent regular P	Variable; no P-QRS relationship	

BUNDLE BRANCH BLOCK

Bundle branch block is an obstruction in the right or left ventricular conduction pathway. When this occurs, the impulse travels first through the unobstructed branch and is then transmitted by non specialized myocardial tissue to the opposite ventricle. This aberrant pathway requires a longer time for activation of the ventricles, and the resulting QRS is greater than 0.12 second. Origin of this beat is from the atria - usually, the SA node. Therefore, a P wave will precede the wide QRS.



Bundle branch block may occur in a single premature beat, because either the right or left branch has not yet been repolarized. It may occur when the rate becomes too fast to permit adequate repolarization between beats (rate-dependent). It may also result from disease or ischemia in this part of the conduction system.

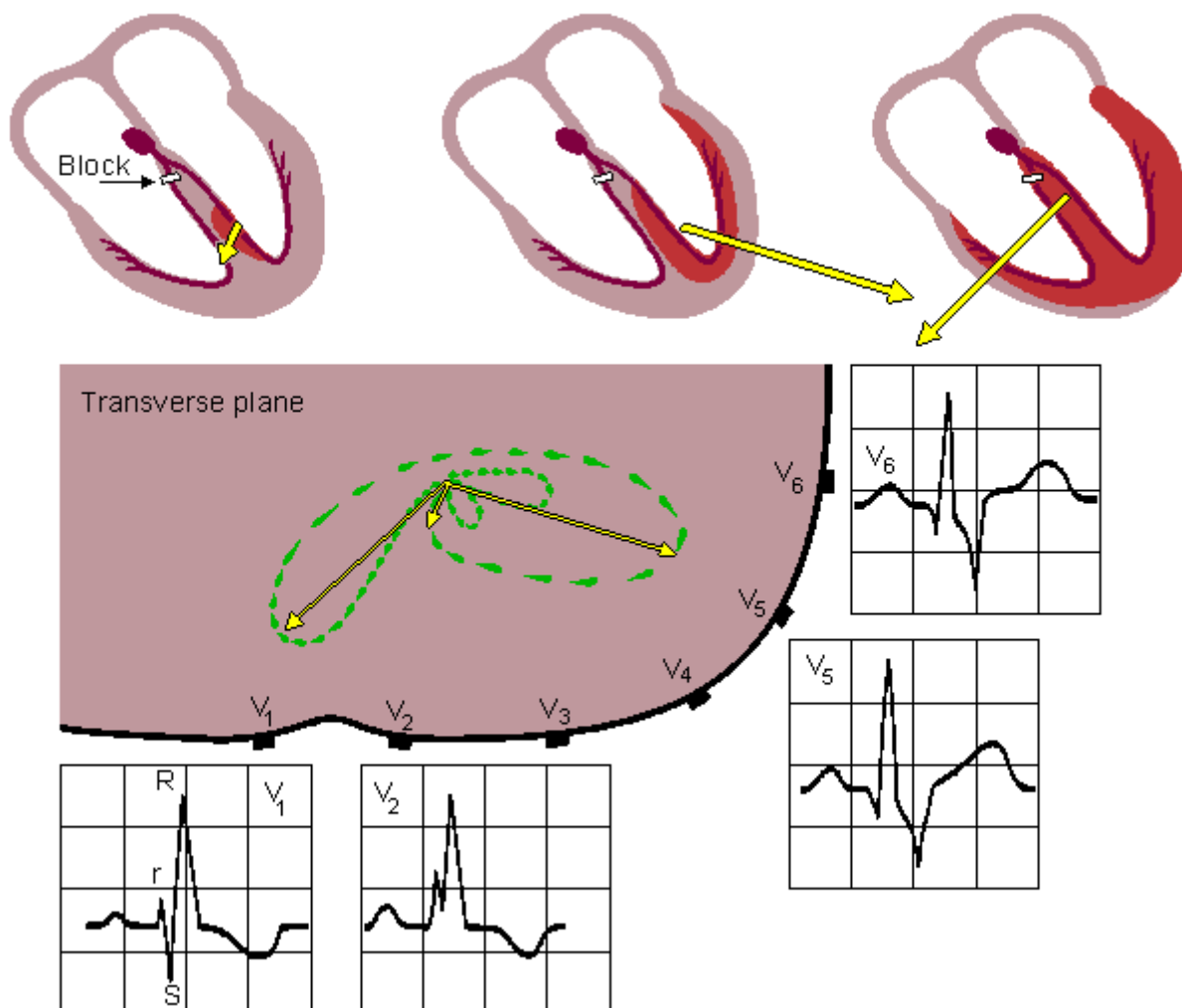
Right bundle-branch block

If the right bundle-branch is defective so that the electrical impulse cannot travel through it to the right ventricle, activation reaches the right ventricle by proceeding from the left ventricle. It then travels through the septal and right ventricular muscle mass. This progress is, of course, slower than that through the conduction system and leads to a QRS-complex wider than 0.1 s. Usually the duration criterion for the QRS-complex in right bundle-branch block (RBBB) as well as for the left bundle-branch block (LBBB) is $>0.12s$.

RIGHT BUNDLE-BRANCH BLOCK

QRS duration greater than 0.12 s

Wide S wave in leads I, V₅ and V₆



With normal activation the electrical forces of the right ventricle are partially concealed by the larger sources arising from the activation of the left ventricle.

In right bundle-branch block (RBBB), activation of the right ventricle is so much delayed, that it can be seen following the activation of the left ventricle. (Activation of the left ventricle takes place normally.)

RBBB causes an abnormal terminal QRS-vector that is directed to the right ventricle (i.e., rightward and anterior). This is seen in the ECG as a **broad terminal S-wave in lead I, V₅ and V₆**. Another typical manifestation is seen **in lead V₁ as a double R-wave**. This is named an RSR'-complex (M-shaped).

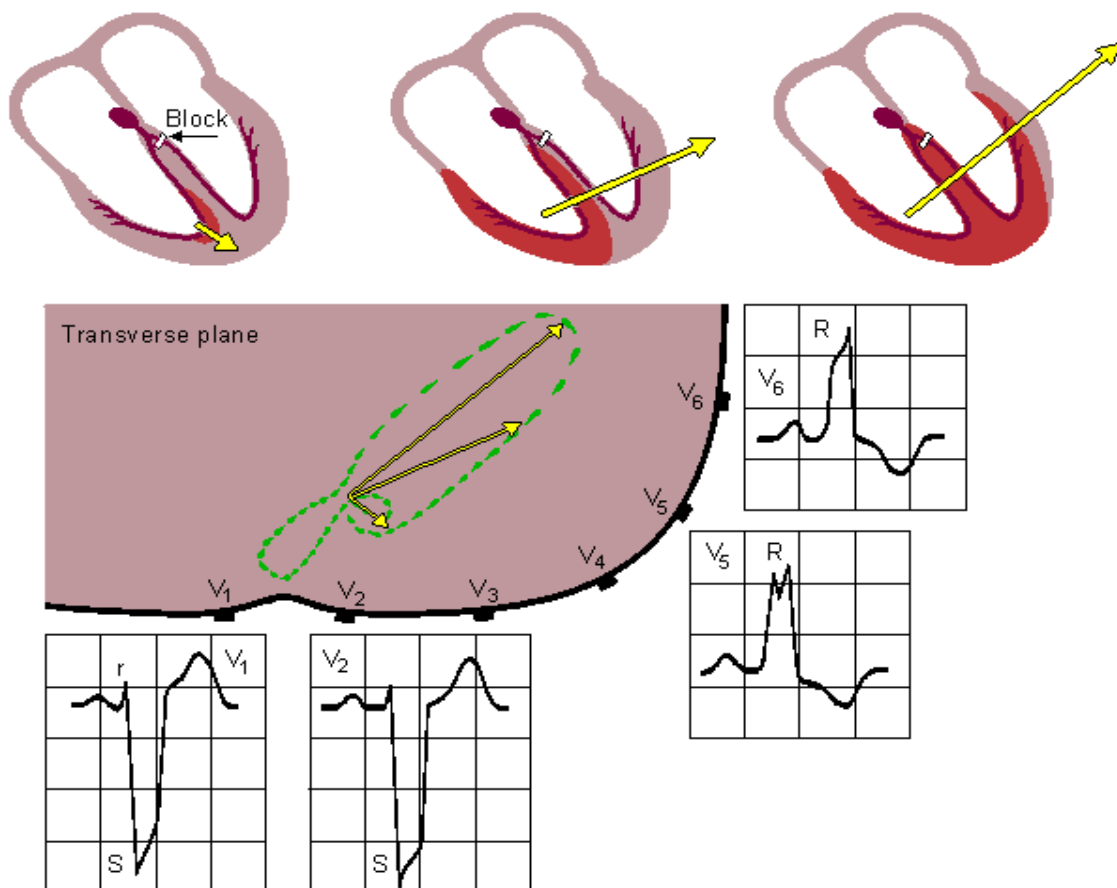
Left bundle branch block

The situation in left bundle-branch block (LBBB) is similar, but activation proceeds in a direction opposite to RBBB. Again the duration criterion for complete block is 0.12 s or more for the QRS-complex. Because the activation wavefront travels in more or less the normal direction in LBBB, the signals' polarities are generally normal. However, because of the abnormal sites of initiation of the left ventricular activation front and the presence of normal right ventricular activation the outcome is complex and the electric heart vector makes a slower and larger loop to the left and is seen as *a broad and tall R-wave, usually in leads I, aVL, V₅, or V₆*.

LEFT BUNDLE-BRANCH BLOCK

QRS duration greater than 0.12 s

Wide S wave in leads V₁ and V₂, wide R wave in V₅ and V₆



Right bundle branch block is more common because the right branch is a long, narrow pathway. The left bundle branch is thicker at its origin and subdivides into anterior and posterior branches. When one of these subdivisions (fascicles) becomes blocked, it is called a hemiblock, or mono-fascicular block. It does not produce a QRS greater than 0.12 sec, and is diagnosed by axis determination. When the right bundle branch and either fascicle of the left bundle become blocked, it is called bifascicular block.

Trifascicular block indicates a combination of two "fascicles" plus first degree AV block. This is dangerous because of the many areas involved, and a pacemaker is indicated.

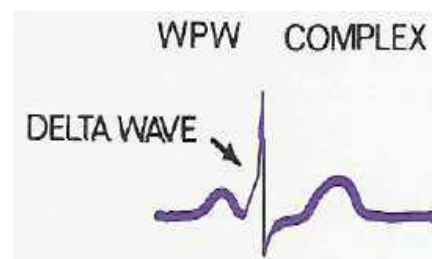
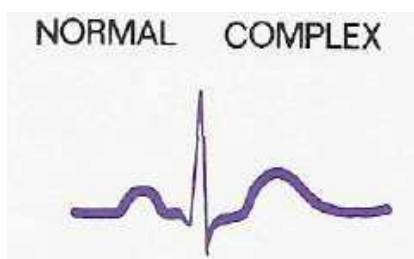
ECG FOR WOLFF- PARKINSON - WHITE (WPW)

Wolff-Parkinson-White (WPW) syndrome. One cause for a broad QRS-complex that exceeds over 0.12 s, may be the Wolff-Parkinson-White syndrome (WPW syndrome). In the WPW syndrome the QRS-complex initially exhibits an early upstroke called the *delta wave*. The interval from the P-wave to the R spike is normal, but the early ventricular excitation forming the delta wave shortens the PQ-time.

The cause of the WPW syndrome is the passage of activation from the atrium directly to the ventricular muscle via an abnormal route, called the *bundle of Kent*, which bypasses the AV junctions. This activates part of the ventricular muscle before normal activation reaches it via the conduction system (after a delay in the AV junction). The process is called pre-excitation, and the resulting ECG depends on the specific location of the accessory pathway.

The syndrome carries the names of the physicians who described one atypical conduction pattern. The ECC is characterized by:

1. A short PR interval (less than 0.12 sec)
2. A slurred upstroke on the QRS (delta wave)
3. A wide QRS (greater than 0.12 sec)
4. Secondary ST and T wave changes (repolarization is altered)

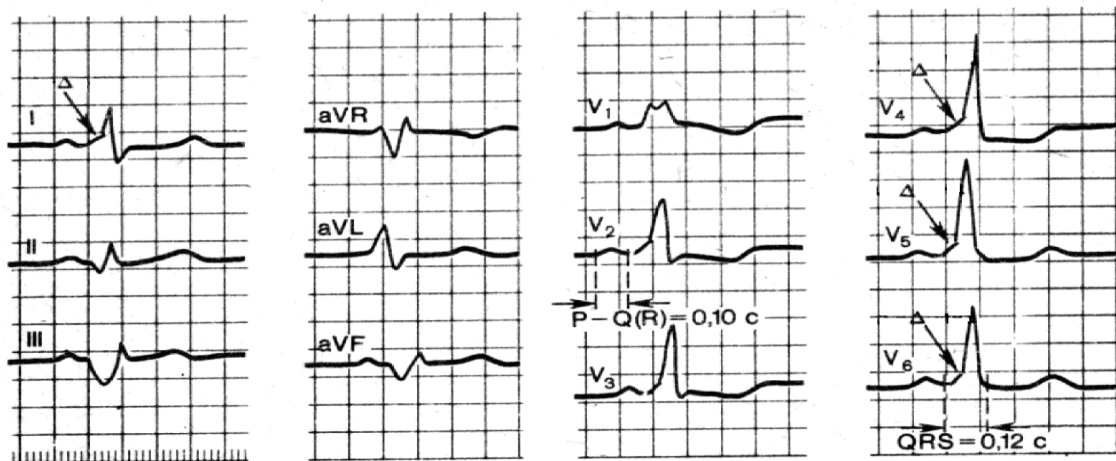


The mechanism of WPW is thought to be the utilization of a highly developed accessory branch of the conduction system called the bundle of Kent. This connects the conduction system of the atria to either ventricle,

bypassing the AV node. This could occur on either the left (type A) or right (type B) side of the heart. Impulses go down the accessory pathway and return by the normal conduction system to set up a re-entry system.

Patients with this condition are subject to episodes of supraventricular tachycardia. This arrhythmia may be resistant to the usual treatment for PAT.

It is important to differentiate it from ventricular tachycardia and other arrhythmias with wide QRS complexes.



Another pre-excitation pattern is the **Lown-Ganong-Levine** syndrome, characterized by a short PR interval without a delta wave.

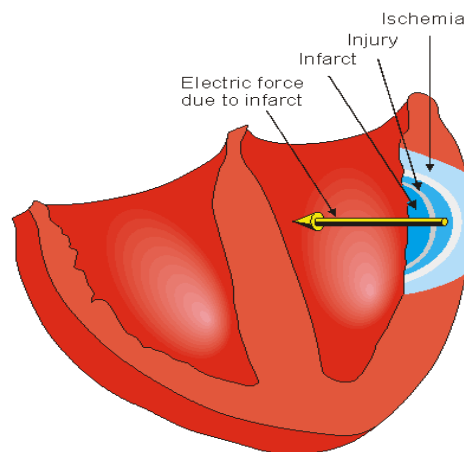
IDENTIFICATION OF MYOCARDIAL INFARCTION

One of the most significant uses of a 12-lead ECG is to aid in determining whether a myocardial infarction has occurred. The physician can locate the damage by noting which leads show indicative changes:

- *inferior infarct*: this shows changes in the inferior leads (II,III,aVF)
- *anterior (small)*: leads V3,4
- *anterior (extensive)*: leads V2-5
- *anteroseptal infarct*: leads V1-4
- *anterolateral infarct*: (V4-6,I,aVL)
- *posterior infarct*: mirror image changes in V1-2, tall and ST depression
- *lateral infarct*: leads I,II,AVL
- *subendocardial*: any lead, T wave inversion may be the only sign

Many factors can influence the 12-lead ECG interpretation.

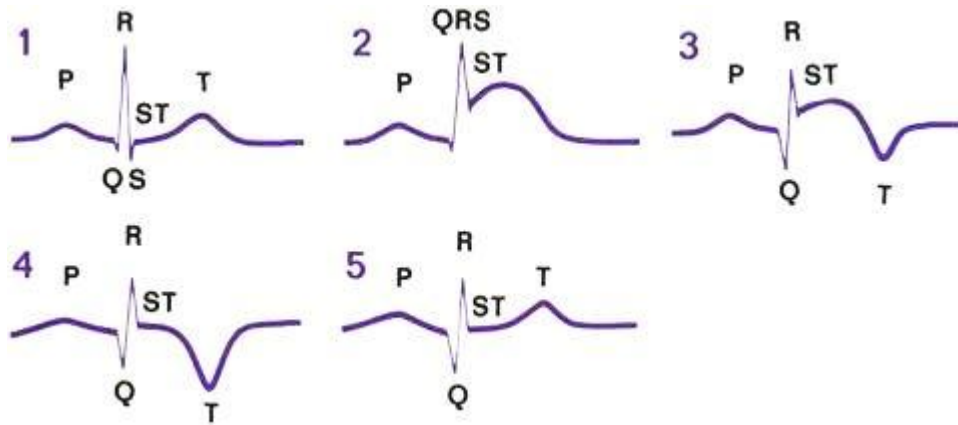
One important point to remember about the ECG interpretation of MI is that about 15 per cent of infarcts show no changes on the initial tracing. ECG changes evolve later in hours or days as tissue damage changes electrical impulse conduction pathways. The usual first finding in an infarct is elevation of the ST segment. This is followed by T wave inversion, which in turn is followed by a large Q wave. As the infarct heals, the Q wave may remain as the only sign of an old infarction. This is the sequence:



Sequence of the ECG following MI

ECG	
Q - wave acute myocardial infarction	
The earliest signs of acute myocardial infarction are subtle and include increased T wave amplitude over the affected area. T waves become more prominent, symmetrical, and pointed (“hyperacute”) – ischemia	
Hours after infarction, the ST segment becomes elevated – injury	
Pathological Q waves may appear within hours or may take greater than 24 hr. A Q wave may be considered abnormal if it is over 0.03 second wide, or if it is greater in depth than one-fourth the height of the QRS complex – necrosis (infarct) .	
Hours to days later, the T wave inverts and the Q wave becomes larger.	
In non Q-wave infarcts , ST depression and T wave inversion occur without ST elevation.	

Sequence of the ECG following MI. (1) Normal. (2) Hours after infarction, the ST segment becomes elevated. (3) Hours to days later, the T wave inverts and the Q wave becomes larger. (4) Days to weeks later, the ST segment returns to near-normal. (5) Weeks to months later, the T wave becomes upright again, but the Q wave may remain large.



In summary: A fresh myocardial infarction is characterized by ST elevation and T wave inversion. An enlarged Q wave without ST or T wave changes is indicative of an old infarction. No Q wave may appear if the infarction is subendocardial (not through the complete thickness of the wall).

Tests

1. Electrocardiographic monitoring provides information about the heart's:
 - a. coronary arteries
 - b. force of contraction
 - c. electrical activity
 - d. cardiac output

2. Which of these electrodes is always negative?
 - a. left leg
 - b. left arm
 - c. right leg
 - d. right arm

3. After the cardiac impulse leaves the SA node and depolarizes the atria, it goes to the:
 - a. Purkinje fibers
 - b. left bundle branch
 - c. AV node
 - d. bundle of His

4. The normal physiological pacemaker is the:
 - a. bundle of His
 - b. AV node
 - c. SA node
 - d. Purkinje fibers

5. The normal PR interval is
 - a. 0.10-0.12
 - b. 0.12-0.20
 - c. 0.04-0.12
 - d. 0.04-0.20

6. The wave form that represents ventricular repolarization is the:
 - a. P
 - b. PR
 - c. QRS
 - d. T

7. Lead II shows electrical activity from the:
 - a. right arm to left leg
 - b. right arm to right leg
 - c. left arm to left leg
 - d. left arm to right leg

8. The SA node normally discharges at the rate of:

- a. 40-60
- b. 60-80
- c. 20-40
- d. 60-100

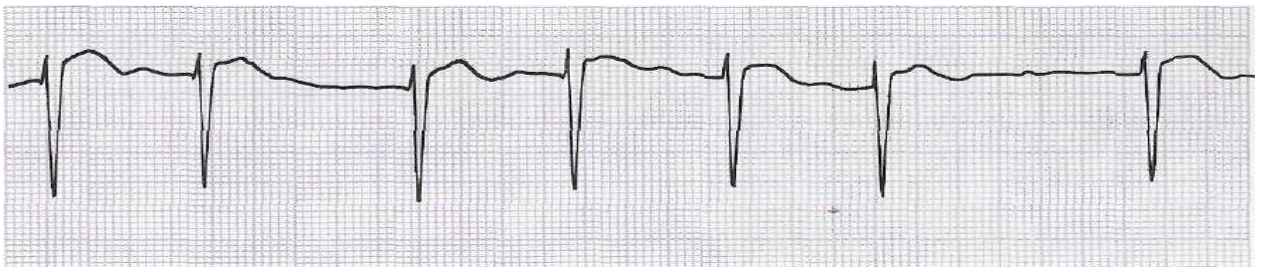
9. On the ECG, the P wave corresponds to:

- a. atrial depolarization
- b. ventricular depolarization
- c. ventricular repolarization
- d. junctional repolarization

10. On the ECG paper (50 mm/s), the width of each small square is:

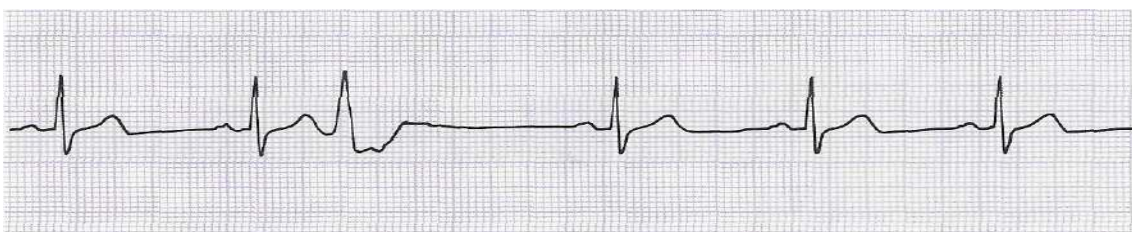
- a. 0.02 sec
- b. 0.04 sec
- c. 0.12 sec
- d. 0.20 sec

11. Interpret the ECG. What violation of the rhythm does a patient have?



- a. Sinus (respiratory) arrhythmia
- b. Atrial fibrillation
- c. PVC (Ventricular extrasystole)
- d. Atrioventricular block (I degree)

12. Interpret the ECG. What violation of the rhythm does a patient have?

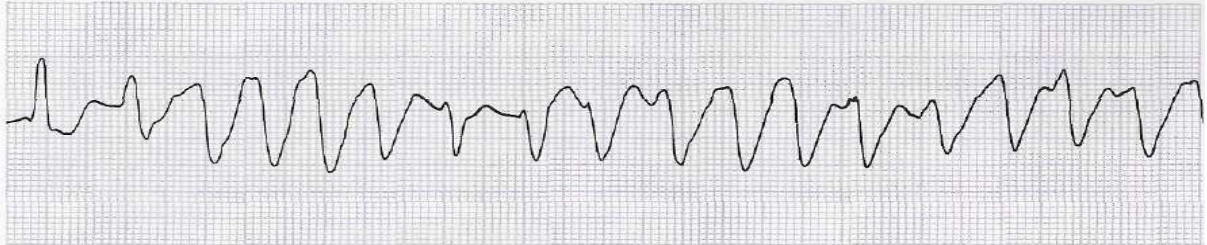


- a. Sinus (respiratory) arrhythmia
- b. Atrial fibrillation

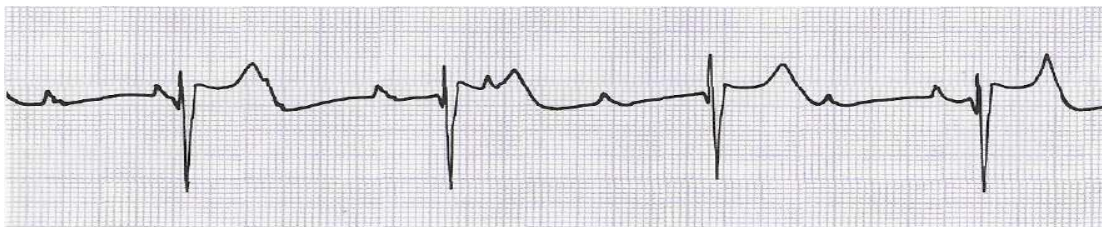
- c. PVC (Ventricular extrasystole)
- d. Atrioventricular block (I degree)

13. Interpret the ECG. What violation of the rhythm does a patient have?

- a. Sinus (respiratory) arrhythmia
- b. Atrial fibrillation
- c. PVC (Ventricular extrasystole)
- d. Ventricular fibrillation

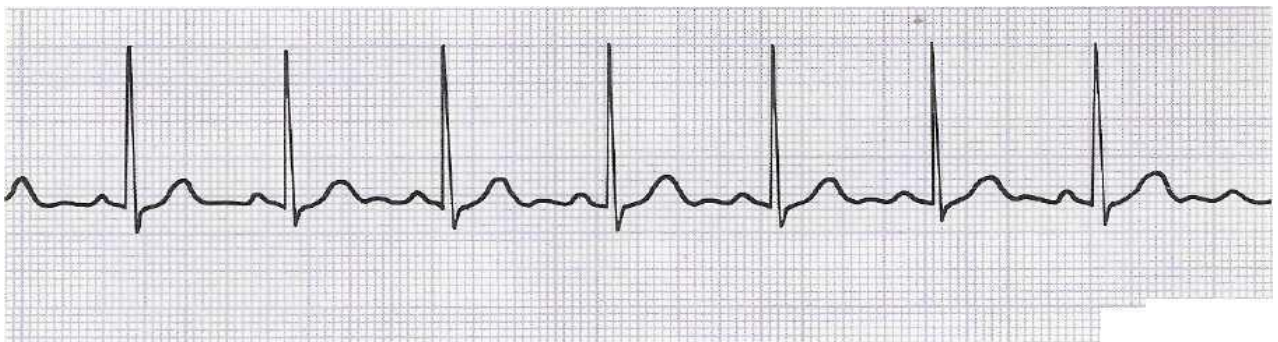


14. Interpret the ECG. What violation of the block does a patient have?



- a. Atrioventricular block (I degree)
- b. Atrioventricular block (II degree)
- c. Atrioventricular block (III degree)
- d. SA block.

15. Interpret the ECG. What violation of the rhythm does a patient have?



- a. Sinus rhythm
- b. Atrial flutter
- c. Paroxysmal tachycardia
- d. Atrioventricular block (I degree)

Answers

1c	2d	3c	4c	5b
6c	7a	8b	9a	10a
11b	12c	13d	14c	15a

Literature

1. Goldman MJ (1986): *Principles of Clinical Electrocardiography*, 12th ed., 460 pp. Lange Medical Publications, Los Altos, Cal.
2. Macfarlane PW, Lawrie TDV (eds.) (1989): *Comprehensive Electrocardiology: Theory and Practice in Health and Disease*, 1st ed., Vols. 1, 2, and 3, 1785 pp. Pergamon Press, New York.
3. Netter FH (1971): Heart, Vol. 5, 293 pp. *The Ciba Collection of Medical Illustrations*, Ciba Pharmaceutical Company, Summit, N.J.
4. Scheidt S (1983): *Basic Electrocardiography: Leads, Axes, Arrhythmias*, Vol. 2/35, 32 pp. Ciba Pharmaceutical Company, Summit, N.J.
5. Scheidt S (1984): *Basic Electrocardiography: Abnormalities of Electrocardiographic Patterns*, Vol. 6/36, 32 pp. Ciba Pharmaceutical Company, Summit, N.J.

CONTENTS

GLOSSARY	3
NORMAL ECG AND RELATED HEART ANATOMY.....	7
THE ECG LEADS.....	17
DETERMINATION OF THE ELECTRIC AXIS OF THE HEART.....	22
ATRIAL AND VENTRICULAR HYPERTROPHIES.....	24
CARDIAC RHYTHM DIAGNOSIS.....	28
DENERMINATION THE HEART RATE	32
INTERPRETATION OF ECG.....	34
ECTOPIC RHYTHMS.....	35
PREMATURE CONTRACTIONS	37
ATRIAL FLUTTER AND FIBRILLATION.....	42
VENTRICULAR FIBRILLATION.....	44
PAROXYSMAL TACHYCARDIA.....	47
BLOCKS.....	50
BUNDLE BRANCH BLOCK.....	56
ECG FOR WOLFF- PARKINSON - WHITE	60
IDENTIFICATION OF MYOCARDIAL INFARCTION.....	62
TESTS.....	65
LITERATURE.....	69
CONTENTS.....	70