

Immunohistochemical changes of maxillary sinus mucosa with underlying adenomatous polyposis

Yu. M. Andreychyn¹, I. S. Kovalenko²

¹State Institution of Higher Education "I. Horbachevsky Ternopil State Medical University of the Ministry of Health of Ukraine",

²Zaporizhzhia State Medical University, Ukraine

Introduction. In maxillary sinusitis pathogenesis researchers paid much attention to the role of paranasal sinuses, sinus drainage dysfunctions, mucociliary transport system disorders in cases of damage of sinuses mucous membranes. Pathohistological, immunohistochemical and morphometric studies of mucosa were conducted. However, to evaluate the local inflammatory response in cases of chronic sinusitis and improvement of individual therapy for the patients, the immunohistochemical studies of the composition of inflammatory immunocyte infiltrates of paranasal sinus mucosa and adenoid vegetations bioplate would be reasonable.

The aim of the research was to study the immunohistochemical content of immunocyte infiltrates of paranasal sinuses adenomatous polyps in biopsy samples of patients suffering from chronic sinusitis.

Materials and Methods. Paranasal sinuses adenomatous polyps removed during surgery of 22 patients suffering from chronic maxillary sinusitis were studied. Immunohistochemical studies of paraffin sections of the removed polyps were performed using appropriate primary antibodies and visualization systems DAKO EnVision+ System (DAKO, Denmark).

Results. During microscopic investigation of paranasal sinuses adenomatous polyps of the patients suffering from chronic sinusitis, moderate and severe immunocyte infiltration of polyp stroma sometimes with focal follicular structures was presented. Immunohistochemical investigation of the cellular composition of these infiltrates proved the presence of CD8+ T-killer cells, CD4+ T-helper cells, CD68+ macrophages as well as single plasma cells. The irregularity of these cells markers expression was determined in dependence of the severity of inflammatory cell infiltration.

Conclusions. In the patients with chronic maxillary polyp sinusitis with mild and moderate immunocyte infiltration of paranasal sinus mucosa, among immune cells the CD4+ T-lymphocytes occupied the most relative area in polyp stroma, plasma cells – the least ($p < 0.001$). In the patients with significant immunocellular infiltration in immunocyte follicular infiltration of polyp stroma the relative area of CD4+ and CD8+ T-lymphocytes significantly exceeded the relative area of macrophages and plasma cells.

Key words:

maxillary sinusitis, adenomatous polyp, subpopulation of T-lymphocytes, macrophages, plasma cells.

Pathologia

2017; 14 (1), 91–94

DOI:

10.14739/2310-1237.2017.1.97793

E-mail:

yandrachyn@tdmu.edu.ua

Імуногістохімічні зміни слизової оболонки верхньощелепного синуса при аденоматозному поліпозі

Ю. М. Андрейчин, І. С. Коваленко

У патогенезі верхньощелепних синуситів досі найбільшу увагу дослідники приділяли ролі співусть приносних пазух, порушенню їхньої дренажної функції, зменшенню дієздатності мукоциліарної транспортної системи при ураженні слизової оболонки синусів. Для цього застосовувалися патогістологічні, імуногістохімічні та морфометричні дослідження слизової оболонки. Однак для сучасного оцінювання місцевої запальної реакції під час хронічних синуситів та уточнення персоналізованої терапії хворих доцільними є імуногістохімічні дослідження складу запальних та імуноклітинних інфільтратів біоптатів слизової оболонки приносних пазух та аденоїдних вегетацій.

Мета роботи – імуногістохімічне визначення клітинного складу імуноцитарних інфільтратів аденоматозних поліпів додаткових пазух носа в біопсійно-операційному матеріалі хворих на хронічний синусит.

Матеріали та методи. Досліджено аденоматозні поліпи додаткових пазух носа, що вилучені під час операції у 22 хворих на хронічний верхньощелепний синусит. У парафінових зрізах видалених поліпів виконувались імуногістохімічні дослідження з використанням відповідних первинних антигенів і системи візуалізації DAKO EnVision+ System («DAKO», Данія).

Результати. Під час мікроскопічного дослідження аденоматозних поліпів додаткових пазух носа хворих на хронічний синусит виявлена помірна та виразна імуноцитарна інфільтрація стромі поліпів, іноді – з формуванням вогнищевих фолікулоподібних структур. Імуногістохімічний аналіз клітинного складу таких інфільтратів показав наявність у них CD8+ Т-кілерів, CD4+ Т-хелперів, CD68+ макрофагів, а також поодиноких плазматичних клітин. Встановлена нерівномірність експресії маркерів цих клітин залежно від виразності запально-клітинної інфільтрації.

Висновки. У хворих на хронічний верхньощелепний поліпозний синусит зі слабкою та помірною імуноцитарною інфільтрацією слизової оболонки додаткових пазух у стромі поліпів серед імуноцитів найбільшу відносну площу займали CD4+ Т-лімфоцити, найменшу – плазматичні клітини ($p < 0,001$). У пацієнтів із виразною імуноклітинною інфільтрацією в імуноцитарних фолікулоподібних інфільтратах стромі поліпів відносна площа CD4+ та CD8+ Т-лімфоцитів статистично значуще перевищувала відносну площу макрофагів і плазматичних клітин.

Ключові слова:

верхньощелепний синусит, аденоматозний поліп, субпопуляції Т-лімфоцитів, макрофаги, плазматичні клітини.

Патологія. – 2017. – Т. 14, № 1(39). – С. 91–94

Имуногистохимические изменения слизистой оболочки верхнечелюстного синуса при аденоматозном полипозе

Ю. М. Андрейчин, И. С. Коваленко

В патогенезе верхнечелюстных синуситов до сих пор наибольшее внимание исследователи уделяли роли околоносовых пазух, нарушению их дренажной функции, уменьшению дееспособности мукоцилиарной транспортной системы при

Ключевые слова: верхнечелюстной синусит, аденоматозный полип, субпопуляции Т-лимфоцитов, макрофаги, плазматические клетки.

Патология. – 2017. – Т. 14, № 1(39). – С. 91–94

поражении слизистой оболочки синусов, что приводит к снижению её резистентности к инфекции. Однако для оценки местной воспалительной реакции и уточнения персонализированной терапии больных целесообразно осуществлять иммуногистохимические исследования состава воспалительных и иммунноклеточных инфильтратов биоптатов слизистой оболочки околоносовых пазух и аденоидных вегетаций.

Цель работы – иммуногистохимическое исследование клеточного состава иммунноклеточных инфильтратов аденоматозных полипов придаточных пазух носа в биопсийно-операционном материале больных хроническим синуситом.

Материалы и методы. Исследованы аденоматозные полипы придаточных пазух носа, изъятые во время операции у 22 больных хроническим верхнечелюстным синуситом. В парафиновых срезах удалённых полипов выполнялись иммуногистохимические исследования с использованием соответствующих первичных антител и системы визуализации DAKO EnVision+ System («ДАКО», Дания).

Результаты. Субпопуляции Т-лимфоцитов, макрофаги и плазматические клетки определялись иммуногистохимически с помощью моноклональных антител. Иммуногистохимический анализ показал наличие в инфильтратах CD8+ Т-киллеров, CD4+ Т-хелперов, CD68+ макрофагов, отдельных плазматических клеток. Установлена неравномерность экспрессии маркеров этих клеток в зависимости от выраженности воспалительно-клеточной инфильтрации.

Выводы. В строме пластинки слизистой оболочки придаточных пазух больных хроническим верхнечелюстным синуситом с аденоматозными полипами выявлена умеренная или выраженная иммуноцитарная инфильтрация, иногда с формированием фолликулоподобных структур. Наибольшую площадь занимали CD4+ Т-лимфоциты, наименьшую – плазматические клетки ($p < 0,001$). В случае фолликулоподобных структур площадь CD4+ и CD8+ Т-лимфоцитов значительно возрастала по сравнению с площадью макрофагов и плазматических клеток.

In maxillary sinusitis pathogenesis researchers paid much attention to the role of paranasal sinuses, sinus drainage dysfunctions, mucociliary transport system disorders in cases of damage of sinuses mucous membranes that causes infection resistance decrease, mucus stagnation and pathological processes progression [1–3]. Some researches were about various structural anomalies of the nasal cavity and paranasal sinuses, adenoid vegetations [4,5], influence of allergic factor [6,7]. Pathohistological, immunohistochemical and morphometric studies of mucosa were conducted [8].

However, it would be reasonable to evaluate the local inflammatory response in cases of chronic sinusitis and improve individual therapy for the patients, immunohistochemical studies of the composition of inflammatory and immunocyte infiltrates of paranasal sinus mucosa and adenoid vegetations biopate.

The aim of the research is to study the immunohistochemical content of immunocyte infiltrates of paranasal sinuses adenomatous polyps in bioptic samples of the patients suffering from chronic sinusitis.

Materials and Methods

A complex pathomorphological investigation of paranasal sinuses adenomatous polyps removed during surgery of 22 patients (12 males and 10 females), 18–63 years old, suffering from chronic sinusitis, was conducted.

According to standard protocols, immunohistochemical studies in paraffin sections of adenomatous polyps after heat-induced epitope retrieval and endogenous peroxidase inhibition were performed using appropriate primary antibodies and visualization systems DAKO EnVision+ System with diaminobenzidine (DAKO, Denmark). CD8+ and CD4+ T-lymphocytes subpopulations in immunocellular infiltrates of polyps were marked using monoclonal antibodies *Mo a-Hu CD8, T-cell Clone C8 / 144B* and *Mo a-Hu CD4, Clone MT310* (DAKO, Denmark). Macrophages and plasma cells of immunocellular infiltrates were determined using monoclonal antibodies *Mo a-Hu CD68, Clone PG-M1* (DAKO, Denmark) and *Mo a-Hu Plasma Cell Ab-1 Clone LIV3G11* (NeoMarkers, USA).

The results of each immunohistochemical reaction were evaluated by means of standard microscope Axioplan 2 (Carl Zeiss, Germany), magnification x200, in each case 200 cells in 5 fields of view were analysed. The relative areas of CD8+ and CD4+ T lymphocytes, CD68+ macrophages and plasma cells in adenomatous polyps were estimated in percents by photo-digital morphometry in a standard area of histological sections (SAHS) of these polyps. SAHS were photo-digital illustration of adenomatous polyps histologic section captured by digital camera Olympus 3040 (Japan) at Axioplan 2 microscope (Carl Zeiss, Germany) amplification x200 in 5 fields of view. By means of the Image J program the relative area of immune-positive cells, which was the percentage of the number of pixels of corresponding immune-positive cells to the total number of pixels in a digital image of adenomatous polyps, was determined. Statistical analysis of the results was performed by Statistica® for Windows 6.0 (StatSoft Inc., USA, license No. AXXR712D833214FAN5). The mean value (M) and standard deviation (σ) were evaluated. Statistical significance of the differences in the compared values was determined by Student's t-test (T). The results were significant at $p < 0.05$.

Results and discussion

During microscopic investigation of paranasal sinuses adenomatous polyps of the patients suffering from chronic sinusitis, moderate and severe immunocyte infiltration of polyp stroma sometimes with focal follicular structures was presented. Immunohistochemical investigation of the cellular composition of these infiltrates proved the presence of CD8+ T-killer cells, CD4+ T-helper cells, CD68+ macrophages as well as single plasma cells (Fig. 1 A, B, C, D). Similar features of morphological structure of nasal polyps were noted by other authors who described multiple focal and diffuse immunocyte infiltration in the epithelium and stroma of the polyps; CD4+ T-helper cells, CD8+ T-killer cells, CD3+ and CD25+ activated lymphocytes, eosinophils, mast cells and a significant number of CD68+ macrophages were determined in their content [9–11].

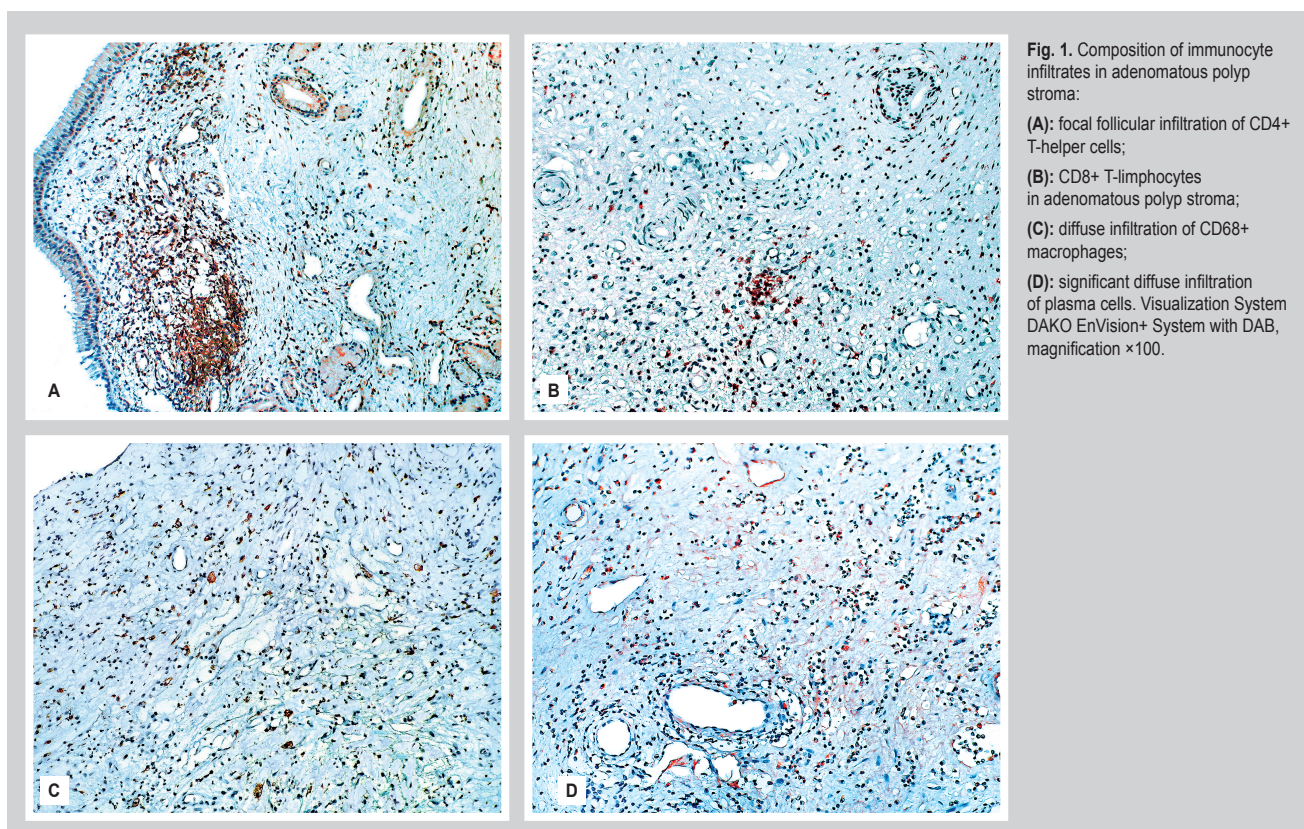


Fig. 1. Composition of immunocyte infiltrates in adenomatous polyp stroma:
(A): focal follicular infiltration of CD4+ T-helper cells;
(B): CD8+ T-lymphocytes in adenomatous polyp stroma;
(C): diffuse infiltration of CD68+ macrophages;
(D): significant diffuse infiltration of plasma cells. Visualization System DAKO EnVision+ System with DAB, magnification $\times 100$.

The expression irregularity of lymphocytic cells markers, macrophages and plasma cells depending on the severity of inflammatory cell infiltration was determined during simultaneous immunohistochemical and morphometric investigation of cellular composition of immunocyte infiltrate of adenomatous polyp stroma. In the patients with mild and moderate immunocyte infiltration of polyp proper mucous plate with no immunocyte follicles or with single follicular structures, the average index of relative area occupied by CD4+ T-lymphocytes was $(2.80 \pm 1.23)\%$, CD8+ T-lymphocytes – $(2.46 \pm 3.72)\%$, CD68+ macrophages – $(1.38 \pm 0.64)\%$ and plasma cells – $(0.86 \pm 0.59)\%$. These first two values are significantly different from the last two ($p < 0.001$). Thus, in the patients with mild and moderate immunocyte infiltration with single follicular structures CD4+ T-lymphocytes occupied the most area and plasma cells – the least. Distribution irregularity of immunocyte infiltration cells was detected by other researchers too, and it mainly depended on different kinds of nasal polyps and their etiological factors. For example, it was found that in the epithelium and stroma of non-allergic nasal polyps there were a number of CD8+ cells and a small amount of CD4+ cells, as opposed to polyps of the patients with allergy symptoms [11]. In addition, according to some studies [12], CD68+ macrophages with significant expression of mannose receptors were often defined along with the CD4+ T-cells and plasma cells in polyp stroma. The expression was associated with phagocytic activity of macrophages and their transduction anti-inflammatory signals to explain recurrent course of chronic inflammation in cases of sinusitis.

In the patients with significant immune-cellular infiltration of polyp stroma with follicular immunocyte structures,

the area of CD4+ T-helper cells and CD8+ T-killer cells increased much. Average rate of relative area occupied by CD4+ T-helper cells and CD8+ T-killer cells increased by (4.29 ± 2.80) and $(3.53 \pm 5.56)\%$ respectively. The relative area occupied by CD68+ macrophages and plasma cells with underlying significant immunocellular infiltration was (1.56 ± 0.83) and $(1.37 \pm 0.75)\%$, respectively. The above mentioned area rates of CD4+ and CD8+ T-lymphocytes were significantly larger than the area of macrophages and plasma cells ($p < 0.001$). Similar results of histological and histochemical study of mucosa bioplate in patients suffering from sinusitis were also achieved by other authors [8,11]. The obtained data prove that, when increasing of inflammatory cell infiltration of stroma and accumulation of inflammatory mediators associated with prolonged tissue damage takes place, polyp cells become resistant to immune mediated apoptosis [11,13]. According to the researches of W. Fokkens et al. and P. Gevaert et al. [14,15], the follicular clusters of immune cells in the stroma of nasal polyps with underlying abundant inflammatory cell infiltration of CD20+ B-cells, CD3+ T-cells and plasma IgE+ cells was found in polyps in cases of staphylococcal infection.

Some researchers studied the profile and level of factors expression with pro- and anti-apoptosis activity depending on the severity and changes in the cell composition of immunocyte infiltration in the stroma of various types of nasal polyps. The eosinophils and lymphocytes resistant to the Fas-L/Fas-mediated apoptosis were found in the immunocyte infiltrates content. Besides, low expression of DFF-45 (DNA fragmentation factor subunit alpha) was detected in the stroma of the most of nasal polyps, so polyp cells with abundant immunocyte infiltration were more resistant to apoptosis with more active

proliferative properties. Also in the polyp stroma, RCAS1 (receptor-binding cancer antigen expressed on SiSo cells) positive macrophages responsible for cytotoxic lymphocytes inhibition were identified that proves their impact on local immune dysfunction of nasal polyps [16].

So, the paranasal proper mucous plate, in patients suffering from chronic sinusitis with adenomatous polyps of abundant inflammatory cell infiltration consisting of various immunophenotype cells, proves the relapsing course of chronic inflammation, activation of immune destruction of bacterial antigens involving antibodies, CD8+ T-lymphocytes and macrophages, as well as activation of mucosa cells resistance to apoptotic death and their timely self-maintenance support.

Conclusions

1. In the patients with chronic maxillary sinusitis with paranasal adenomatous polyps, moderate or severe immunocyte infiltration of CD8+ T-killer cells, CD4+ T-helper cells, CD68+ macrophages, plasma cells, which sometimes formed follicular structures, were found in polyp stroma.

2. In the patients with chronic maxillary polyp sinusitis with mild or moderate immunocyte infiltration of paranasal sinus mucosa in polyp stroma, among immune cells the CD4+ T-lymphocytes occupied the most relative area, plasma cells – the least ($p < 0.001$).

3. In the patients with significant immunocellular infiltration and focal follicular structures of maxillary sinus mucosa, the relative area of CD4+ and CD8+ T-lymphocytes in immunocyte infiltrates of polyp stroma significantly exceeded the relative area of macrophages and plasma cells.

Further research prospects. The obtained data can be used in development the correction of immune-histological changes of maxillary sinus mucosa.

References

- Betlejewski, S., & Betlejewski, A. (2008) The influence of nasal flow aerodynamics on the nasal physiology. *Otolaryngol*, 62(3), 321–325. doi: 10.1016/S0030-6657(08)70263-4.
- Zavaliu, M. A., & Bezshapochny, S. D. (2010) Rezultaty kompleksnogo lecheniya bol'nykh s obostreniem khronicheskogo gnojnogo sinusita [Results of complex treatment for patients suffering from exacerbation of chronic purulent sinusitis]. *Zhurnal vushnykh, nosovykh i horlovykh khvorob*, 6, 16–21. [in Russian].
- Meusel, T., Negoias, S., Scheibe, M., & Hummel, T. (2010) Topographical differences in distribution and responsiveness of trigeminal sensitivity within the human nasal mucosa. *Pain*, 151(2), 516–521. doi: 10.1016/j.pain.2010.08.013.
- Ramadan, H. H., & Makary, C. A. (2014) Can computed tomography score predict outcome of adenoidectomy for chronic rhinosinusitis in children. *The American Journal of Rhinology & Allergy*, 28(1), 80–82. doi: 10.2500/ajra.2014.28.4004.
- Evcimik, M. F., Dogru, M., Cirik, A. A., & Nepesov, M. I. (2015) Adenoid hypertrophy in children with allergic disease and influential factors. *International Journal of Pediatric Otorhinolaryngology*, 79(5), 694–697. doi: 10.1016/j.ijporl.2015.02.017.
- Carvalho, F. G., Puppini-Rontani, R. M., Fúcio, S. B., & Negri, T. C.; Carlo, H. L., Garcia-Godoy, F. (2012) Analysis by confocal laser scanning microscopy of the MDPB bactericidal effect on *S. mutans* biofilm. *Journal of Applied Oral Science*, 20(5), 568–575. doi: 10.1590/S1678-77572012000500013.
- Pukhlik, S. M., & Buchatsky, M. S. (2013) Sovremennye metody vizualizatsii sostoyaniya okolonosovykh pazukh. Opyt ul'trazvukovoy diagnostiki [Modern methods of visualisation of paranasal sinuses. Experience of ultrasonic diagnostics]. *Rynolohiya*, 2, 58–64. [in Russian].
- Zakharova, H. P., & Il'inskaya, E. V. (2002) Kharakteristika ul'trastrukturnykh osobennostej slizistoy obolochki verkhnechelyustnykh pazukh pri khronicheskikh rinosinitakh [Characteristic ultrastructural features of the mucosa of the maxillary sinus in chronic rhinosinitis]. *Novosti otorinolaringologii*, 3, 25–31. [in Russian].
- Tan, B. K., Li, Q.-Zh., Suh, L., Kato, A., Conley, D. B., Chandra, R. K., et al. (2011). Evidence for intranasal anti-nuclear autoantibodies in Chronic Rhinosinusitis with Nasal Polyps. *J Allergy Clin Immunol*, 128(6), 1198–1206. doi: 10.1016/j.jaci.2011.08.037.
- Hulse, K. E., Stevens, W. W., Tan, B. K., & Schleimer, R. P. (2015). Pathogenesis of nasal polyposis. *Clin Exp Allergy*, 45(2), 328–346. doi: 10.1111/cea.12472.
- Dutsch-Wicherek, M., Tomaszewska, R., Lazar, A., Stręk, P., Wicherek, L., Piekutowski, K., & Józwicki, W. (2010). The evaluation of metallo-thionein expression in nasal polyps with respect to immune cell presence and activity. *BMC Immunol.*, 11, 10. doi: 10.1186/1471-2172-11-10.
- Claeys, S., De Belder, T., Holtappels, G., Gevaert, P., Verhasselt, B., Van Cauwenberge, P., Bachert, C. (2004). Macrophage mannose receptor in chronic sinus disease. *Allergy*; 59, 606–612. doi: 10.1111/j.1398-9995.2004.00471.x.
- Könnecke, M., Bösccke, R., Waldmann, A., Bruchhage, K.-L., Linke, R., Pries, R., et al. (2014). Immune Imbalance in Nasal Polyps of Caucasian Chronic Rhinosinusitis Patients Is Associated with a Downregulation of E-Selectin. *J Immunol Res.*, 2014, 959854. doi: 10.1155/2014/959854.
- Fokkens, W., Lund, V., & Mullol, J. (2007). European Position Paper on Rhinosinusitis and Nasal Polyps Group. *Rhino*, 20, 1–136.
- Gevaert, P., Holtappels, G., Johansson, S.G.O., Cuvelier, C., Van Cauwenberge, P., & Bachert, C. (2005). Organisation of secondary lymphoid tissue and local IgE formation to *Staphylococcus aureus* enterotoxins in nasal polyps. *Allergy*, 60(1), 71–79. doi: 10.1111/j.1398-9995.2004.00621.x.
- Dutsch-Wicherek, M., Tomaszewska, R., Stręk, P., Wicherek, L., & Skladzien, J. (2006). The analysis of RCAS1 and DFF-45 expression in nasal polyps with respect to immune cells infiltration. *BMC Immunol.*, 21, 7–4. doi: 10.1186/1471-2172-7-4.

Information about authors:

Andreychyn Yu. M., MD, PhD, DSc, Associate Professor of the Department of Otorhinolaryngology, Ophthalmology and Neurosurgery of the State Institution of Higher Education "Ivan Horbachevsky Ternopil State Medical University of the Ministry of Health of Ukraine", Ukraine.
Kovalenko I. S., MD, PhD, Assistant of the Department of Pathological Anatomy and Forensic Medicine, Zaporizhzhia State Medical University, Ukraine.

Відомості про авторів:

Андрейчин Ю. М., д-р мед. наук, доцент каф. отоларингології, офтальмології та нейрохірургії, ДВНЗ «Тернопільський державний медичний університет імені І. Я. Горбачевського», Україна.
Коваленко І. С., канд. мед. наук, асистент каф. патологічної анатомії та судової медицини, Запорізький державний медичний університет. Україна.

Сведения об авторах:

Андрейчин Ю. М., д-р мед. наук, доцент каф. отоларингологии, офтальмологии и нейрохирургии, ГБУЗ «Тернопольский государственный медицинский университет имени И. Я. Горбачевского», Украина.
Коваленко И. С., канд. мед. наук, ассистент каф. патологической анатомии и судебной медицины, Запорожский государственный медицинский университет, Украина.

Конфлікт інтересів: відсутній.

Conflicts of interest: authors have no conflict of interest to declare.

Надійшло до редакції / Received: 14.02.2017

Після доопрацювання / Revised: 24.02.2017

Прийнято до друку / Accepted: 02.03.2017