

MINISTRY OF HEALTHCARE OF UKRAINE
ZAPORIZHZHYA STATE MEDICAL UNIVERSITY

OPHTHALMOLOGY DEPARTMENT

Lens Diseases

Tutorial

for the 4th year medical faculty students and residents
in “Ophthalmology” and “General medicine” specialties

Zaporizhzhya

2017

UDC 617.7
BBC 56.7
B 55

*Ratified on meeting of the Central methodical committee
of Zaporizhzhia State Medical University
(protocol N ___ from _____)
and it is recommended for the use in educational process for foreign students.*

Authors:

Bezugly M., MD, PhD

Zavgorodnya N., Professor, MD, PhD

Bezugly M.

B 55 Lens Diseases : tutorial for the 4th year medical faculty students and residents in “Ophthalmology” and “General medicine” specialties. – Zaporizhzhya, 2017. – 64 p.

The tutorial "Lens Diseases" was compiled according to the materials developed by the staff of the Ophthalmology Department in Zaporizhzhia State Medical University according to “Ophthalmology” Working Program for 4th year students of Medical Faculty. The authors considered modern requirements for teaching and control of theoretical knowledge and practical skills acquisition concerning the module system. The materials of the Tutorial are the guidelines for students’ practical classes in Ophthalmology.

UDC 617.7
BBC 56.7

Topic "Lens Diseases "

1. Topicality

Diseases of the lens, and cataracts in particular, are the most often reason for treatable blindness in the world. Beside that, majority of them connected with severe refractive problems which result in pure vision. Thus, making up the timely diagnosis, based on deep understanding of etiology, pathogenesis, symptoms and signs, as well as proper treatment strategy development, are very important for low vision and blindness prevention. The Tutorial contains materials dedicated to the questions listed above which makes it actual for medical students.

2. Educational goals of the practical class:

a) Student must know ($\alpha = \text{II}$):

- etiopathogenesis of the eye affection in lens diseases
- clinical characteristics of the lens diseases' course

b) Student must be able to ($\alpha = \text{III}$)

- get and assess patient's complains and anamnesis, provide ophthalmological examinations;
- determine necessary examinations and their sequence, and estimate their results;
- identify the lens diseases' symptoms
- emphasize clinical syndromes
- interpret the results of instrumental and laboratorial investigations and make primary diagnosis;
- make differential diagnosis of affliction of the eye in case of lens diseases, make a final diagnosis
- prescribe medical or surgical treatment.

3. Pedagogical goals: ($\alpha = \text{II}$)

- Student must know scientists, who provided investigations in diagnostic, treatment and prevention of the lens diseases
- Deontological aspects of patients with the lens diseases treatment

4. Plan and structure of the practical class

No	Steps	Educational goals at learning levels	Methods of teaching and control	Materials of methodical support	Timing
I. Preparatory stage					
	Organizational actions				5 min
	Topicality Defining				5 min
	Statement of educational goals				5 min
	Entrance check-up of the knowledge: -etiology -clinics -diagnostics -treatment	I II - III II - III II - III	According to the level, but different, may be combined	Questions of 1 st and 2 nd level, 2 nd level tests, 3 rd level tasks	
II. Main step					
	Professional skills forming	III	Practical training, situational tasks	Professional algorithm of examination	

III. Final step					
	Professional skills' level control	III	Individual control of the practical skills. Untypical tusks solving. Analysis of laboratorial and instrumental investigations	3 rd level tests, 3 rd level tasks	
	Summing up the topic				
	Home assignment		Approximate card point 5.4.		

5. Materials for self-study work

5.1 Basic knowledge and skills required for topic studying

Disciplines	To know	To be able to
Anatomy, histology and physiology	Anatomy and histology, methods of the lens examination	evaluate the lens structure in normal conditions and pathology
Pathological physiology	Signs of dystrophic changes in the lens	Define pathogenesis of clinical syndromes
Pathological anatomy	The description of dystrophic processes in the lens	Define pathogenesis of clinical syndromes
Laboratory investigations	Algorithms of laboratorial investigations	Examine and interpret results of laboratorial and instrumental investigations
Clinical pharmacology	Mechanism of drugs' effects, their compatibility, dosage, route of administration	Define therapeutic indications, calculate doses, and write recipes. Develop the complications prevention plan

5.2 Content of the topic (theoretical literature review)

The lens is a biconvex and transparent organ, held in its position behind the iris by the suspensory ligaments (zonules). The zonules attach the equator of the lens to the ciliary body. Diseases may affect the position, size, shape, and structure of the lens. Abnormalities of lens position, size, and shape may lead to refractive errors of the eye, impairing patient's vision and increasing optical aberrations. Beside this, such kinds of anomalies are often associated with lens opacities.

Anomalies of Lens Position

Ectopia Lentis

Definition. Ectopia lentis is a displacement of the lens out of its normal anatomic position which may be partial (subluxation, displacement) or total (luxation, dislocation). Subluxated lens, although being displaced, still remains in the pupillary area due to rupture or extension of the part of Zinn ligaments. Complete dislocation of the lens, which is a result of total ligament rupture, is quite a rare condition and appears in two variants – dislocation into the anterior chamber and into the vitreous. In the latter case the lens cannot be seen in the pupillary area (this condition is called *aphakia*).

Etiology of ectopia lentis includes two groups of causes: hereditary and acquired.

Hereditary ectopia may be seen in cases of:

- familial ectopia lentis (simple) – isolated and monosymptomatic, inherited as an autosomal dominant trait,
- Marfan's syndrome,
- Weill–Marchesani syndrome,
- homocystinuria (metabolic disease).

Acquired causes include:

- trauma (the most frequent cause),
- pseudoexfoliation (in aged patients),
- ciliary body tumor,
- buphthalmos.

Signs and Symptoms. Monocular diplopia, impairment of vision due to refraction changes (severe astigmatism, high hyperopia).

General ophthalmic findings:

- *for subluxation:*
 - iridodonesis (tremulous iris);
 - phacodonesis (tremulous lens on eye movement);
 - the anterior chamber becomes deep or irregular;
 - irregular pupil (sometimes);
 - marked displacement of the lens equator can be seen in the pupillary area (Fig. 1);

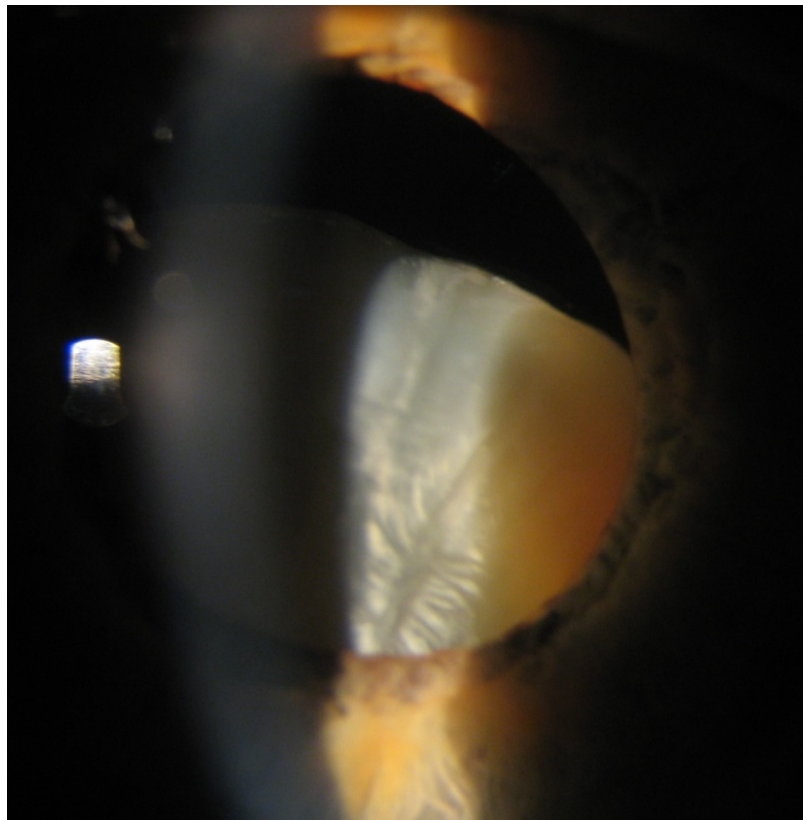


Fig. 1. Inferior displacement of opaque (cataractous) lens due to contusion. The superior part of the equator is seen in the pupil

- *for anterior displacement:*

- pupillary block with angle-closure glaucoma.

Marfan's syndrome is an autosomal dominant disorder of collagen synthesis characterized by skeletal, cardiac, and ocular findings. *Systemic findings* include tall, thin stature, mitral valve prolapse, dilated aortic root and aortic dissection, arachnodactyly, hyperextensible joints. *Ophthalmic findings* are bilateral ectopia lentis (mainly superotemporal), myopia, increased incidence of retinal detachment (Fig. 2).

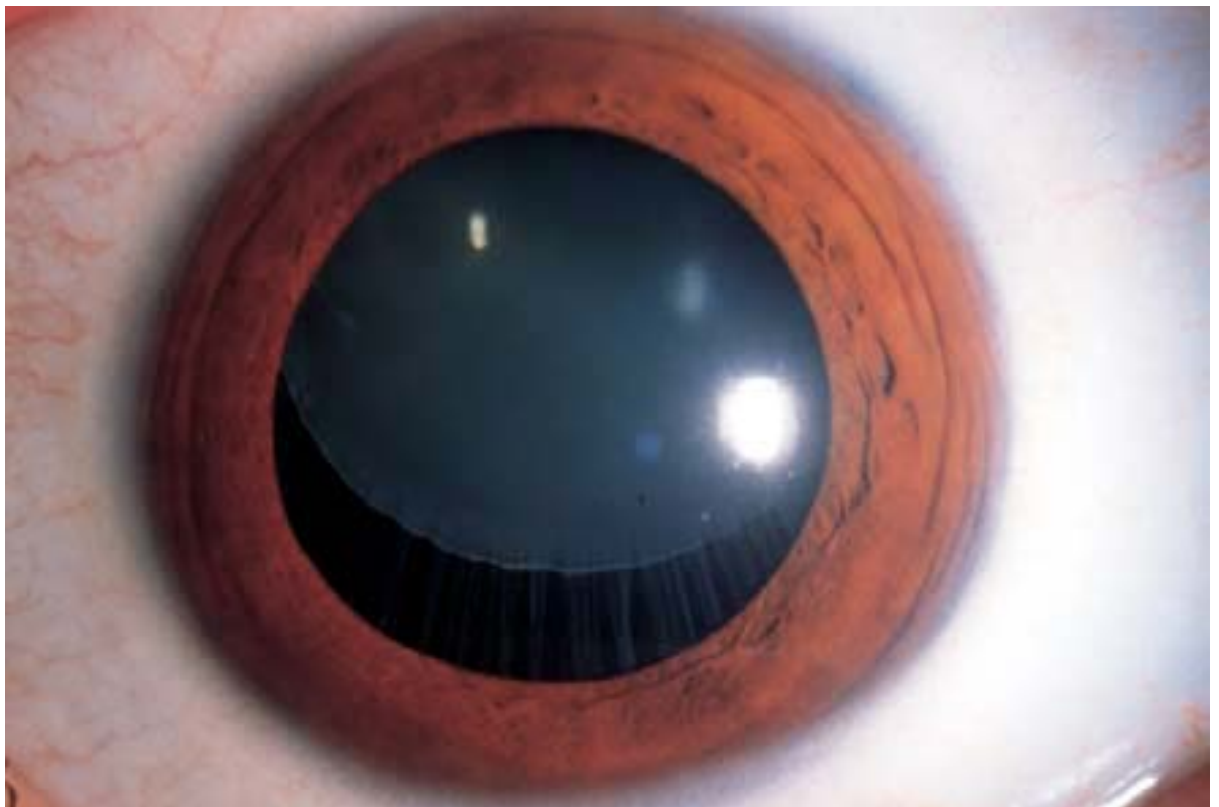


Fig. 2. Superior lens subluxation in a Marfan's syndrome patient. The capsular lens zonules remain stretched but intact for the most part (from *Ophthalmology. A short Textbook* / G. K. Lang, M.D. – Thieme, Stuttgart–New York, 2000)

Weill–Marchesani syndrome is an autosomal recessive condition characterized by short stature, small hands and feet (brachydactylia). *Ophthalmic findings*: the lens is abnormally round and often very small (microspherophakia); it is usually eccentric and displaced inferiorly.

Homocystinuria is an autosomal recessive systemic disorder of amino acid metabolism resulting in lenticular zonular fragility, seizures, and an increased risk for thromboembolic events. *Systemic findings* are characterized by oligophrenia, osteoporosis, and skeletal deformities. *Ophthalmic findings*: lens displacement is usually medial and inferior; torn zonule fibers appear as a “permanent wave” on the lens.

The treatment of lens position anomalies includes:

- therapeutic options – optic correction of refractive errors with spectacles or contact lenses;
- surgical options – lensectomy with intraocular lens (IOL) implantation in cases of optical correction inability or presence of attendant cataracts.

Aphakia is the condition in which the crystalline lens is out of its normal position.

How aphakia can be produced

1. By operative measures like extra-capsular, intra-capsular extraction of lens or phakoemulsification.
2. By trauma – usually contusion injury, when the lens may be dislocated in the vitreous.
3. By couching. This is an operation for cataract in which the lens is pushed out of the pupil downwards and backwards into the jelly-like vitreous humour by a small knife inserted through the edge of the cornea. It was widely employed in ancient Hindu civilizations and has been practiced ever since. Its sole advantage is speed of performance, but modern developments in surgery and anaesthesia leave little place for it today.
4. As a developmental anomaly – Congenital absence of the lens.

Symptoms of aphakia

There is marked dimness of vision, both for the distance and for the near, due to development of acquired hyperopia and due to complete loss of accommodation.

Clinical signs of aphakia

1. Deep anterior chamber.
2. Tremulous of iris known as iridodonesis.
3. Jet-black pupil provided there is no after-cataract.
4. Absence of 3rd and 4th Purkinje`s images.
5. Lineal scar mark at the upper half of the limbus, in cases where extraction of the lens is the cause of aphakia.

Changes occurring in an aphakic eye

1. Acquired high hyperopia. The total dioptric power of a normal eye is about +58 to +60D, of which cornea contributes +42 to +43D and the lens in situ contributes +15 to +18D. Thus when the lens is removed, the dioptric power of the eye decreases and so the eye becomes hyperopic.

2. Acquired astigmatism in cases where aphakia is due to extraction of the lens. The astigmatism is against the rule, i.e., the vertical curvature of the cornea is flatter than the horizontal. This is caused by the contraction of the limbal scar.

3. Complete loss of accommodation, as there is no lens.

4. The anterior and the posterior focal lengths of the eyeball increase than normal. Thus the anterior and the posterior focal lengths of the aphakic eye become 23,3mm and 31 mm, as compared to 15mm and 24 mm in the normal eye approximately from the cornea.

5. The retinal image of an object in an aphakic eye, even after correction with glasses, becomes bigger by 25 – 30 percent than that in the normal eye. So if one eye is aphakic and the other eye is normal, binocular vision is not possible even after using correct aphakic glasses, due to the disparity of image size. So if aphakic glasses are prescribed when the other eye is normal, there is diplopia.

Sometimes an aphakic eye sees objects tinged with red or blue colour, due to increased entry of infra-red or ultra-violet rays into the eye, which are normally absorbed by the lens.

Anomalies of Lens Size and Shape

Anomalies of lens size and shape are very rare congenital conditions connected mostly with eye malformation. To this group of diseases we refer the following disorders:

- congenital aphakia,
- lenticonus,
- lentiglobus,
- lens coloboma,
- microspherophakia,
- remnants of the fetal vasculature system of the lens.

Congenital aphakia is a very rare anomaly characterized by total absence of the lens.

Lenticonus is a localized cone-shaped deformation of the anterior (anterior lenticonus) or posterior (posterior lenticonus) lens surface. Posterior lenticonus is more common than the anterior one and is usually unilateral. Anterior lenticonus, which is often bilateral, may be associated with Alport syndrome (kidney disease accompanied by sensorineural hearing loss and lens shape anomalies) (Fig. 3).

Lentiglobus is rare, usually unilateral, generalized hemispherical deformation of the lens, which may be associated with posterior polar lens opacity. *The symptoms* of lenticonus and lentiglobus include reduced visual acuity due to myopic refraction.

Lens coloboma is a wedge-shaped defect or indentation of the lens periphery that occurs as an isolated anomaly typically located inferiorly and may be associated with colobomas of the uveal tissue.

Microspherophakia is a developmental abnormality in which the lens is small in diameter and spherical. The entire lens equator can be seen with the slit lamp when the pupil is dilated. The spherical shape of the lens results in increased refractive

power and appearance of high myopia. Microspherophakia is most often seen as a part of Weill–Marchesani syndrome as well as an isolated hereditary abnormality or, occasionally, in association with Peters anomaly, Marfan’s syndrome, Alport syndrome, Lowe syndrome, or congenital rubella.

Mittendorf dot is a remnant of the posterior pupillary membrane of the tunica vasculosa lentis. It is a common anomaly observed in many healthy eyes as a small, dense white spot generally located inferonasally to the posterior pole of the lens. Sometimes a Mittendorf dot is associated with a fibrous remnant of the hyaloid artery projecting into the vitreous. This anomaly usually does not require any treatment.

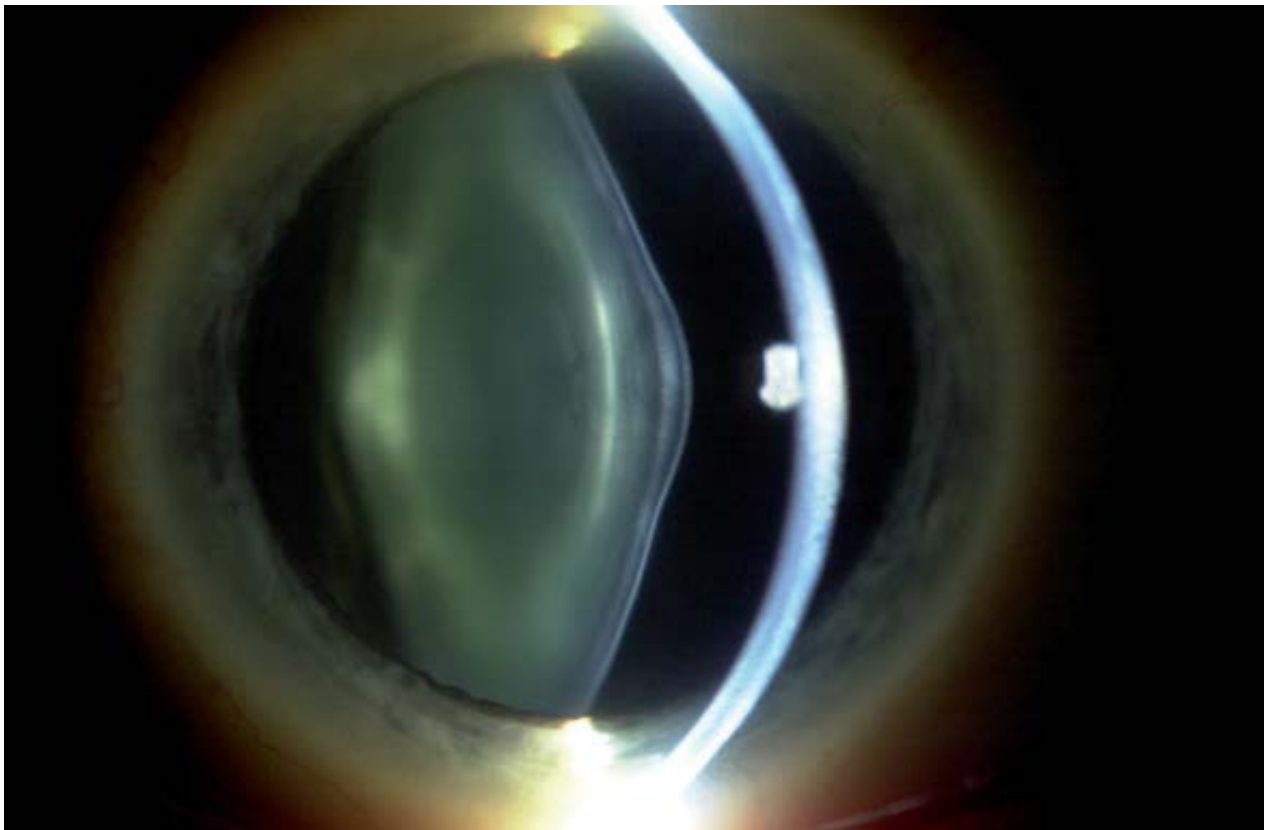


Fig. 3. Anterior and posterior lenticonus (from *Rapid Diagnoses in Ophthalmology: Lens and Glaucoma* / J. Schuman, V. Christopoulos, D. Dhaliwal et al. – MOSBY, 2008)

Treatment options in case of these anomalies depend on the degree of vision impairment and abilities of optic correction of refractive errors. Surgical treatment is

indicated in cases of ineffective optical correction and developed opacification of the media. However, making the choice, the doctor should always consider the risks of further surgical complications.

Cataracts

Cataract is the presence of any persistent opacity in the lens. This disease is the most common cause of treatable blindness in the world.

Classification

Despite numerous classifications of cataracts, there is still no one that would satisfy ophthalmologists completely. Usually cataracts are classified according to following criteria: time of onset; morphology (opacity localization); etiology and stages of maturation.

By the *time of onset* all cataracts are divided into:

- congenital and juvenile,
- acquired.

Congenital cataracts are detected at birth; juvenile cataracts appear during the first 12 years of life. Acquired cataracts may be detected in adulthood.

By *morphology* acquired and congenital cataracts are divided in different ways.

The following morphological types of *age-related cataracts* are distinguished:

- cortical,
- nuclear,
- posterior subcapsular,
- mixed.

Morphological changes in *congenital and juvenile cataracts* are classified as follows:

I. Total (complete) – the lens is completely opaque or hazy at birth.

II. Partial (incomplete) – opacities localized in a definite part of the lens:

A. Anterior and posterior polar cataracts.

B. Zonular cataracts:

1. Lamellar.
2. Sutural (stellate).
3. Nuclear.
4. Coronary.
5. Blue dot (cerulean).

C. Membranous cataracts.

Etiological classification of acquired cataracts:

- age-related (senile) cataract,
- traumatic cataracts (contusion, penetrating injury, infrared radiation, alkali burn),
- metabolic cataracts (diabetes mellitus, Wilson disease),
- complicated cataracts (chronic anterior uveitis, retinal vasculitis, retinitis pigmentosa),
- toxic cataracts:
 - corticosteroid-induced,
 - miotic-induced,
 - copper- and iron-induced,
- radiation cataract,
- electrical cataract,
- postoperative cataracts (following vitrectomy or glaucoma penetrating surgery),
- cataracts associated with systemic diseases (atopic dermatitis, myotonic dystrophy, tetany, Fabry's disease),
- cataracts associated with miscellaneous syndromes (Down's syndrome, Lowe's syndrome).

By the stage of maturation senile cataracts are usually grading into:

- incipient cataract,
- immature cataract,

- mature cataract,
- hypermature cataract.

Cataract grading systems have developed significantly during the last decades. They transformed from simple assessment by direct ophthalmoscopy to more up-to-date methods such as the Lens Opacities Classification System III (LOCS III) (1993) or Age-Related Eye Diseases Study (AREDS) (2008), where slit-lamp examination is compared to a standard set of photographs (special sets for nuclear, cortical, and posterior subcapsular) (Fig. 4, 5).

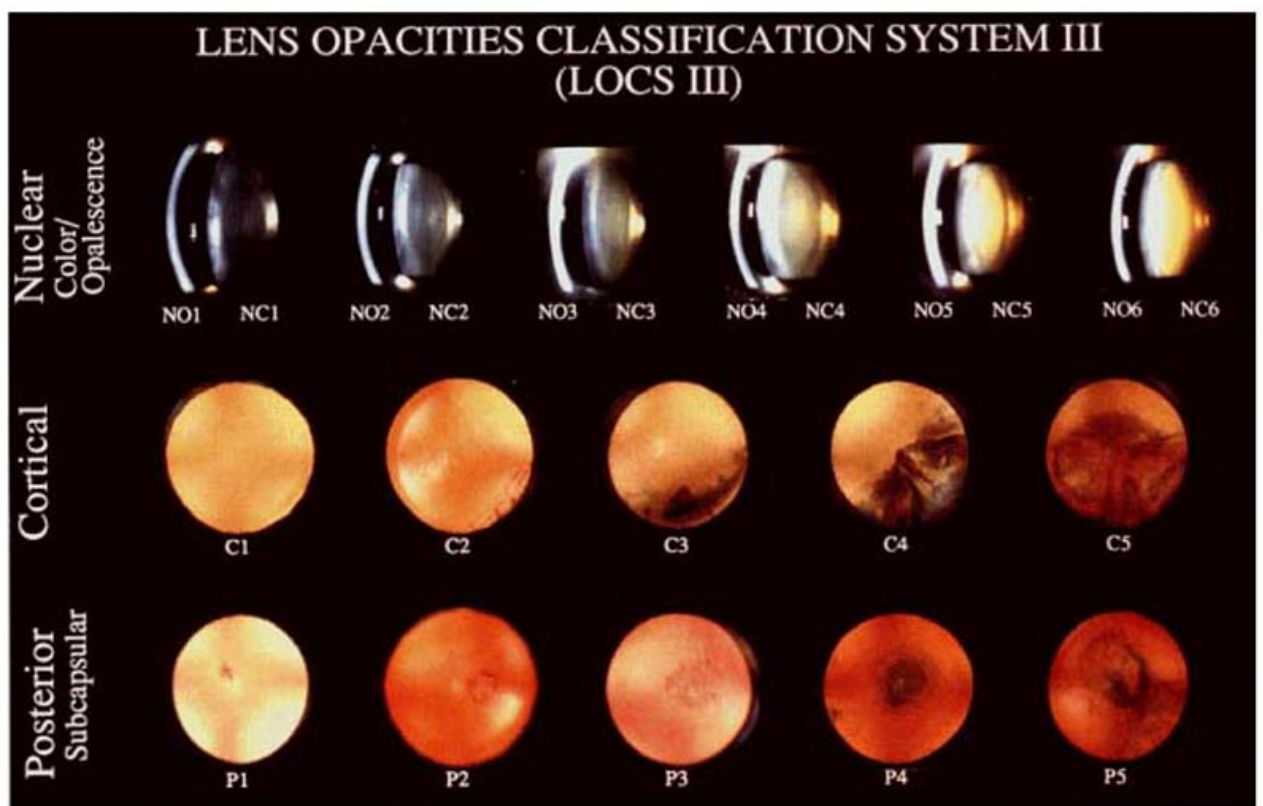


Fig. 4. Lens Opacities Classification System III (from *Arch Ophthalmol* – Vol. 111 – June, 1993)

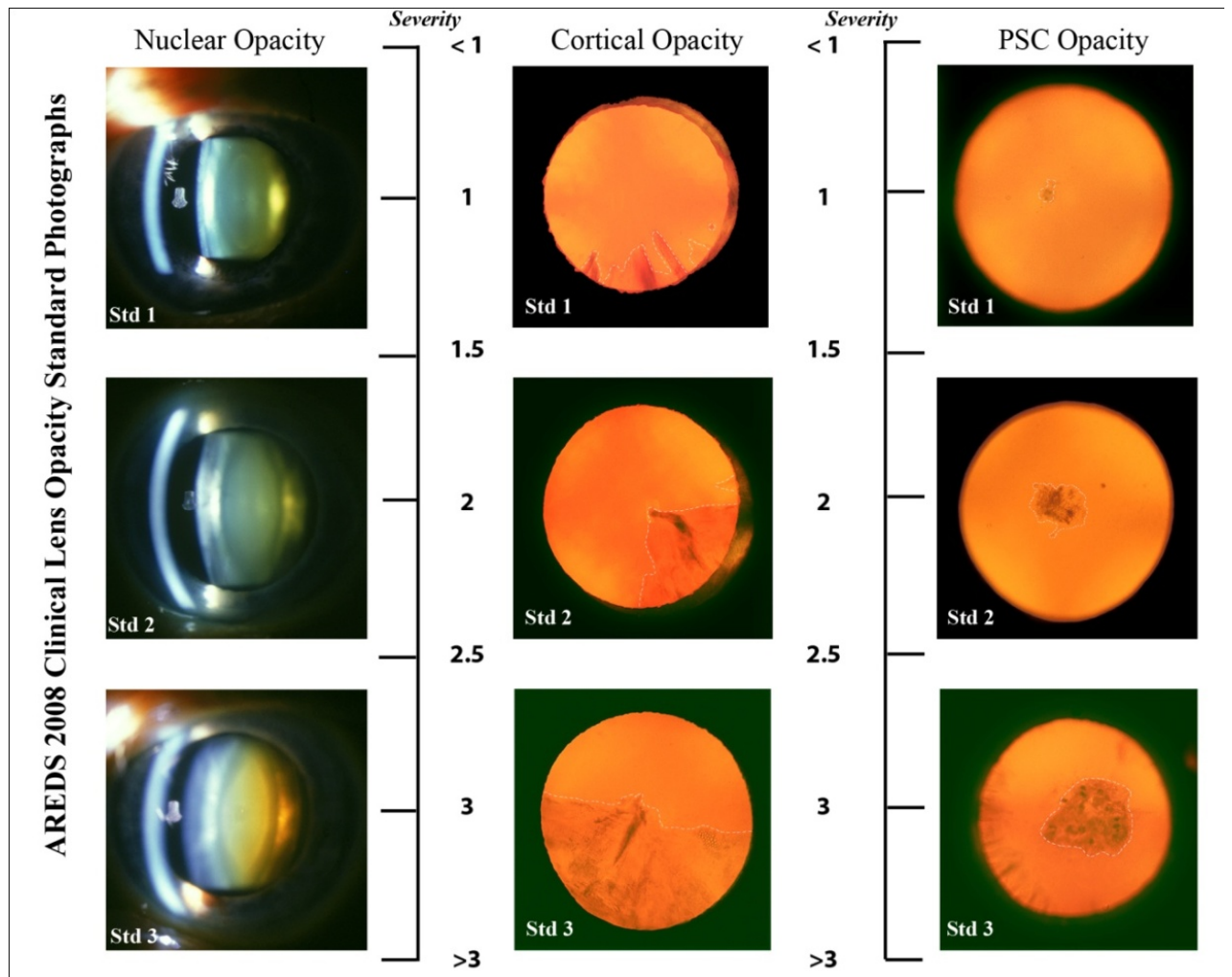


Fig. 5. The cataract grading system AREDS (2008)

Congenital Cataracts

Congenital cataracts occur due to any disturbance in the process of normal growth of the lens. Congenital and developmental opacities assume very variable appearance and minimal opacities (without visual disturbance); they are common in normal population. Otherwise, significant opacification of the central areas of the lens or total cataracts may lead to great vision problems.

Etiology. Among numerous predisposing factors in congenital cataract development, the following play the main role:

I. Heredity.

Genetically-determined cataract is due to chromosomal aberrations. About one-third of all congenital cataracts are hereditary – inherited as an autosomal dominant trait: cataracta pulverulenta (nuclear), zonular cataract (also occurs as non-familial), coronary cataract and total soft cataract (may also occur due to rubella).

II. Maternal factors.

1. Malnutrition during pregnancy (non-familial zonular cataract).

2. Infections. Maternal infections like rubella are associated with cataract in 50 % cases as well as mumps, toxoplasmosis, hepatitis, CMV-infection.

3. Drug ingestion. Congenital cataracts have also been reported in children of mothers who have taken certain drugs during pregnancy (e.g., thalidomide, corticosteroids).

4. Radiation. Maternal exposure to radiation during pregnancy.

III. Fetal or infantile factors.

1. Deficient oxygenation (anoxia) owing to placental hemorrhage.

2. Metabolic disorders of the fetus or infant such as galactosemia, galactokinase deficiency, and neonatal hypoglycemia.

3. Cataracts associated with other congenital anomalies, e.g., as seen in Lowe's syndrome, dystrophic myotony, etc.

4. Birth trauma.

5. Malnutrition in early infancy.

IV. Idiopathic. About 50 % cases are sporadic and of unknown etiology.

Symptoms and signs. As has been mentioned above, the degree of vision impairment in congenital cataracts varies considerably from total absence of any vision problems to loss of vision up to light perception and depends mostly on the localization and density of opacities in the lens.

In case of total and nuclear cataracts, especially if they are bilateral, visual acuity is decreased significantly. But even if lens opacities are not so severe, mothers may mention changes in their baby's behavior and appearance:

- an opaque dot or a disk can be seen in the pupillary area; the pupil may be totally white (the latter is called leukocoria);

- strabismus and nystagmus may develop;
- at two months of age the baby doesn't fix his/her gaze at relatives' faces or bright toys, doesn't watch or follow objects;
- in case of monocular vision loss the baby constantly turns to the same side while watching a toy.

In *total* cataracts all portions of the lens are completely opaque.

Anterior and posterior polar cataracts involve the lens capsule in the anterior or posterior pole of the lens. They are sometimes associated with a localized anatomical abnormality in the region (i.e. posterior polar cataracts are commonly associated with posterior lenticonus). They may cause severe visual symptoms, however, they are usually stable, and patients may do well with conservative measures. The familial type is bilateral and inherited as an autosomal-dominant trait.

In *zonular cataracts* only one region or zone of the lens is opaque. They may be stationary or progressive. Subtypes of zonular cataracts are: lamellar, sutural (stellate), nuclear, coronary, blue dot (cerulean) cataract.

Lamellar cataract is the most common type of congenital cataract. Such cases are usually bilateral and symmetric, and the density of opacification may vary considerably. Less opaque lamellar cataracts may be compatible with good vision and require minimal medical intervention (e.g., optical correction, therapeutic mydriasis).

These cataracts may be inherited as an autosomal-dominant trait, but in some cases they may be a result of some intrauterine toxic agent, affecting only the layer of cells developing at the time of fetal exposure (Fig. 6).

Sutural or stellate cataracts affect the region of the sutures. They may be Y-shaped if the cataract occurs at the intrauterine stage of development as the sutures have this configuration during this period. Anterior sutural cataracts are Y-shaped; posterior sutural cataracts are shaped like an inverted Y. Sutural cataracts that develop later on have a more stellate shape.

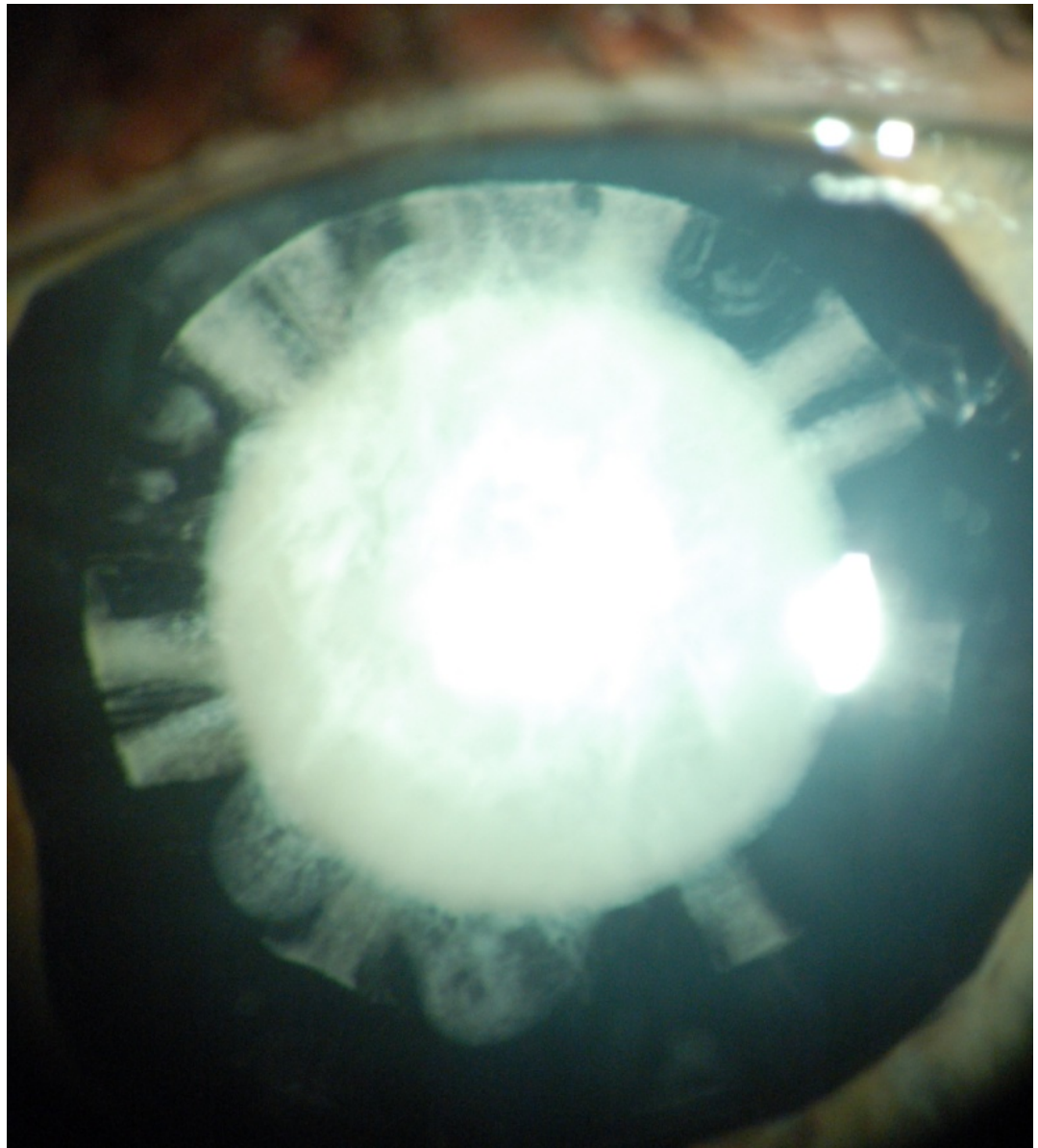

Fig. 6. Lamellar cataract

Nuclear cataracts are usually bilateral and involve the fetal or embryonal nucleus. They may be inherited as an autosomal-dominant, autosomal-recessive or X-linked trait and are associated with infections (e.g., rubella).

Coronary cataracts are radial, club-shaped discrete opacities located in the cortex. The term “coronary” means that their appearance is like the top of the crown. Because of their peripheral location, they do not decrease visual acuity. Coronary cataracts are dominantly inherited and have been described in cases of Down’s syndrome and myotonic dystrophy.

Blue dot (cerulean) cataracts consist of small, discrete opacities that have a distinct bluish hue. These opacities are located in the cortex, are non-progressive, and do not cause visual symptoms. They may be present together with other congenital cataracts (Fig. 7).

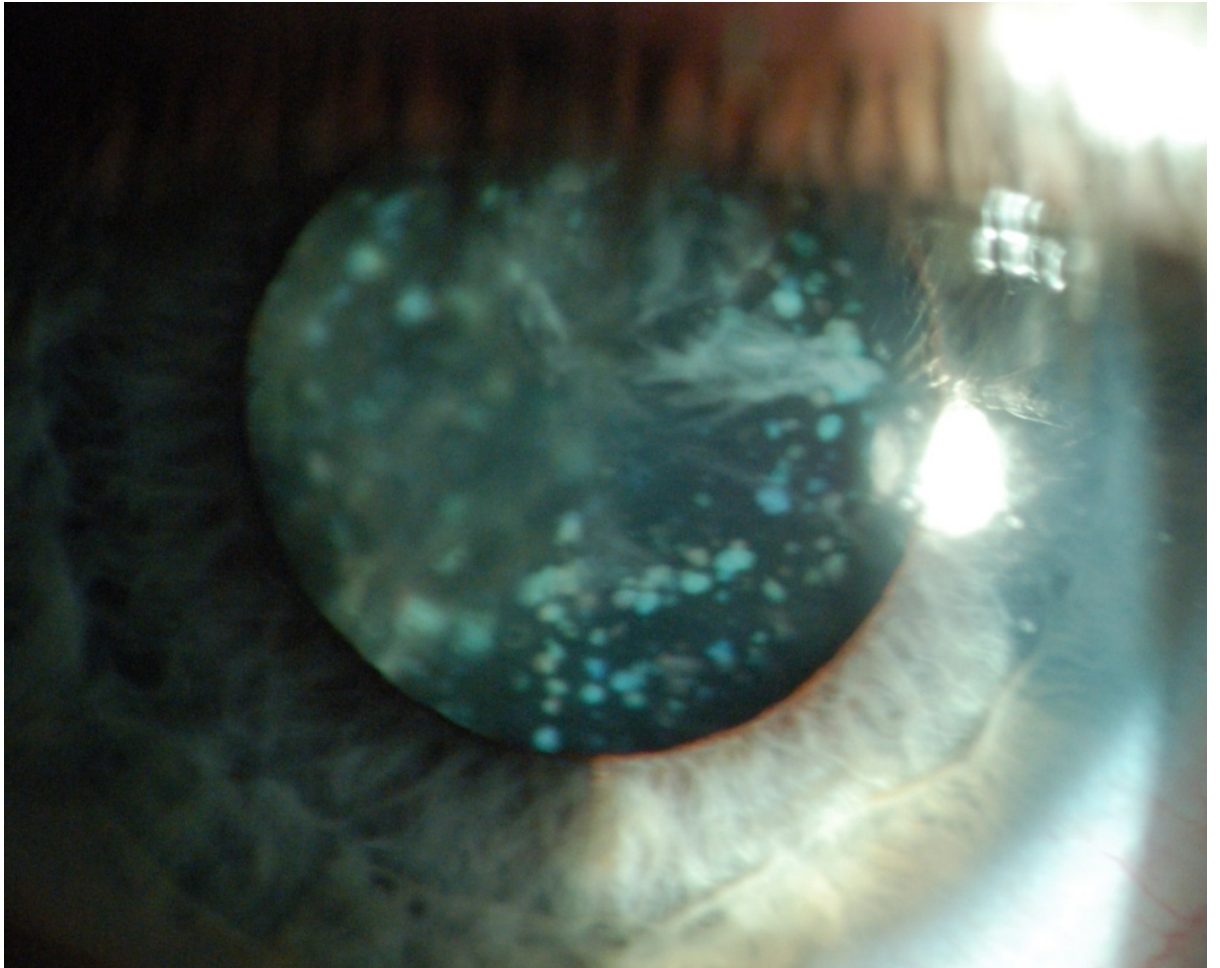


Fig. 7. Blue dot cataract associated with cortical cataract

Membranous cataracts are thin but dense and contain fibrous tissue. They may occur when lens proteins are reabsorbed (e.g., traumatized lens), such that the anterior and posterior lens capsules fuse producing a dense membrane.

Examination methods in babies and children include visual acuity testing, focal and slit-lamp ocular examination, and ophthalmoscopy. In some cases methods like

fixation reflex, visually evoked response, and optic-kinetic nystagmus (OKN) may be amended. The aims of thorough examination are working out prognostic factors, indications, and timing of surgery.

Differential diagnosis. Congenital cataracts with leukocoria are to be differentiated from various conditions presenting with this sign such as retinoblastoma, retinopathy of prematurity, persistent hyperplastic primary vitreous (PHPV), etc.

Treatment. Surgical treatment is the only effective method for cataract treatment. In pediatric cataracts the decision about surgery should be developed basing on thorough analysis of many factors such as: current visual functions, density of the cataract, unilateral or bilateral cataract, time of onset, associated ocular and systemic defects, etc. General approach to pediatric cataract surgery should be as follows:

Partial cataracts and small central cataracts, which are visually insignificant and non-progressive, can safely be observed or treated non-surgically with optical correction (if required).

Bilateral dense cataracts should be removed early (within 6 weeks of birth) to prevent amblyopia development.

Unilateral dense cataracts should be removed as early as possible after birth. However, it must be remembered that visual prognosis in these cases is poor even after successful surgery because proper correction of aphakia and prevention of amblyopia in infants is an extremely hard task considering further growth of the eyeball.

Surgical procedures include phacoemulsification or extracapsular cataract extraction (details of these are described further in the chapter). Post-operative aphakia should be corrected with intraocular lenses (IOL), in some cases (elder children) it may also be corrected with contact lenses or spectacles.

Acquired Cataracts

In acquired cataracts opacification of the lens fibers occurs under the influence of various causative factors like aging, trauma, metabolic disorders, different physical (radiation, electricity) and toxic agents, etc. The most common type of acquired cataract, which takes about 90 % of all cases, is age-related (senile) cataract.

Etiology of senile cataract still remains unknown, but several predisposing factors for lens opacity development shown in multiple studies are the following: heredity, ultraviolet irradiation from sunlight, dietary factors (deficiency of certain proteins, amino acids, vitamins), dehydrational crisis (due to diarrhea, cholera), smoking.

Symptoms and signs. The clinical picture of senile cataract is determined by its morphological type (cortical, nuclear or subcapsular) and degree of maturation but the main complaint of such patients is gradual decrease of vision which they have observed during several months to several years and even decades.

Nuclear cataracts tend to progress slowly. Usually they develop bilaterally but asymmetrically. Impairment of distant vision is more marked than near vision, at early stages refraction changes are known as myopic shift (lenticular myopia), so presbyopic patients can read without spectacles because of some improvement of near vision. Another symptoms of nuclear cataract may be monocular diplopia, disorders in color perception (especially for blue color).

Cortical cataracts in contrast to nuclear cataracts progress relatively rapidly, are usually bilateral, and often asymmetric. Their effect on the visual function varies greatly depending on the location of opacification in relation to the visual axis. At the daytime, when the pupil is constricted, patients report better vision. A common symptom of cortical cataracts is glare from intense focal light sources, such as car headlights. Monocular diplopia may also be present. At early stages of cataract the patients may perceive colored halos around light sources.

Posterior subcapsular cataracts are located in the posterior cortical layer and are usually axial. The patient often complains of glare and poor vision under bright lighting conditions because opacity obscures more of the pupillary aperture when miosis is induced by bright lights, accommodation, or miotics. Near visual acuity

tends to be reduced more than distance visual acuity. Some patients experience monocular diplopia.

Objective signs in cataracts vary according to cataract maturation.

1. Incipient cataracts. The first signs of cortical cataract formation visible with the slit-lamp biomicroscope are vacuoles in the anterior or posterior cortex (Fig. 8).

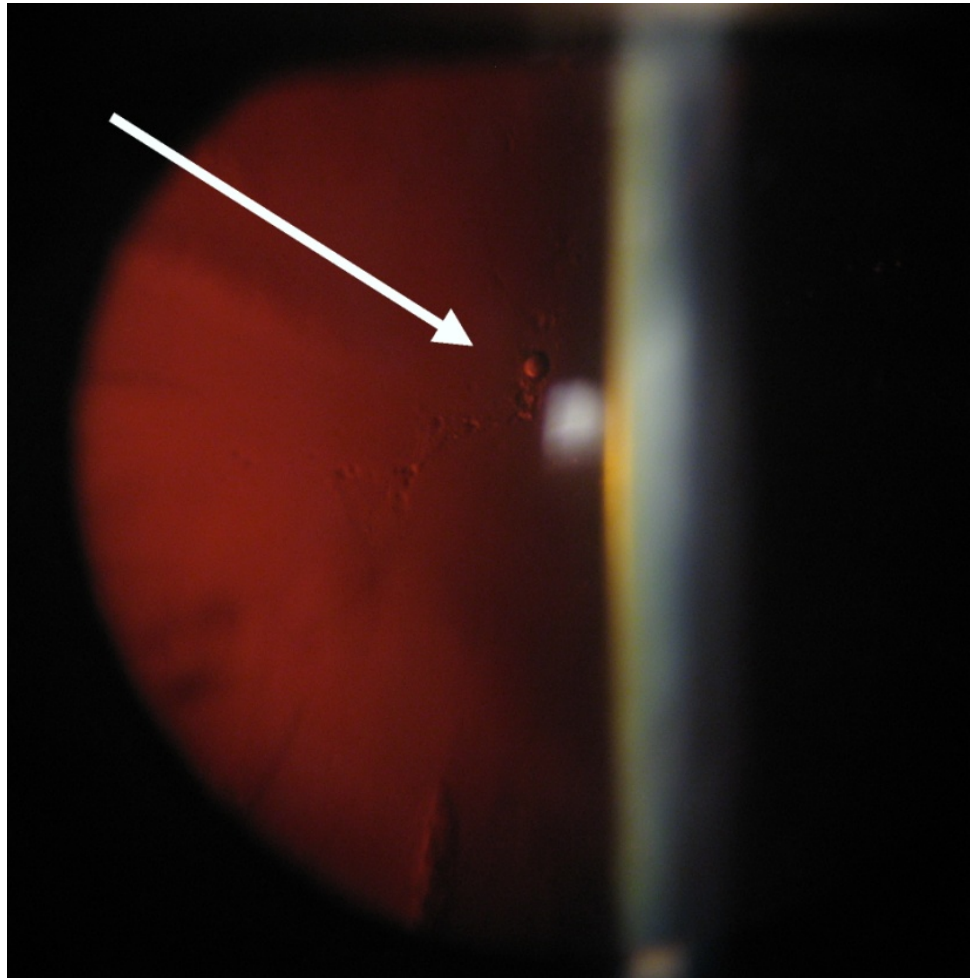


Fig. 8. Vacuoles in the posterior cortex (shown with an arrow)

Wedge-shaped opacities (often called cortical spokes or cuneiform opacities) form near the periphery of the lens, with the pointed end of the opacities oriented toward the center. They are first seen in the lower nasal quadrant. These opacities are present both in the anterior and posterior cortex. On oblique illumination these present a typical radial spoke-like pattern of grayish white opacities. On distant direct ophthalmoscopy, these opacities appear as dark lines against the red fundal reflex

(Fig. 9). The nucleus at this stage shows signs of sclerosis and initial opacities. VA at this stage is normal or mildly decreased (1.0–0.8)

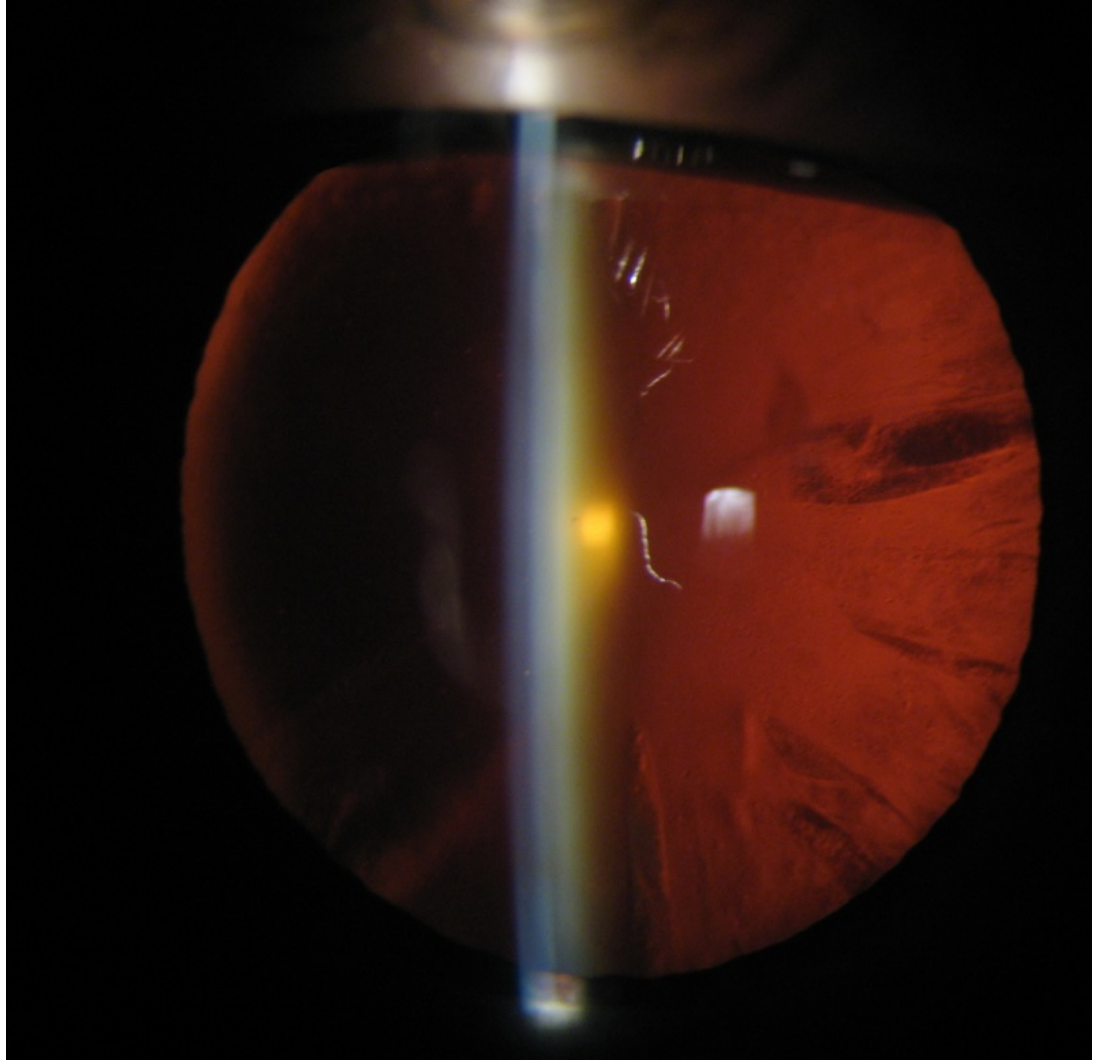


Fig. 9. Cuneiform cortical opacities (cortical spokes)

2. Immature cataract. At this stage, opacification progresses further. The lens appears grayish-white but clear cortex is still present and iris shadow is visible. Scattered opacities of the lens are separated by clear zones (Fig. 10, 11). In some patients, at this stage, the lens may become swollen due to continued hydration. This condition is called *intumescent cataract*. In this case due to swollen lens the anterior chamber becomes shallow. Visual acuity at this stage keeps decreasing to 0.7–0.01.

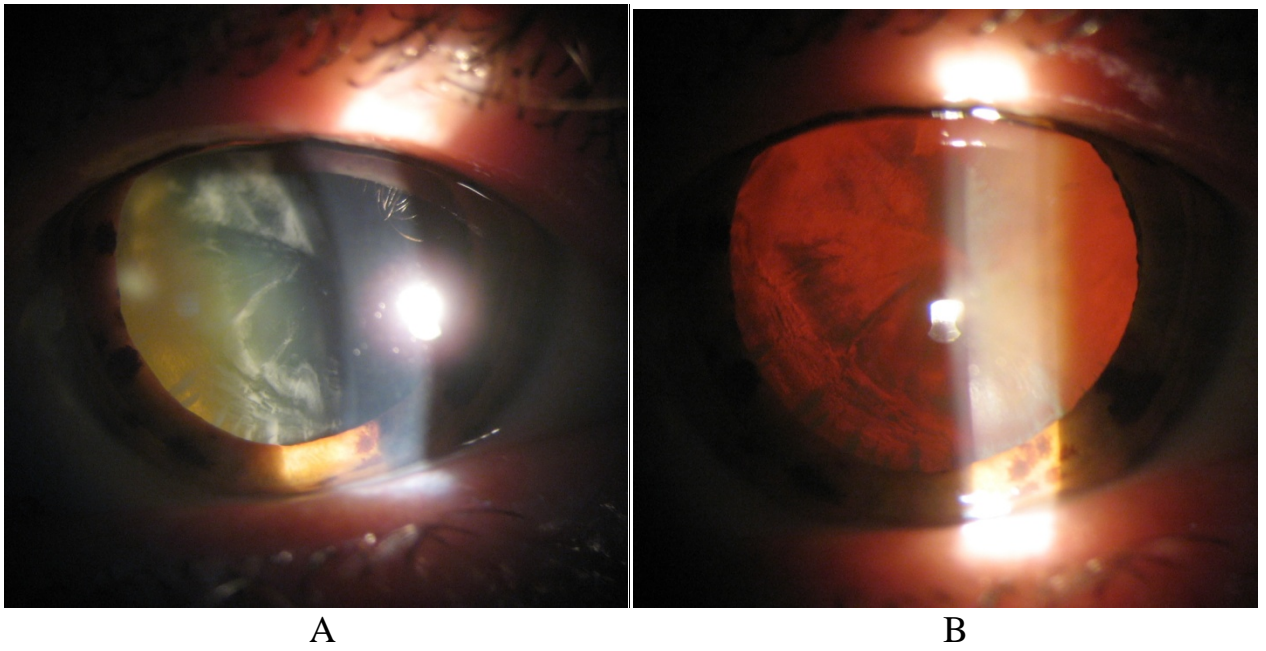


Fig. 10. Immature cortical cataract in focal (A) and direct (B) illumination. Also yellowish opacification of the nucleus (A) can be seen

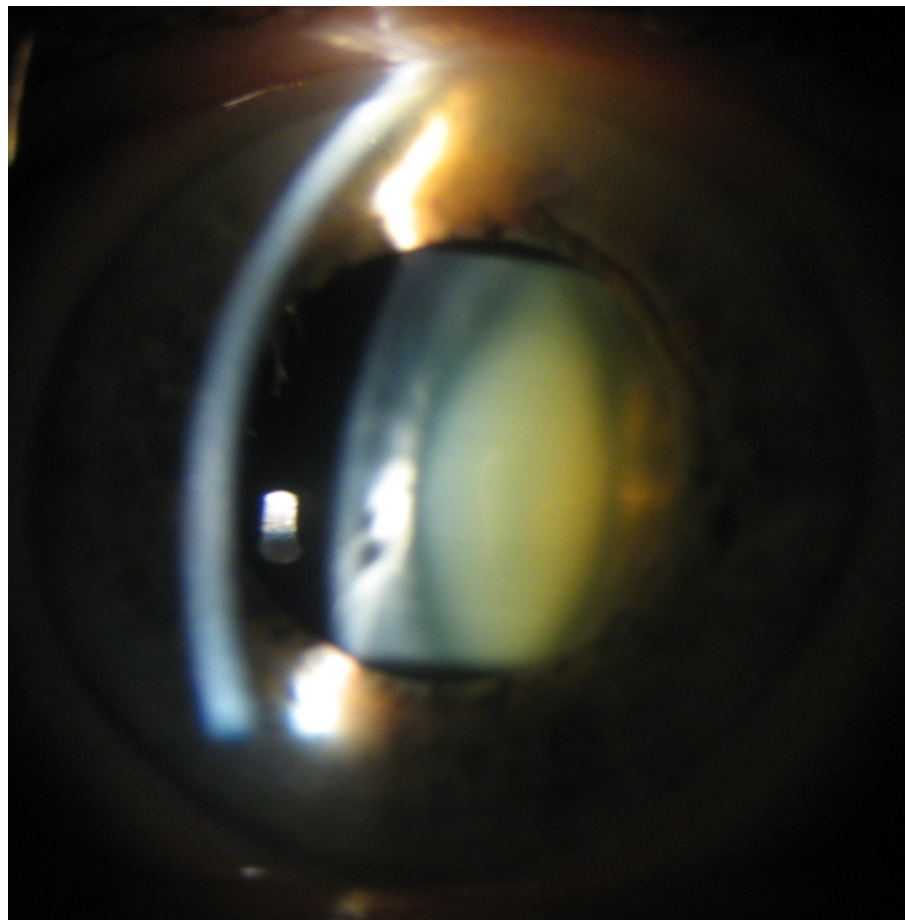


Fig. 11. Immature nuclear cataract

3. Mature cataract. At this stage opacification becomes complete, the whole cortex is totally opaque, the lens structure cannot be differentiated. The lens becomes pearly white or brownish in color, no iris shadow is formed. Vision at this stage decreases from 0.01 to light perception (Fig. 12).

4. Hypermature cataract. When mature cataract is left untreated, the next stage is hypermaturity. Hypermature cataract may appear in any of the two forms:

(a) *Sclerotic cataract* occurs when degenerated cortical material leaks through the lens capsule leaving the capsule wrinkled and shrunken (Fig. 13).

(b) *Morgagnian cataract* occurs when further liquefaction of the cortex allows free movement of the nucleus within the capsular bag. The small brown nucleus usually depresses downwards so that its upper equatorial part is visible.

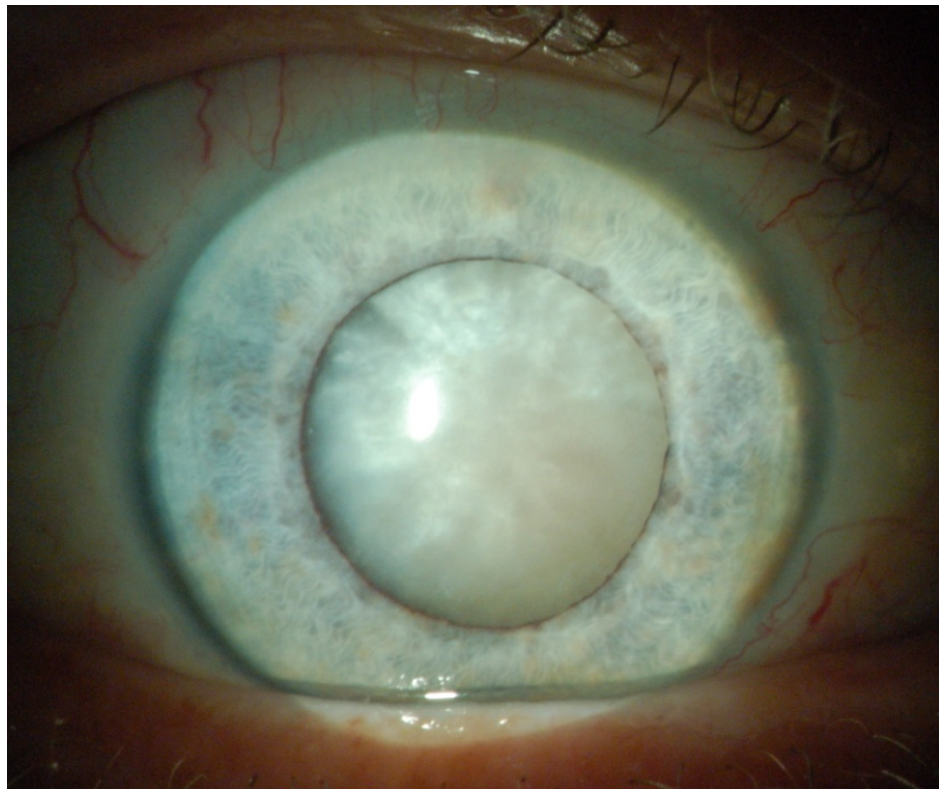


Fig. 12. Mature cataract

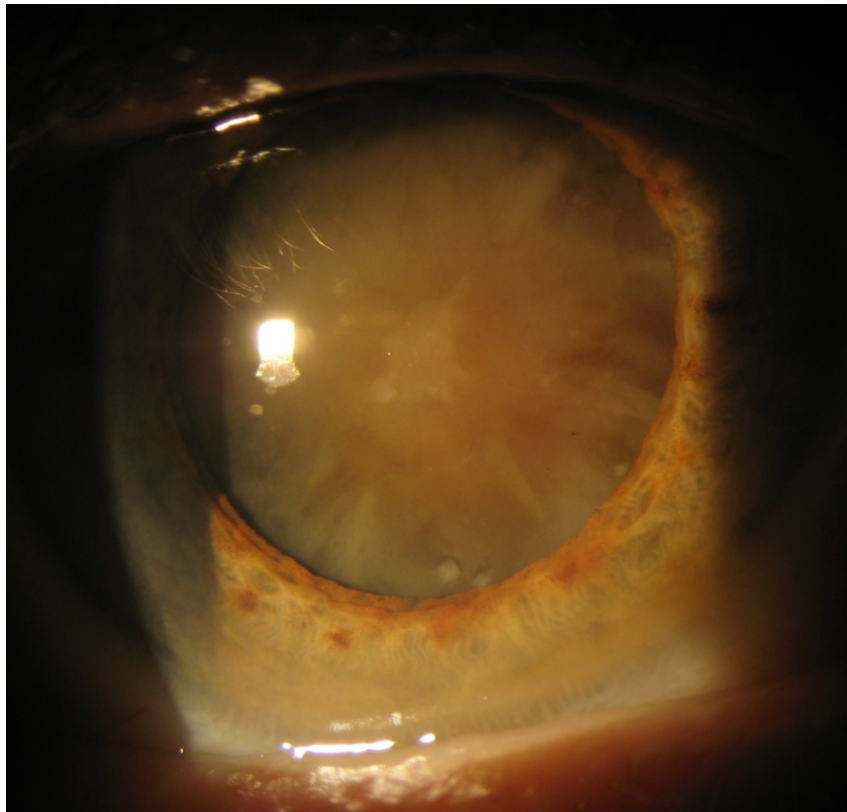


Fig. 13. Hypermature sclerotic cataract

Methods of examination. Examination methods for cataract should include: visual acuity testing, evaluation of intraocular pressure, distant direct ophthalmoscopic examination. Slit-lamp examination with maximally dilated pupil is the main method in cataract patients; it allows evaluating complete morphology of opacity (site, size, shape, color pattern, and hardness of the nucleus). Where the fundus is not visible in mature lens opacity, ultrasound studies (one-dimensional A-scan and two-dimensional B-scan) are indicated to exclude involvement of the deeper structures of the eye.

Treatment. The only curative treatment of cataracts is their surgical removal. However, in some conditions while surgery cannot be carried out for any reason (psychological – the patient is not ready mentally; medical – the risk of severe complications due to systemic diseases; social or any other), optical correction or therapeutic treatment may be prescribed. Lots of topical preparations delaying cataract progression and consisting mostly of vitamins, antioxidants, and minerals are

available at the market nowadays. But none of them have shown satisfying and confirmed effect in delaying the progression of cataract.

The main surgical techniques of cataract removal are as follows:

- intracapsular cataract extraction,
- extracapsular cataract extraction,
- phacoemulsification.

Intracapsular cataract extraction (ICCE) is an obsolete technique at present time and is mentioned here just in historical aspect. In this method, a big (150–180°) corneoscleral incision is made, through which the entire lens is removed within its capsule with the aid of a cryoprobe or a special lens spatula by tearing up all Zinn ligaments. Additionally iridectomy is performed and the incision is closed with sutures. Numerous complications of this method (e.g., retinal detachment, secondary glaucoma, intraocular bleeding, etc.) made ophthalmologists decline it and search for something safer and more effective.

Extracapsular cataract extraction (ECCE) was a big step forward in cataract surgery. In this technique, after corneoscleral incision, the major part of the anterior capsule is cut in “can opener” technique with a bent needle or a special instrument – cystotome – and removed together with the cortex and nucleus of the lens. Therefore, the lens’ capsular bag remains intact being held with Zinn ligaments, which creates perfect background for further IOL implantation into the capsular bag or posterior chamber. Advantages of the method are smaller incision, less sutures, less postoperative astigmatism, safe natural barrier between the posterior and anterior segments of the eye, and as a result – absence of vitreous herniation into the anterior chamber, secondary glaucoma, etc. Relative simplicity of this technique and no need for expensive equipment led to appearance of various modifications of the method, and also made it quite popular among ophthalmologists so that even now in some small clinics it can still be seen, however, more and more rarely.

Phacoemulsification of cataract is the most widespread method of cataract surgery in the world. Phacoemulsification uses a special phaco machine with an ultrasonically driven tip moving along its longitudinal axis at a speed of 40,000 times

a second and thus fragmenting and emulsifying the nucleus. The technique also uses a surgeon-controlled automated irrigation-aspiration system to remove the fragmented nucleus and cortical material through a small needle introduced through a very small incision (1.2–2.75 mm). Incisions are usually clear corneal (they allow to avoid bleeding) and self-sealing (no need in sutures); besides that, such small incisions completely prevent post-operative astigmatism. Protection of the corneal endothelium and other intraocular structures from instrument manipulations in the anterior chamber is ensured by the use of protective viscoelastic materials previously injected into the anterior chamber. Partial removal of the anterior capsule of the lens (4–6 mm in diameter) is usually carried out by means of continuous curvilinear capsulorhexis (CCC) technique.

Development of phacoemulsification: laser phacoemulsification. The latest modification of conventional phacoemulsification technique is femtosecond laser-assisted phacoemulsification. The principle of femtosecond laser work is ocular tissue disruption due to concentration of a great energy in a very small point during an extremely short period of time – 10^{-9} – 10^{-12} sec. The main advantage of the method is that all the cutting procedures like corneal incisions, capsulorhexis, as well as nucleus emulsification can be done very safely and precisely. However, the high cost of the equipment is a serious disadvantage restricting worldwide spread of the technique.

Correction of postoperative aphakia

For full rehabilitation of cataract patients it's not enough to restore optical media transparency; proper correction of refractive abnormality, which appears after opaque lens removal, is also very important. Presently, correction of postoperative aphakia with intraocular lenses (IOL) is considered to be the most physiological. The state of the eye after cataract surgery with implanted IOL is called *pseudophakia*.

IOL consists of two main parts: optical and haptical fixating and centering the lens in the right position.

By anatomic position IOLs can be divided into: anterior chamber IOL, posterior chamber IOL, IOL with iris fixation, and capsular fixation IOLs. The latter are obviously the most preferable in case of non-complicated phacoemulsification or extracapsular extraction.

IOL design can be various and keeps improving and progressing (Fig. 14).

1. *Rigid IOLs* require an incision larger than the diameter of its optic part. They are made entirely from polymethylmethacrylate (PMMA) and are now generally used only in developing countries.




Fig. 14. Examples of IOL design: **A** – four-point aspheric IOL *Akreos™ AO*, Bausch+Lomb; **B** – Toric C-loop IOL *AcrySof® TORIC SN60T5*, Alcon; **C** – Trifocal IOL *AT LISA® tri 839MP*, Zeiss

2. *Flexible IOLs* are now in general use and allow implantation through a very small incision. For insertion they may be folded in half with special forceps or loaded

into an injector delivery system, then unfolded or unrolled inside the eye. By the material they are made of IOLs are classified as follows:

- *silicone* IOLs are available in both loop haptic (1- or 3-piece) and plate haptic (1-piece) conformations,

- *acrylic* IOLs may be hydrophobic (water content < 1 %) or hydrophilic, with much higher water content. Hydrophobic acrylic materials have a greater refractive index than hydrophilic lenses and are consequently thinner. Hydrophilic acrylic (hydrogel), in theory, offers better biocompatibility,

- *collamer* is composed of collagen, a poly-HEMA based copolymer, and a UV-absorbing chromophore.

3. *Aspheric IOLs*. Optical aberrations occur when light from a point object does not form a perfect point after passing through the optical system. The refraction of peripheral rays of light is greater than those passing near the lens center. This is pupil-dependent and may account for the symptoms of dysphotopsia when the Snellen visual acuity is good, but the patient has a poor subjective outcome. The cornea has a positive spherical aberration and the young crystalline lens has negative spherical aberration, resulting in neutralization. However, later in life the aging crystalline lens develops positive spherical aberration and therefore both combine to increase the spherical aberration of the eye. Therefore if one inserts an intraocular lens with a negative spherical aberration to neutralize that of the cornea, visual function will theoretically improve.

A number of manufacturers have therefore developed aspheric intraocular lenses, which are said to improve contrast sensitivity function and visual performance, particularly in mesopic lighting conditions. In some implants the aspheric surfaces on the anterior, and in some the posterior surface, and the degree of IOL-induced spherical aberration varies.

Another approach has been to produce an intraocular lens with no spherical aberration to allow the small positive spherical aberration from the cornea to provide a degree of pseudoaccommodation.

Although there is a wealth of evidence which suggests that these lens implants are theoretically better, in practical terms the patients may not notice the difference. This may in part be due to the fact that the lens implants are not directly matched to the spherical aberration of the cornea, i.e. they are not customized, and that if there is more than 0.8 mm of decentration all advantage would be lost.

4. Multifocal IOLs aim to provide clear vision at different focal distances.

There are three types of multifocal/accommodating intraocular lenses.

i Refractive lens – This has a variable refractive anterior surface producing multiple points of foci to give multifocality and a very good range of focus. The disadvantages are that patients can experience halos at night and the photopic reading vision can be poor, due to pupil miosis.

ii Diffractive lens – This lens has a diffraction grating on the anterior or posterior surface of the lens to give a bifocal effect. The lens implant gives very good near and distance vision, but initially only fair intermediate vision. It also suffers from halos and poor scotopic reading vision.

iii Accommodative lens – This lens implant sits in the capsular bag and relies on capsule/ciliary body interaction to push the lens anteriorly and posteriorly to give an accommodative effect (Fig.15). The lens is therefore varifocal and has the advantage of low incidence of dysphotopsia, but the near vision is not as good as with the refractive or diffractive lens.




Fig.15. Crystalens® AO – accommodating posterior chamber IOL by Baush + Lomb

The lens designs vary in the distance dominance. The amount of reading addition varies between 3 and 4 diopters in the IOL plane, equivalent to 2.25–3.75 in the spectacle plane, and the split between distance and near may be 50/50, or more usually 60/40. The materials now are nearly always acrylic for the diffractive, refractive lenses and silicone for the accommodating lens.

The lens implant technologies may be mixed (mix and match) to enhance the depth of field and use the advantages of each lens i.e. using a diffractive lens in the non-dominant and refractive lens in the dominant eye.

The concept of monovision is important and should always be borne in mind when assessing patients.

5. Toric IOLs.

When planning cataract surgery, the surgeon must take into account the corneal astigmatism, i.e. that which is left following removal of the natural lens. It must also be remembered that a low degree of myopic against the rule astigmatism can be useful in producing pseudoaccommodation. The peroperative options for correcting astigmatism are at the corneal plane, that is placing the incision on the steep

meridian, limbal relaxing incisions (LRI), or opposite clear corneal incisions (OCCI). At the lenticular plane one can insert a toric intraocular lens. The lenses must be designed to have no postoperative rotation, otherwise they would induce a cross cylinder effect and have to be stable in both the short and long term. Thirty degrees of rotation will cancel out the effect of the toric correction completely.

The preoperative assessment and lens power calculation have to be accurately measured, and this should ideally be done with the Javal Shiotz keratometer (as the gold standard) but may also be done with an IOL Master or by corneal topography. The surgeon needs to know what astigmatism is induced by the incision(s), and this is influenced by size, location, and position. Many lens manufacturers have on-line calculators to determine the toric intraocular lens power and its orientation.

The horizontal axis of the eye needs to be marked on the limbus immediately pre-operatively, preferably at a slit lamp, prior to any form of anesthesia, to take into account the effect of cyclorotation of the eye (which can be up to 4°) when the patient lies down. After the lens implant is inserted and the viscoelastic removed, the lens then must be aligned with the suggested axis with the aid of marks on the surface of the lens and on the limbus.

The critical success factors are preoperative assessment of the astigmatism, accurate marking of the horizontal axis, and alignment of the intraocular lens.

A 1° axis error results in a 3.3% loss of the intraocular lens cylinder power correction, and 10° off will therefore lose 33% of its cylinder power. If it is 90° off axis, cylinder power will double.

These lenses are very effective if the corneal astigmatism is greater than 1.5 diopters. Less than this, treatment in the corneal plane is a better option due to error in corneal power and axis calculation and axis alignment and stability.

6. Blue light filters.

Age-related macular degeneration can progress following cataract surgery due to acute (class II photochemical reaction) blue light damage and perioperative inflammation, the latter being associated with complement activation (Fig. 15.4A). It might also progress in the long term due to increased exposure to blue light and is

proportional to the level and duration of exposure and the wavelength. The process is said to occur because energy from blue light is absorbed by the retinal pigment epithelium which interacts with fluorophore (A2E) within lipofuscin to produce free radicals, which subsequently cause oxidative stress to the RPE cells and apoptosis.

The cataractous lens becomes yellow with age to produce a natural filter which is then removed during routine cataract surgery. The rationale for blue filters/yellow intraocular lenses is to maintain a blue light blocking/reducing effect (at peak approx 440 nm, range 400–475 nm) to protect against chronic exposure to blue light. These blockers are said to reduce leakage from the blood–retinal barrier, reduce free radical damage, and therefore reduce the risk of progression of long-term age-related macular degeneration.

Although there is laboratory evidence that this effect does occur, many of the experiments were done in the short-term with acute photic damage and may not represent what happens in the aging human.

There appears to be no detrimental effect on color vision, contrast sensitivity, or visual acuity with these bluefiltering lenses. However, there may be a reduction in mesopic retinal function and an effect on circadian rhythms by reducing the amount of light which reaches non-visual melanopsin containing retinal ganglion cells/blue light photo receptors in the retina, which are responsible for circadian rhythm entrainment. Trials to test this are currently underway.

Therefore, there is a clear rationale for blue light filters, experimental evidence of efficacy, but little clinical proof. It is likely that their total light exposure is a risk factor for progression of macular degeneration, which is dependent on geographical location and lifestyle.

IOL Optic Power Calculation

Regression formulas (formulas generated by averaging large numbers of postoperative clinical results) are used to choose the appropriate IOL power for achieving emmetropia in the eye. The following formula developed by Sanders,

Retzlaff, and Kraff in the 1980s (SRK formula) was the basic one for future development of IOL calculations:

$$P = A - (2.5L) - 0.9K,$$

where P = lens implant power for emmetropia (diopters); L = axial length of the eye (mm); K = average keratometric reading (diopters); A = a constant, specific to the lens implant to be used, which depends on the lens material, design, positioning, etc.

Newer versions of regression formulas (e.g., SRK/T, Holladay 2, Hoffer Q, Haigis) have been developed for IOL power calculation in the eyes outside the range of 22–25 mm length (patients with initial severe refractive abnormalities).

Complications of cataract surgery and their management

Now-a-days cataract surgery is being performed largely by phacoemulsification and sometimes – extracapsular cataract extraction technique.

Therefore, complications encountered during these techniques are described in general. Wherever necessary a specific reference of the technique viz. conventional ECCE, manual SICS and phacoemulsification in relation to the particular complication is highlighted. Complications encountered during surgical management of cataract can be enumerated under the following heads:

- (A) Preoperative complications
- (B) Intraoperative complications
- (C) Early postoperative complications
- (D) Delayed (late) postoperative complications
- (E) IOL-related complications

[A] Preoperative complications

1. **Anxiety.** Some patients may develop anxiety, on the eve of operation due to fear and apprehension of operation. Anxiolytic drugs such as diazepam 2 to 5 mg at bed time usually alleviate such symptoms.

2. Nausea and gastritis. A few patients may develop nausea and gastritis due to preoperative medicines such as acetazolamide and/or glycerol. Oral antacids and omission of further dose of such medicines usually relieve the symptoms.

3. Irritative or allergic conjunctivitis may occur in some patients due to preoperative topical antibiotic drops. Postponing the operation for 2 days along with withdrawal of such drugs is required.

4. Corneal abrasion may develop due to inadvertent injury during Schiotz tonometry. Patching with antibiotic ointment for a day and postponement of operation for 2 days is required.

5. Complications due to local anaesthesia

Retrobulbar haemorrhage may occur due to retrobulbar block. Immediate pressure bandage after instilling one drop of 2% pilocarpine and postponement of operation for a week is advised.

Oculocardiac reflex, which manifests as bradycardia and/or cardiac arrhythmia, has also been observed due to retrobulbar block. An intravenous injection of atropine is helpful.

Perforation of globe may also occur sometimes. To prevent such catastrophe, gentle injection with blunt-tipped needle is recommended. Further, peribulbar anaesthesia may be preferred over retrobulbar block.

Subconjunctival haemorrhage is a minor complication observed frequently, and does not need much attention.

Spontaneous dislocation of lens in vitreous has also been reported (in patients with weak and degenerated zonules especially with hypermature cataract) during vigorous ocular massage after retrobulbar block. The operation should be postponed and further management is on the lines of posterior dislocation of lens.

[B] Operative complications

1. Superior rectus muscle laceration and/or haematoma, may occur while applying the bridle suture. Usually no treatment is required.

2. Excessive bleeding may be encountered during the preparation of conjunctival flap or during incision into the anterior chamber. Bleeding vessels may be gently cauterised.

3. Incision related complications depend upon the type of cataract surgery being performed.

i. *In conventional ECCE* there may occur *irregular incision*. Irregular incision leading to defective coaptation of wound may occur due to blunt cutting instruments.

ii. *In manual SICS and phacoemulsification* following complications may occur while making the self-sealing tunnel incision.

Button holing of anterior wall of tunnel can occur because of superficial dissection of the scleral flap. As a remedy, abandon this dissection and re-enter at a deeper plane from the other side of the external incision.

Premature entry into the anterior chamber can occur because of deep dissection. Once this is detected, dissection in that area should be stopped and a new dissection started at a lesser depth at the other end of the tunnel.

Scleral disinsertion can occur due to very deep groove incision. In it there occurs complete separation of inferior sclera from the sclera superior to the incision. Scleral disinsertion needs to be managed by radial sutures.

4. Injury to the cornea (Descemet's detachment), iris and lens may occur when anterior chamber is entered with a sharp-tipped instrument such as keratome or a piece of razor blade. A gentle handling with proper hypotony reduces the incidence of such inadvertent injuries.

5. Iris injury and iridodialysis (tear of iris from root) may occur inadvertently during intraocular manipulation.

6. Complications related to anterior capsulorhexis.

Continuous curvilinear capsulorhexis (CCC) is the preferred technique for opening the anterior capsule for SICS and phacoemulsification. Following complications may occur:

Escaping capsulorhexis i.e., capsulorhexis moves peripherally and may extend to the equator or posterior capsule.

Small capsulorhexis. It predisposes to posterior capsular tear and nuclear drop during hydrodissection. It also predisposes to occurrence of zonular deshiscence. Therefore, a small sized capsulorhexis should always be enlarged by 2 or 3 relaxing incisions before proceeding further.

Very large capsulorhexis may cause problems for in the bag placement of IOL.

Eccentric capsulorhexis can lead to IOL decentration at a later stage.

7. Posterior capsular rupture (PCR). It is a dreaded complication during extracapsular cataract extraction.

In manual SICS and phacoemulsification PCR is even more feared because it can lead to nuclear drop into the vitreous. The PCR can occur in following situations:

- _ During forceful hydrodissection,
- _ By direct injury with some instrument such as Sinsky's hook, chopper or phacotip
- _ During cortex aspiration (accidental PCR)

8. Zonular dehiscence may occur in all techniques of ECCE but is especially common during nucleus prolapse into the anterior chamber in manual SICS.

9. Vitreous loss: It is the most serious complication which may occur following accidental rupture of posterior capsule during any technique of ECCE. Therefore, adequate measures as described below should be taken to prevent vitreous loss.

To decrease vitreous volume: Preoperative use of hyperosmotic agents like 20 percent mannitol or oral glycerol is suggested.

To decrease aqueous volume: Preoperatively acetazolamide 500 mg orally should be used and adequate ocular massage should be carried out digitally after injecting local anaesthesia.

To decrease orbital volume adequate ocular massage and orbital compression by use of superpinky, Honan's ball, or 30 mm of Hg pressure by paediatric sphygmomanometer should be carried out.

Better ocular akinesia and anaesthesia decrease the chances of pressure from eye muscle.

Minimising the external pressure on eyeball by not using eye speculum, reducing pull on bridle suture and overall gentle handling during surgery.

Use of Flieringa ring to prevent collapse of sclera especially in myopic patients decreases the incidence of vitreous loss.

When IOP is high in spite of all above measures and operation cannot be postponed, in that situation a planned posterior-sclerotomy with drainage of vitreous from pars plana will prevent rupture of the anterior hyaloid face and vitreous loss.

Management of vitreous loss. Once the vitreous loss has occurred, the aim should be to clear it from the anterior chamber and incision site. This can be achieved by performing partial anterior vitrectomy, with the use of automated vitrectors.

A meticulously performed partial anterior vitrectomy will reduce the incidence of postoperative problems associated with vitreous loss such as updrawn pupil, iris prolapse and vitreous touch syndrome.

10. Nucleus drop into the vitreous cavity. It occurs more frequently with phacoemulsification, less frequently with manual SICS and sparingly with conventional ECCE. It is a dreadful complication which occurs due to sudden and large PCR.

Management. Once the nucleus has dropped into the vitreous cavity, no attempt should be made to fish it out. The case must be referred to vitreoretinal surgeon after a thorough anterior vitrectomy and cortical clean up.

11. Posterior loss of lens fragments into the vitreous cavity may occur after PCR or zonular dehiscence during phacoemulsification. It is potentially serious because it may result in glaucoma, chronic uveitis, chronic CME and even retinal detachment.

Management. The case should be managed by vitreoretinal surgeon by performing pars plana vitrectomy and removal of nuclear fragments.

12. Expulsive choroidal haemorrhage. It is one of the most dramatic and serious complications of cataract surgery. It usually occurs in hypertensives and

patients with arteriosclerotic changes. It may occur during operation or during immediate postoperative period. Its incidence was high in ICCE and conventional ECCE but has decreased markedly with valvular incision of manual SICS and phaco emulsification technique.

It is *characterised* by spontaneous gaping of the wound followed by expulsion of the lens, vitreous, retina, uvea and finally a gush of bright red blood.

Although *treatment* is unsatisfactory, the surgeon should attempt to drain subchoroidal blood by performing an equatorial sclerotomy. Most of the time eye is lost and so evisceration operation has to be performed.

[C] Early postoperative complications

1. *Hyphaema.* Collection of blood in the anterior chamber may occur from conjunctival or scleral vessels due to minor ocular trauma or otherwise.

Treatment. Most hyphaemas absorb spontaneously and thus need no treatment. Sometimes hyphaema may be large and associated with rise in IOP. In such cases, IOP should be lowered by acetazolamide and hyperosmotic agents. If the blood does not get absorbed in a week's time, then a paracentesis should be done to drain the blood.

2. *Iris prolapse.* It is usually caused by inadequate suturing of the incision after ICCE and conventional ECCE and occurs during first or second postoperative day. This complication is not known with manual SICS and phacoemulsification technique.

Management: A small prolapse of less than 24 hours duration may be repositioned back and wound sutured. A large prolapse of long duration needs abscission and suturing of wound.

3. *Striate keratopathy.* Characterised by mild corneal oedema with Descemet's folds is a common complication observed during immediate postoperative period. This occurs due to endothelial damage during surgery.

Management. Mild striate keratopathy usually disappears spontaneously within a week. Moderate to severe keratopathy may be treated by instillation of hypertonic saline drops (5% sodium chloride) along with steroids.

4. Flat (shallow or nonformed) anterior chamber.

It has become a relatively rare complication due to improved wound closure. It may be due to wound leak, ciliochoroidal detachment or pupil block.

i. *Flat anterior chamber with wound leak* is associated with hypotony. It is diagnosed by Seidel's test. In this test, a drop of fluorescein is instilled into the lower fornix and patient is asked to blink to spread the dye evenly. The incision is then examined with slit lamp using cobalt-blue filter. At the site of leakage, fluorescein will be diluted by aqueous. In most cases wound leak is cured within 4 days with pressure bandage and oral acetazolamide. If the condition persists, injection of air in the anterior chamber and resuturing of the leaking wound should be carried out.

ii. *Ciliochoroidal detachment.* It may or may not be associated with wound leak. Detached ciliochoroid presents as a convex brownish mass in the involved quadrant with shallow anterior chamber. In most cases choroidal detachment is cured within 4 days with pressure bandage and use of oral acetazolamide. If the condition persists, suprachoroidal drainage with injection of air in the anterior chamber is indicated.

iii. *Pupil block due to vitreous bulge* after ICCE leads to formation of iris bombe and shallowing of anterior chamber. If the condition persists for 5-7 days, permanent peripheral anterior synechiae (PAS) may be formed leading to secondary angle closure glaucoma.

Pupil block is managed initially with mydriatic, hyperosmotic agents (e.g., 20% mannitol) and acetazolamide. If not relieved, then laser or surgical peripheral iridectomy should be performed to bypass the pupillary block.

5. Postoperative anterior uveitis can be induced by instrumental trauma, undue handling of uveal tissue, reaction to residual cortex or chemical reaction induced by viscoelastics, pilocarpine etc.

Management includes more aggressive use of topical steroids, cycloplegics and NSAIDs. Rarely systemic steroids may be required in cases with severe fibrinous reaction.

6. Bacterial endophthalmitis. This is one of the most dreaded complications with an incidence of 0.2 to 0.5 percent. The principal sources of infection are contaminated solutions, instruments, surgeon's hands, patient's own flora from conjunctiva, eyelids and air-borne bacteria.

Symptoms and signs of bacterial endophthalmitis are generally present between 48 and 72 hours after surgery and include: ocular pain, diminished vision, lid oedema, conjunctival chemosis and marked circumciliary congestion, corneal oedema, exudates in pupillary area, hypopyon and diminished or absent red pupillary glow.

Management. It is an emergency and should be managed energetically.

[D] Late postoperative complications

These complications may occur after weeks, months or years of cataract surgery.

1. Cystoid macular oedema (CME). Collection of fluid in the form of cystic loculi in the Henle's layer of macula is a frequent complication of cataract surgery. However, in most cases it is clinically insignificant, does not produce any visual problem and undergoes spontaneous regression. In few cases, clinically significant CME typically produces visual diminution one to three months after cataract extraction. On funduscopy it gives *honeycomb appearance*. On fluorescein angiography it depicts typical *flower petal pattern* due to leakage of dye from perifoveal capillaries. In most cases it is associated with vitreous incarceration in the wound and mild iritis. Role of some prostaglandins is being widely considered in its etiopathogenesis. Therefore, immediate preoperative and postoperative use of antiprostaglandins (indomethacin or flurbiprofen or ketorolac) eyedrops is recommended as prophylaxis of CME. In cases of CME with vitreous incarceration, anterior vitrectomy along with steroids and antiprostaglandins may improve visual acuity and decrease the amount of discomfort.

2. *Delayed chronic postoperative endophthalmitis* is caused when an organism of low virulence (*Propionobacterium acne* or *staph epidermidis*) becomes trapped within the capsular bag. It has an onset ranging from 4 weeks to years (mean 9 months) postoperatively and typically follows an uneventful cataract extraction with a PCIOL in the bag.

3. *Pseudophakic bullous keratopathy (PBK)* is usually a continuation of postoperative corneal oedema produced by surgical or chemical insult to a healthy or compromised corneal endothelium. PBK is becoming a common indication of penetrating keratoplasty (PK).

4. *Retinal detachment (RD)*. Incidence of retinal detachment is higher in aphakic patients as compared to phakics. It has been noted that retinal detachment is more common after ICCE than after ECCE. Other risk factors for aphakic retinal detachment include vitreous loss during operation, associated myopia and lattice degeneration of the retina.

5. *Epithelial ingrowth*. Rarely conjunctival epithelial cells may invade the anterior chamber through a defect in the incision. This abnormal epithelial membrane slowly grows and lines the back of cornea and trabecular meshwork leading to intractable glaucoma. In late stages, the epithelial membrane extends on the iris and anterior part of the vitreous.

6. *Fibrous downgrowth* into the anterior chamber may occur very rarely when the cataract wound apposition is not perfect. It may cause secondary glaucoma, disorganisation of anterior segment and ultimately phthisis bulbi.

7. *After cataract*. It is also known as 'secondary cataract'. It is the opacity which persists or develops after extracapsular lens extraction or phakoemulsification. More details about this complication will be described below.

8. *Glaucoma-in-aphakia and pseudophakia*.

[E] IOL-related complications

In addition to the complications of cataract surgery, following IOL-related complications may be seen:

1. Complications like cystoid macular oedema, corneal endothelial damage, uveitis and secondary glaucoma are seen more frequently with IOL implantation, especially with anterior chamber and iris supported IOLs.

UGH syndrome refers to concurrent occurrence of uveitis, glaucoma and hyphaema. It used to occur with rigid anterior chamber IOLs, which are not used now.

2. Malpositions of IOL (Fig. 16). These may be in the form of decentration, subluxation and dislocation.

The fancy names attached to various malpositions of IOL are:

_ *Sun-set syndrome* (Inferior subluxation of IOL).

_ *Sun-rise syndrome* (Superior subluxation of IOL).

_ *Lost lens syndrome* refers to complete dislocation of an IOL into the vitreous cavity.

_ *Windshield wiper syndrome*. It results when a very small IOL is placed vertically in the sulcus.

In it the superior loop moves to the left and right, with movements of the head.

3. Pupillary capture of the IOL (Fig. 17) may occur following postoperative iritis or proliferation of the remains of lens fibres.

4. Toxic lens syndrome. It is the uveal inflammation excited by either the ethylene gas used for sterilising IOLs (in early cases) or by the lens material (in late cases).

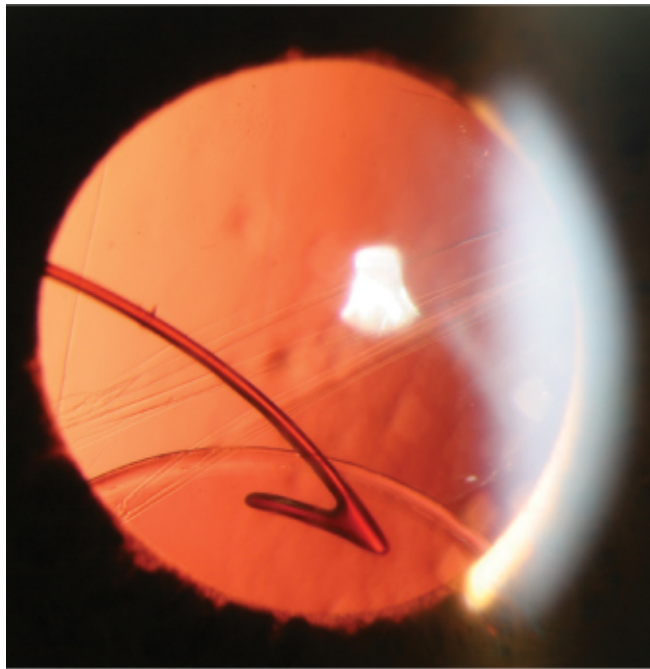


Fig. 16. Subluxed posterior chamber intraocular lens, partially supported by capsular remnants (By Karim N. Jamal, Pravin U. Dugel, Retinal Physician, 2009)

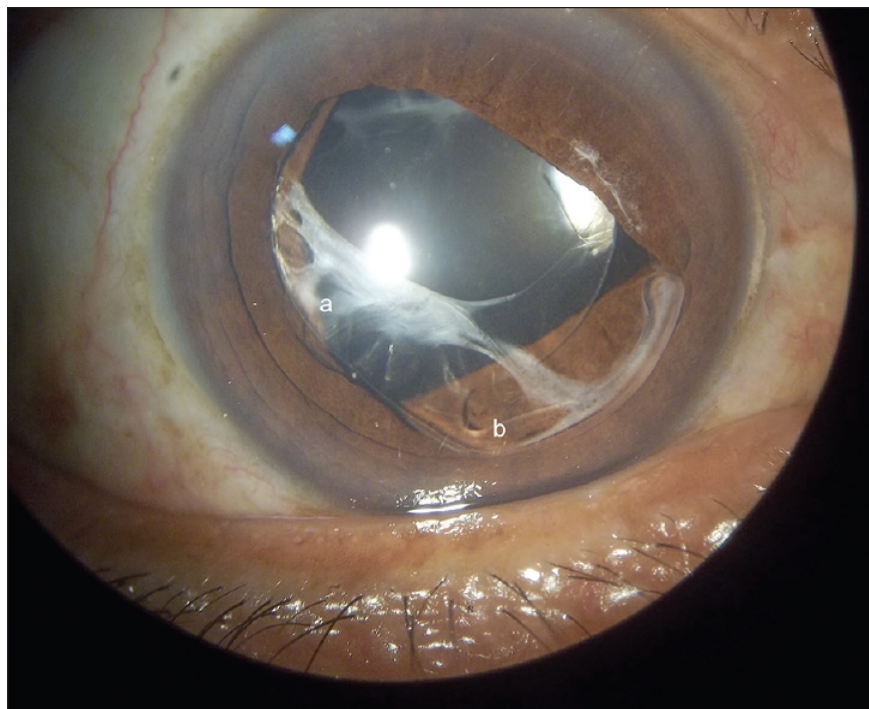


Fig.17. Anteriorly dislocated in-the-bag acrylic foldable intraocular lens with (a) capsular contraction and (b) compressed haptic (By H. Bhattacharjee, R. K. Saxena, J. Medhi, Indian J. Ophthalmology, 2015)

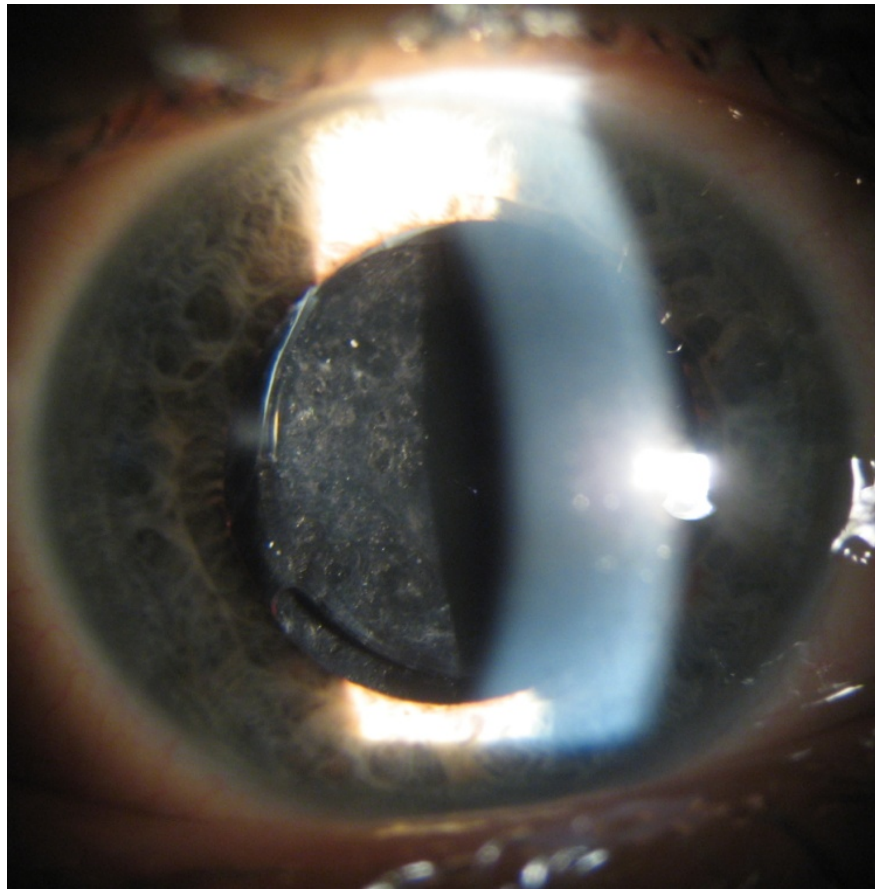
Secondary Cataract

Secondary cataract is an opacity which persists or develops after cataract surgery carried out with lens capsule retention (ECCE or phacoemulsification).


Etiology. Residual lens epithelial cells are inevitably left behind at the time of surgery, attached to the capsule despite thorough removal of soft lens material. They proliferate, migrate, and undergo metaplasia, resulting in opacification of the posterior capsule. Two patterns of posterior capsular opacification are seen: cellular proliferation, producing drop-like deposits in the visual axis (Elschnig's pearls), or fibrosis and shrinkage of the capsule, producing striae.

Symptoms and signs. Patients report gradual decrease in vision during some months of years after cataract surgery. They describe hazy or misty vision as well as glare. Elschnig's pearls are large deposits on the posterior capsule in the form of droplet-like soap bubbles (Fig. 18). There also may be striae and a fibrous sheet across the visual axis.

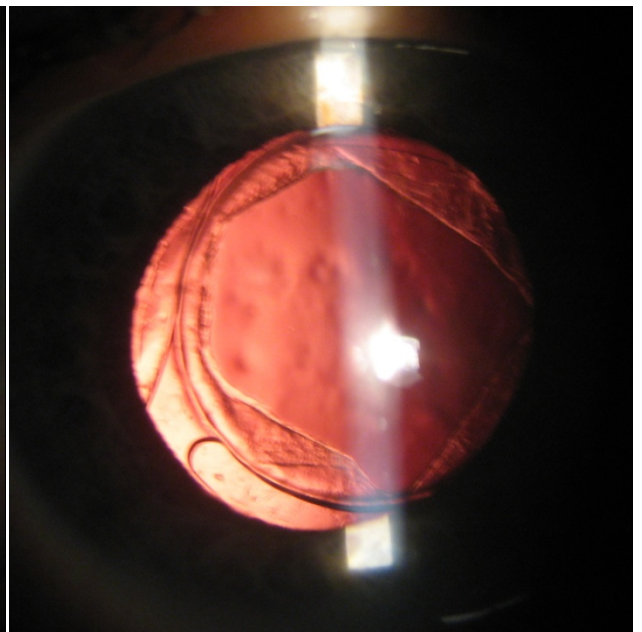
Treatment. There is now considerable evidence that square-profile IOLs reduce the risk of secondary cataracts. YAG-laser capsulotomy is a very effective and safe procedure for the treatment of visually significant opacities. It is performed as an outpatient procedure and does not require any anesthesia.



A



B



C

Fig. 18. Secondary cataract, the same eye: A – in oblique illumination; direct illumination B – before, and C – after YAG-laser capsulotomy

5.2.1 Medications list for cataract treatment

I. Preparations delaying cataract progression:

- Azapentacene Sulfonate Sodium (Quinax[®]) – 15 ml – eye drops.
- Cytochrome C/Vitamin B3/Adenosine (Oftan[®] Catachrom) – 10 ml – eye drops.
- Pirenoxine 0.005 % ophthalmic solution (Catalin) – 15 ml – eye drops.

II. Perioperative medications:

1. Anesthetics

A. Topical (drops, ointments)

- Proparacaine hydrochloride 0.5 % ophthalmic solution (Alcaine[®], Ophthetic[®]).
- Tetracaine hydrochloride 0.5 % – 1.0 % ophthalmic solution (TetraVisc[®], Altacaine[®]).
- Benoxinate (oxybuprocaine hydrochloride) 0.4 % ophthalmic solution (Novesine[®], Benoxi[®]).
- Lidocaine 4 %.
- Bupivacaine 0.75 %.

B. Intracameral anesthetics:

Isotonic, nonpreserved 1–2 % lidocaine; 0.75 % bupivacaine (Marcaine[®]).

C. Retrobulbar or parabolbar anesthesia:

Lidocaine, 1–2 % (Xylocaine[®]); mepivacaine, 1–2 % (Carbocaine[®], Polocaine[®]); bupivacaine, 0.25–0.75 % (Marcaine[®]).

2. Cycloplegic drugs/mydriatics:

- Atropine 1 % ophthalmic solution – eye drops.
- Phenylephrine hydrochloride 10 % ophthalmic solution (Phenephrin[®]) – 10 ml – eye drops.
- Tropicamide Ophthalmic Solution USP, 0.5–1 % (Mydracyl[®]) – eye drops.

3. Antibiotics (topical):

- Tobramycin 0.3 % sterile ophthalmic solution (Tobrex[®]).
- Ciprofloxacin 0.3 % ophthalmic solution (Ciloxan[®]).
- Ofloxacin 0.3 % ophthalmic solution (Ocuflox[®], Floxal[®], Uniflox[®]).
- Gatifloxacin 0.3 % ophthalmic solution (Zymar[®]).
- Moxifloxacin 0.5 % ophthalmic solution (Vigamox[®], Moxeza[®]).
- Levofloxacin 0.5 % ophthalmic solution (Quixin[®], Oftaquin[®]).

4. Ocular antiseptics:

Povidone-iodine 5 % ophthalmic solution (Betadine[®]).

5. Irrigating solutions:

- BSS[®] (Balanced Salt Solution) contains sodium chloride 0.64 %, potassium chloride 0.075 %, calcium chloride 0.048 %, magnesium chloride 0.03 %, sodium acetate 0.39 %, sodium citrate 0.17 %, sodium hydroxide and/or hydrochloric acid (to adjust pH), and water for injection.
- BSS plus[®]: each ml contains: sodium chloride 7.44 mg, potassium chloride 0.395 mg, dibasic sodium phosphate 0.433 mg, sodium bicarbonate 2.19 mg, hydrochloric acid and/or sodium hydroxide (to adjust pH), calcium chloride dihydrate 3.85 mg, magnesium chloride hexahydrate 5 mg, dextrose 23 mg, glutathione disulfide (oxidized glutathione) 4.6 mg in water for injection.

6. Ophthalmic Viscosurgical Devices (OVDs):

A. Cohesive OVDs:

Healon[®], Provisc[®], Amvisc Plus[®].

B. Dispersive OVDs:

DisCoVisc[®], Viscoat[®], Cellugel[®], Visilon[®], Celoftal[®].

7. Corticosteroids (topical):

- Dexamethasone sodium phosphate 0.1 % ophthalmic solution (Maxidex[®]).
- Prednisolone acetate 1 % ophthalmic solution (Pred Forte[®]).
- Difluprednate 0.05 % ophthalmic emulsion (Durezol[®]).
- Loteprednol etabonate 0.5 % ophthalmic suspension (Lotemax[®]).

8. Nonsteroidal Anti-inflammatory Drugs:

- Diclofenac sodium 0.1 % ophthalmic solution (Uniclophen[®], Diphthal[®], Diclo-F[®]).
- Indometacine 0.1 % ophthalmic solution (Indocollyre[®]).
- Nepafenac 0.1 % ophthalmic suspension (Nevanac[®]).
- Preservative-free ketorolac tromethamine 0.45 % ophthalmic solution (Acuvail[®]).
- Bromfenac 0.09 % ophthalmic solution (Bromday[®]).

5.3. Recommended literature

Main:

Khurana A. Comprehensive Ophthalmology / A. K. Khurana, Aruj K. Khurana, B. Khurana. - 6th ed. - New Delhi : Jaypee Brothers, 2015. - 634 p.

Additional:

1. Chern K. Emergency Ophthalmology : A Rapid Treatment Guide : монография / К.С. Chern. - New York : McGRAW-HILL, 2003. - 298 p.
2. James B. Lecture Notes on Ophthalmology / B. James, C. Chew, A. Bron. - 9th ed. - Oxford : Blackwell Publishing, 2003
3. Kanski J. Clinical Ophthalmology: A Systematic Approach / J. Kanski, Bowling B. - 7th ed. - Saunders, Edinburgh, New York : Elsevier, 2011.
4. Malhotra R. Eye Essentials: Cataract Assessment : Classification and Management. - Oxford : Butterworth Heinemann, 2008.

5. Rapid Diagnoses in Ophthalmology: Lens and Glaucoma / J. Schuman, V. Christopoulos, D. Dhaliwal, M. Kahook, R. Noecker. – Maryland Heights, 2008.
6. Oxford American handbook of ophthalmology / J. Tsai, A. Denniston, P. Murray, J. Huang, Aldad, T. – Oxford, Oxford University Press, 2011.
7. Yanoff M. Ophthalmology / M. Yanoff, J. Duker. - 3rd ed. - Maryland Heights, 2008.
8. Lecture materials
9. Tutorial

5.4 The Review questions

5.4.1. Lesson topic control questions:

1. What diseases of the lens do you know?
2. Name anomalies of the lens position. In which chromosomal diseases they may occur?
3. Name anomalies of the size and shape of the lens
4. Give definition to the term “Cataract”. Classification of cataracts.
5. What is etiology of congenital cataracts. Describe their main symptoms and signs.
6. Name the differences in clinical picture of different morphological types of congenital cataracts. Approaches to congenital cataracts treatment
7. Name main etiological factors for acquired cataracts.
8. Describe clinical symptoms of senile cataracts depending on their morphology.
9. Specify objective signs of senile cataract depending on its maturation stage.
10. What examination methods will you use in cataract patient examination?
11. What is the treatment strategy for acquired cataract? Name the main techniques of cataract surgery
12. How to correct postoperative aphakia after cataract surgery? Specify the main types of IOL
13. How to calculate IOL optic power in cataract patient?

14. What is secondary cataract? Main approaches to its treatment

5.4.2. Multiple-answer questions

1. Which of listed objective signs mainly referred to *Subluxation of the lens*?

- A. Dislocation of the lens into vitreous
- B. Total opacification of the lens
- C. Opacities of the posterior capsule of the lens
- D. Presence of irido- and phacodonesis
- E. Absence of the lens in pupillary area

2. All of this conditions are *anomalies of lens size and shape* except:

- A. Anterior lenticonus
- B. Microspherophakia
- C. Sutural cataract
- D. Lens coloboma
- E. Remnants of the fetal vasculature system of the lens

3. Which of the following is not characteristic for *congenital cataracts*?

- A. Lamellar cataract
- B. Sutural cataract
- C. Polar cataract
- D. Blue dot cataract
- E. Morgagnian cataract

4. A prophylactic slit lamp examination of a 25-year-old woman with visual acuity of both eyes = 1.0 (20/20) and without any complains of vision showed small, discrete bluish opacities of the lens cortex . What is the diagnosis?

- A. Congenital nuclear cataract
- B. Congenital coronary cataract

- C. Senile cortical cataract
- D. Blue dot cataract
- E. Congenital sutural cataract

5. A woman noted that the pupils of both eyes of her 1-week baby have unusual white color. What pathology may be suspected in this case?

- A. Congenital aphakia
- B. Congenital cataract
- C. Lenticonus
- D. Microspherophakia
- E. Conjunctivitis

6. Which of the following congenital cataracts should be treated surgically at early age?

- A. Bilateral blue dot cataract
- B. Bilateral total cataract
- C. Unilateral anterior polar cataract
- D. Bilateral anterior polar cataract
- E. Coronary cataract

7. What is the most often etiological factor for acquired cataracts?

- A. Trauma
- B. Infections of anterior segment of the eye
- C. Toxic effects of medications
- D. Metabolic disorders of the organism
- E. Age

8. Which of following signs describe *Incipient stage* of senile cataract?

- A. Dense yellow nucleus of the lens, visual acuity = 0.1
- B. Scattered opacities of the lens are separated by clear zones, VA = 0.6

- C. Cortex is milky-white, small brown nucleus is dislocated downwards.
- D. Vacuoles in posterior cortex, cuneiform opacities in lower nasal quadrant
- E. Cortex is opaque, lens layer cannot be differentiated

9. A patient, 67 years old, complains of gradual decrease of vision during the last 3 years. Visual acuity in both eyes = 0.2, intraocular pressure is normal. Objective examination shows no pathological changes in the conjunctiva, cornea, and anterior chamber. The lens appears grayish-white but clear cortex is still present and iris shadow is visible. Scattered opacities of the lens are separated by clear zones. What is the diagnosis?

- A. Immature senile cataract
- B. Mature senile cataract
- C. Incipient senile cataract
- D. Hypermature senile cataract
- E. Morgagnian cataract

10. A 55-year-old patient complains of decreased vision in the right eye. Visual acuity of the right eye = 0.8. Slit-lamp examination revealed vacuoles in the anterior or posterior cortex, cuneiform opacities in the lens' cortex. Examination in direct illumination showed radial spoke-like opacities in the lens. What is the diagnosis?

- A. Immature senile cataract
- B. Mature senile cataract
- C. Incipient senile cataract
- D. Hypermature senile cataract
- E. Morgagnian cataract

11. In *immature senile cataract* during slit-lamp examination can be seen:

- A. Lens appears grayish-white, scattered opacities of the lens but clear cortex is still present and iris shadow is visible
- B. Cuneiform opacities in lower nasal quadrant

- C. Cortex is opaque, lens layer cannot be differentiated, no iris shadow
- D. The lens is brown in color, its capsule is wrinkled and shrunken
- E. Small discrete bluish opacities in cortex

12. Patient has immature senile nuclear cataract with visual acuity decreased to 0.5.

Which is most preferable treatment strategy in this case?

- A. Therapeutical treatment with vitamins and antioxidant eye-drops
- B. Intracapsular cataract extraction
- C. Phacoemulsification
- D. Optical correction of refractive abnormalities
- E. No treatment required because patient has normal visual acuity

13. Which of the following methods considered to be most physiological for postoperative aphakia correction?

- A. Contact lenses
- B. Intraocular lenses
- C. Glasses
- D. Excimer-laser correction
- E. No need in any optical correction

14. The term "Secondary cataract" means:

- A. Cataract developed during intrauterine period due to maternal infection
- B. Cataract developed after penetrating injury of the eyeball
- C. Cataract developed in patient with diabetes mellitus
- D. Opacity of posterior lens capsule following vitreoretinal surgery for retinal detachment
- E. Opacity of posterior lens capsule following cataract phacoemulsification with IOL implantation

15. Which of the materials is never used for IOL manufacturing?

- A. Polymethylmethacrylate (PMMA)
- B. Acryl
- C. Silicone
- D. Polyvinyl chloride
- E. Collamer

16. Parents came to an ophthalmologist with a 6 years old child. One year ago phacoemulsification of congenital cataract with IOL implantation of the left eye was carried out to the boy. An objective examination: visual acuity of right eye 1.0, left eye = 0.2 no optical correction is eligible. In the left eye IOL position is correct, posterior capsule is clear. On the eye fundus - the optic disc has normal color, disk margins are clear, blood vessels are of normal caliber, macular and foveolar reflexes are clear, visual fields are normal. What is the most probable cause of low vision in the left eye?

- A. Congenital glaucoma
- B. Amblyopia
- C. Partial optic atrophy
- D. Secondary cataract
- E. All above are correct

5.4.3. Tasks

1. A patient, 20 years old, complains of pure vision in both eyes since early age. General examination reveals tall and thin stature, arachnodactyly, hypermobility of joints. Ophthalmic examination revealed in both eyes 7-diopter myopia, the lenses of both eyes are displaced superiorly and temporally.

- Which diagnosis should be supposed in this case?
- What would be a correct treatment strategy?

2. An 18-year-old patient complains of blurred vision since early childhood, when high myopia was diagnosed. He wears concave (-10.0 diopters) spectacles for both

eyes. Objectively the patient has short stature, thick and short fingers, short hands. Ophthalmological signs: bilaterally the lenses have small diameter, their equator is seen in the dilated pupil, they have a spherical shape. Beside this, the lenses are displaced inferiorly and nasally.

- Which diagnosis is more probable?
- What would be a correct treatment strategy?

3. Mother referred to an ophthalmologist because she mentioned in her 2-month aged daughter no reaction for bright toys and relatives' faces, nistagmus, and whitish color of the pupils in both eyes. Ophthalmologic examination revealed presence of dense opacities of entire nucleus in both baby's lenses.

- What type of congenital cataract is most probable in this case?
- What treatment strategy should be chosen?

4. A 65-years old patient complains of gradual decrease of vision for far in both eyes during last 2 – 3 years, worse vision in conditions of bright illumination or sunshine. At the same time he said he cannot use his reading glasses anymore and can see at near distance without spectacles. Refractometry revealed 4 diopters myopia. Slit-lamp examination – dense brownish nucleus of the lens.

- Which is the most probable diagnosis?
- What treatment would be preferable in this case?

5. An 82-years old patient came to an ophthalmologist with complains of gradual painless vision loss in right eye. Vision has been getting worse progressively during 10 or 12 years. 2 years ago the vision disappeared completely, but the patient didn't visit a doctor. VA in right eye = $1/\infty$ pr. l. certa (correct light projection). During slit-lamp examination the lens is white, cortex seems milky-white and liquefied. Small brown nucleus can be seen depressed downwards within the capsular bag.

- What is the diagnosis?
- What treatment would you offer?

6. A 64- years old female patient complain of gradual decrease of vision in her left eye which she mentioned 3 month ago. 2 year ago she was treated surgically for immature cataract (Cataract phakoemulsification with IOL implantation) in this eye. VA in left eye = 0.6. Objective examination reveals no changes in anterior segment of the left eye. Pseudophakia, IOL is centred inside the capsular bag. Posterior capsule of the lens is a bit opaque, large droplet-like of soap bubbles deposits are seen on the posterior capsule.

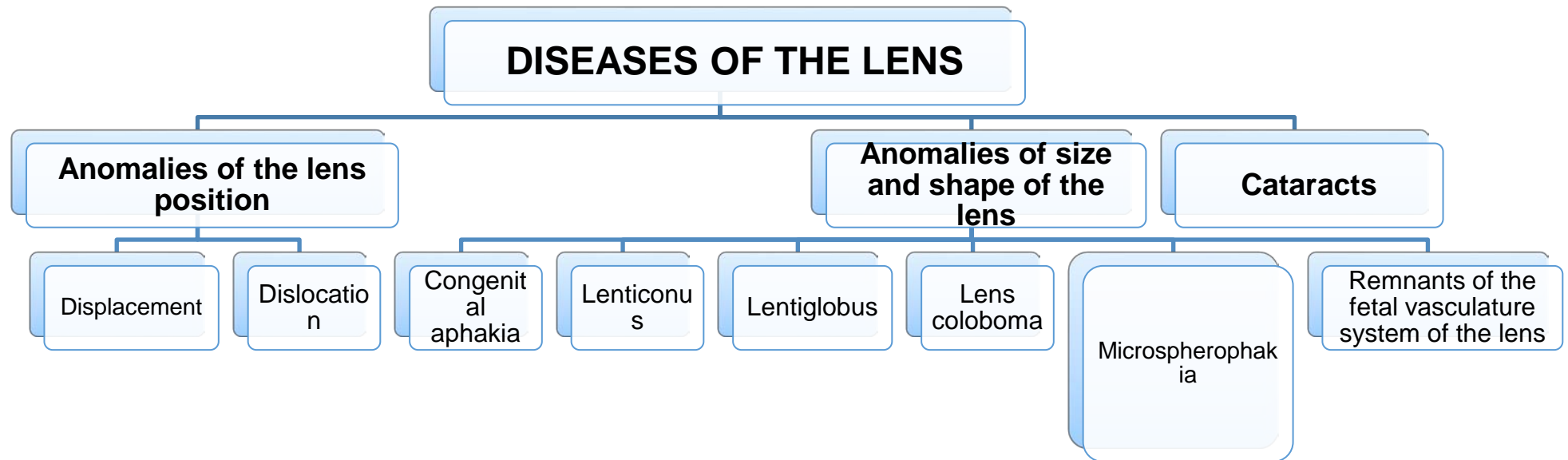
- How such condition is called?
- What are the treatment options?

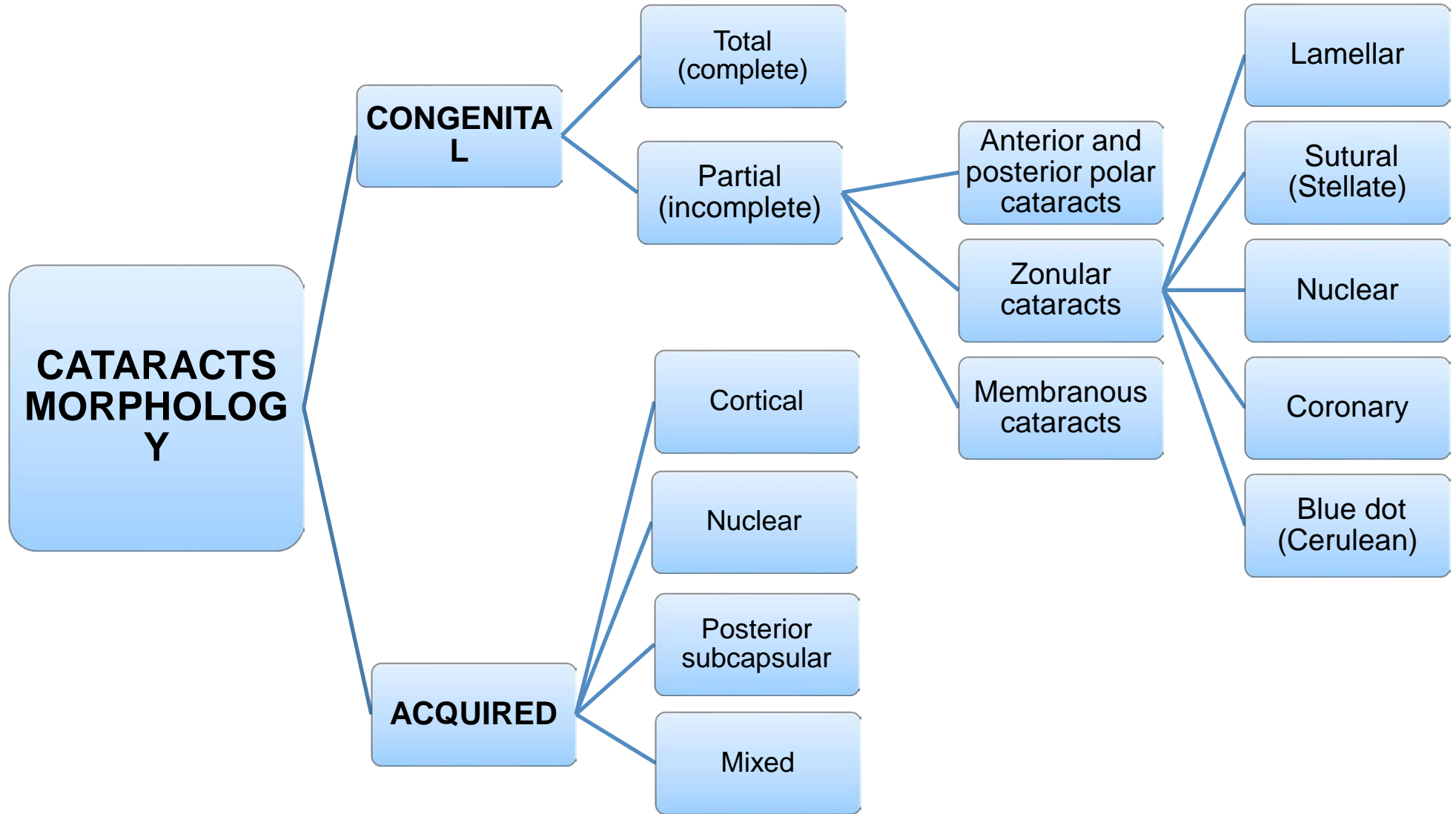
6. Material for independent work

The list of practical skills which should be done by a student at the practical class:

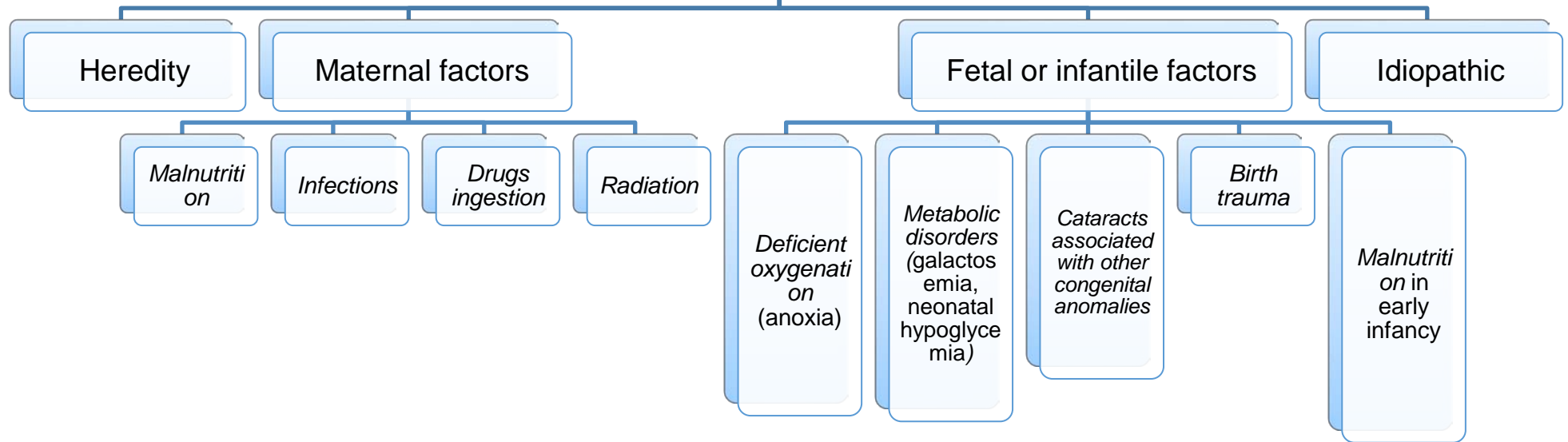
- Assessment of patient's complains and anamnesis
- Ophthalmological examination of the patient with lens diseases
- Making up the diagnosis
- Planning patient's investigations and evaluate their results
- Choose the treatment strategy

Appendix 1. Schemes for the topic





CONGENITAL CATARACT ETIOLOGY



ACQUIRED CATARACTS ETIOLOGY

